

[CLINICAL COMMENTARY]

NEIL S. GHODADRA, MD¹ • MATTHEW T. PROVENCHER, MD, LCDR² • NIKHIL N. VERMA, MD¹
KEVIN E. WILK, PT, DPT³ • ANTHONY A. ROMEO, MD¹

Open, Mini-open, and All-Arthroscopic Rotator Cuff Repair Surgery: Indications and Implications for Rehabilitation

Rotator cuff tears can lead to a variety of clinical manifestations, including debilitating shoulder dysfunction and impairment. The goal of rotator cuff repair is to eliminate pain and improve function with increased shoulder strength and range of motion (ROM). Optimal repair of the rotator cuff includes achievement of high fixation strength, minimal gap formation and maintenance of mechanical stability under cyclic loading, and proper healing of tendon to bone. In addition to adequate

surgical repair, outcomes are dependent on appropriate rehabilitation. Successful postoperative management following

rotator cuff repair is dependent on several variables, including surgical intervention method, patient age,

activity level, chronicity of tear, and tear size. With rapidly advancing surgical techniques and modes of fixation, optimal rehabilitation following rotator cuff surgical repair has become increasingly important and challenging for the orthopedic surgeon and physical therapist. This article will address the current trends in rotator cuff repair and discuss the important postoperative implications of open, mini-open, and all-arthroscopic cuff repair techniques.



• **SYNOPSIS:** Rotator cuff tears lead to debilitating shoulder dysfunction and impairment. The goal of rotator cuff repair is to eliminate pain and improve function with increased shoulder strength and range of motion. The clinical outcomes of the surgical methods of rotator cuff repair (open, mini-open, and all-arthroscopic cuff repair) vary, as each method provides an array of advantages and disadvantages. Although the open surgical technique has long been considered the gold standard of rotator cuff repair, surgeons are becoming more adept at decreasing patient morbidity through decreased surgical trauma from an all-arthroscopic approach. In addition to a surgery-specific rotator cuff rehabilitation program, effective communication, and coordination of care by the physical therapist and surgeon are essential in optimal patient education and outcomes. In the ideal situation, a very well-educated therapist who has great communication with the treating surgeon can mobilize the shoulder early, re-establish scapulohoracic function safely and minimize the

risk of stiffness and retear, while facilitating return to function. Treatment options can be individualized according to patient age, size and chronicity of tear, surgical approach, and fixation method. We recommend that patients who have undergone an all-arthroscopic rotator cuff repair undergo an accelerated postoperative rehabilitation program. A rational approach to therapy involves early, safe motion to allow optimal tendon healing, yet maintenance of joint mobility with minimal stress. As the field of orthopedics and, particularly, rotator cuff repair continues to develop with new technologies, the patient, physical therapist, and doctor need to work together to ensure optimal outcomes and patient satisfaction.

• **LEVEL OF EVIDENCE:** Therapy, Level 5.
J Orthop Sports Phys Ther 2009; 39(2):81-89.
doi:10.2519/jospt.2009.2918

• **KEY WORDS:** arthroscopy, rotator cuff tear, shoulder, supraspinatus

OPEN ROTATOR CUFF REPAIR

THE FIRST ROTATOR CUFF REPAIR was performed by Dr Codman in 1911, utilizing an open technique.⁷⁷ Further modifications were later proposed by Neer in 1972 and included a description of 5 fundamentals of open rotator cuff repair techniques: (1) meticulous repair of the deltoid origin, (2) subacromial decompression, (3) surgical releases as necessary to obtain freely mobile muscle-tendon units, (4) secure transosseus fixation of the tendon to the tuberosity, and (5) closely supervised rehabilitation with early passive motion.⁷⁷ Outcome studies of individuals who were treated with an open rotator cuff repair have revealed good to excellent results in both functional improvement (75%-

¹ Orthopaedic Surgeon, Rush University, Department of Orthopaedic Surgery, Chicago, IL. ² Orthopaedic Surgeon, Naval Medical Center, Department of Orthopaedic Surgery, San Diego, CA. ³ Associate Clinical Director, Champion Sports Medicine, A Physiotherapy Associates Clinic, Birmingham, AL; Rehabilitation Consultant, Tampa Bay Rays Baseball Team, Tampa Bay, FL. Address correspondence to Dr Neil S. Ghodadra, 1653 West Congress Pkwy, 1471 Jelke Bldg, Chicago, IL 60612. Email: neil_ghodadra@rush.edu

[CLINICAL COMMENTARY]

95% of patients) and pain relief (85%-100% of patients).^{7,20,29,34,63} Although the development of reliable, procedure-specific, arthroscopic instrumentation and various fixation methods have led to arthroscopically assisted rotator cuff repair techniques, open rotator cuff repair continues to be used by many surgeons, particularly for large or massive tears. Open cuff repair is performed in these instances, as the quality of the remaining tissue may be poor and significant tendon retraction and adhesions are likely, making arthroscopic rotator cuff repair challenging.

To perform an open rotator cuff repair, the patient is usually placed in a beach-chair position, with the torso angled 60° to the horizontal (**FIGURE 1**). After identification and marking of the appropriate osseous landmarks, including the anterior and lateral borders of the acromion and clavicle, a 3- to 6-cm incision is made over the anterior superior aspect of the shoulder, parallel with the lateral border of the acromion, in line with Langer's lines (**FIGURE 1**). The subcutaneous fat layer is then divided with electrocautery and the deltoid muscle insertion into the acromion is clearly identified. The deltoid is taken off the anterior aspect of the acromion, generally beginning at the acromioclavicular joint, extending along the anterior border of the acromion, then splitting the deltoid laterally for 3 to 5 cm. It is critical to maintain a strong, healthy cuff of deltoid fascia, which can be used for tissue reapproximation to the acromion and preservation of the deltoid origin.

Next, a subacromial decompression and bursal resection is performed. Resection of the bursa leads to better visualization of the rotator cuff and decreased pain and inflammation subsequent to the surgery.^{35,59,68} After identification of the leading edge of the tendon, debridement of adhesions is performed to help mobilize the tendon to the greater tuberosity. Next, bone preparation is performed by minimal debridement of the cortical bone on the greater tuberosity. In many open rotator cuff repairs, a transosseus

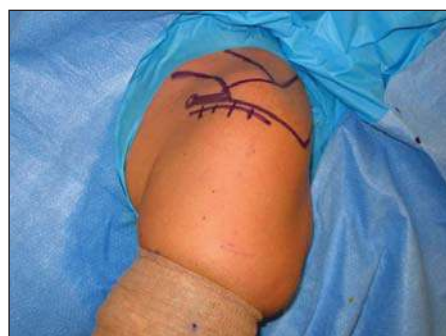

FIGURE 1. Patient in beach-chair position, with the coracoid process, acromioclavicular joint, clavicle, and acromion marked for the left shoulder. For an open rotator cuff repair, a 3- to 6-cm incision is marked parallel to the lateral border of the acromion.

suture technique is employed. An approximately 1.5-cm bridge of hard cortical bone is preferred between the medial and lateral drill holes, with the lateral hole exiting cortical bone distal to the greater tuberosity to optimize tendon-bone healing and fixation strength.⁹ A braided nylon suture is passed through the bony tunnels, then through the tendon, with at least a 1-cm cuff of tissue. A simple suture technique is used for repair. A locking-stitch technique, known as the modified Mason-Allen stitch, is also often used for better holding power, especially when the quality of the rotator cuff tissue is compromised.²⁷ Multiple other suture techniques and open repair suture and/or anchor configurations have been described.

Deltoid reattachment to the acromion is a critical component of open rotator cuff repair, with specific implications for postoperative rehabilitation. A strong and meticulous repair of both the superficial and deep deltoid fascial layers is essential to avoid postoperative dehiscence during rehabilitation. The longitudinal deltoid split is repaired with nonabsorbable sutures in a simple fashion, while reattachment to bone is often performed through tunnels in the acromion. In a study by DeOrio et al,¹⁸ prior deltoid detachment or lateral acromionectomy was present in approximately 48% of patients who presented for a second rotator cuff repair. Consequently, postsurgery, it is important for patients to avoid activities that

create tensile loads to the area of deltoid reattachment.

Multiple studies have shown 80% to 94% of patients who have undergone open rotator cuff repair to have good to excellent results.^{13,20,33,47} In a study of 100 patients at 4.2-year follow-up, Hawkins et al³³ reported that 86% of patients had no or slight pain. The average shoulder abduction ROM increased from 81° preoperatively to 125° postoperatively. Neer et al⁴⁷ reviewed the results of 245 patients who underwent open rotator cuff repair and reported a 91% satisfactory rate. In a review of 105 patients who had open rotator cuff repair, Cofield et al¹³ found tear size to be the most important determinant of outcome with regard to active motion, strength, satisfaction, and need for reoperation. Rokito et al,⁶³ reported a 76% rate of satisfactory results at a mean follow-up of 5 years in 30 patients with open repair of large and massive cuff tears. In the study by Rokito et al⁶³ the postoperative protocol included passive ROM exercises and the use of an arm sling for 6 weeks. Active ROM exercises were begun at 6 weeks postoperatively, with the addition of isometric and isotonic rotator cuff muscles strengthening exercises when at least 80% of normal active ROM had returned. With regard to tendon healing, Harryman et al³⁰ reported a 68% healing rate in a study of 105 patients at 5-year follow-up.

Despite reports of high satisfaction rates with open cuff repair, the open repair is associated with several disadvantages related to deltoid dysfunction and postoperative pain. Loss of the anterior deltoid is a devastating complication of open cuff repair, as there are no reasonable fixation alternatives and the patient loses anterior deltoid function.⁷⁷ Moreover, deltoid takedown and repair requires a postoperative period of protection of at least 4 weeks, which precludes accelerated postoperative rehabilitation (no active motions). Previous studies have noted a 0.5% incidence of postoperative deltoid avulsion.^{41,45,76} Several studies have also shown that open repair is as-

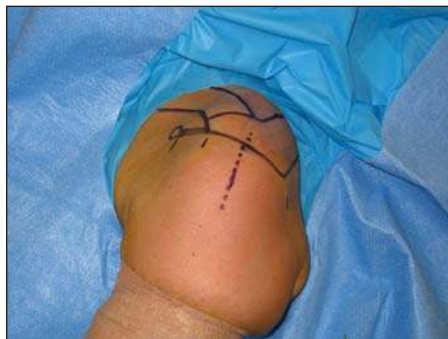

FIGURE 2. For a mini-open rotator cuff repair, the landmarks on the shoulder and the arthroscopic portals are identified and marked. In addition, a 2- to 4-cm incision is marked at the lateral portal site.

sociated with greater postoperative pain than arthroscopic-assisted cuff repair.²⁴⁻²⁶ Increased pain, which can hinder early postoperative physical therapy and lead to longer recovery times, has been associated with the transdeltoid approach of the open technique.^{63,64}

MINI-OPEN ROTATOR CUFF REPAIR

TO CIRCUMVENT THE PRIMARY ISSUES regarding deltoid takedown, Levy et al⁴⁰ described a technique of arthroscopically assisted rotator cuff repair in 1994. In its nascent stages, this “mini-open” technique used arthroscopy to perform a subacromial decompression and avoid deltoid takedown. To accomplish the mini-open repair, the arthroscopic portal is extended by 1 to 2 cm, and the fibers of the deltoid are split in line to obtain access for secure bone-tendon fixation (FIGURE 2). With this approach, rotator cuff preparations, including debridement of tendon edges, releases, mobilization, and, in some cases, single-row anchor placement are all performed arthroscopically. Because most of the procedure is done arthroscopically, both the time requirement and exposure for the deltoid-splitting approach should be limited, potentially minimizing deltoid injury. Mini-open rotator cuff repair has been shown by several authors to provide predictable results similar to open repair. Multiple studies have shown 80% to 88% of patients having good to excellent re-

TABLE	COMPARISON OF ROTATOR CUFF TECHNIQUES		
	Open Cuff Repair	Mini-Open Cuff Repair	Arthroscopic Cuff Repair
Glenohumeral evaluation	No	Yes	Yes
Incision size	4-6 cm	3-4 cm	4-7 mm
Deltoid surgical insult	Moderate to large	Small	Minimal
Repair techniques	Transosseus	Single-row, transosseus	Single-row, double-row, transosseus equivalent
Early passive motion	Yes	Yes	Yes
Early active assisted motion	No	Yes	Yes
Early active motion	No	Yes	Yes
Postoperative pain	Moderate to moderate-severe	Moderate	Mild

sults at long-term follow-up.^{3,56,57} In a study of 29 patients who were treated with mini-open cuff repair, Severud et al⁶⁶ noted that 93% of patients had good to excellent results at 44-month follow-up. The specific rehabilitation used by Severud et al⁶⁶ is typical for mini-open cuff repair and included (1) sling immobilization and passive ROM for the first 6 weeks postsurgery, (2) active assisted ROM exercises and progression to active motion between 6 to 12 weeks postoperatively, (3) resistive exercises starting at 12 weeks, and (4) return to full activity at 6 months.

ALL-ARTHROSCOPIC ROTATOR CUFF REPAIR

ARTHROSCOPIC TREATMENT OF ROTATOR cuff tears has become a routine procedure as the trend toward minimally invasive surgery continues. Proponents of this technique point to the lower risk of complications such as stiffness, infection, and deltoid avulsions. However, critics emphasize the lack of long-term outcome data, the controversy over the optimal fixation method, and the technical difficulty associated with this procedure. In contrast to the mini-open repair technique, the all-arthroscopic cuff repair requires only a small incision for insertion of several cannulas up to 7 to 8 mm in diameter. The only insult to the deltoid is the insertion of the cannula, as no tissue retraction is required by this

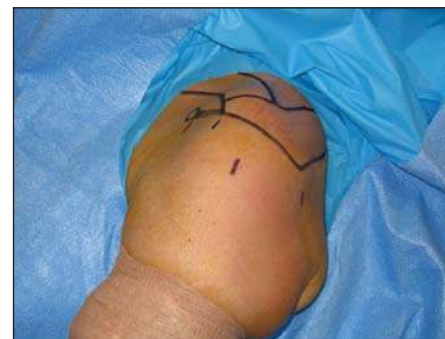

FIGURE 3. For an all-arthroscopic cuff repair, the landmarks on the shoulder and arthroscopic portals are identified and marked; left to right, anterior portal, accessory anterolateral working portal, lateral portal, posterior portal.

technique (TABLE).

After identification of the appropriate landmarks, including the clavicle, acromion, and spine of the scapula, all arthroscopic portals are marked and a 1-cm longitudinal incision is made, as described previously at the posterior portal (FIGURE 3). An anterior working portal is also established lateral to the coracoid and a 5- to 6-mm cannula is placed through this incision into the glenohumeral joint. Once the glenohumeral joint has been examined arthroscopically, a lateral working portal is established under direct visualization at the midline of the lateral acromion. After the rotator cuff tendon and footprint are prepared with instrumentation from the lateral portal (FIGURE 4), a superior-lateral accessory portal can be made proximal and lateral to the anterior working portal for anchor

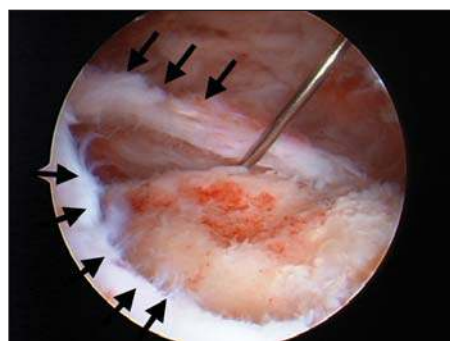


FIGURE 4. U-shaped rotator cuff tear. The black arrows demonstrate the periphery of the tear; the greater tuberosity has been prepared for cuff repair.

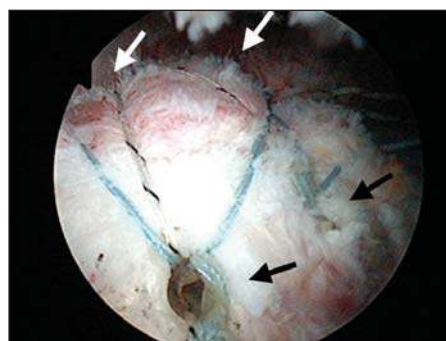


FIGURE 5. Arthroscopic view of the supraspinatus and double-row rotator cuff repair. The white arrows denote the medial row of repair near the musculotendinous junction, and the black arrows denote the lateral row of a double-row transosseous technique.

insertion. Through these portals, various instruments can be introduced into the shoulder to mobilize the cuff, implant suture anchors, and tie arthroscopic knots to hold the torn tendon to bone.

Initially, surgeons performed tendon-bone fixation in arthroscopic cuff repair with a single row of anchors. Recent criticism of the single-row technique has focused on the inability to restore the normal rotator cuff footprint. Therefore, newer techniques utilizing double-row or transosseous equivalent have been developed to reproduce normal footprint anatomy, maximize tendon-bone contact, and minimize gapping with early ROM. These techniques have shown up to 100% restoration of normal surface area of the supraspinatus footprint compared to 65% for single-row fixation.^{37,42} Additionally, biomechanical testing at time zero has demonstrated significant improvement in ultimate load to failure and significant decrease in early gap formation, when compared to traditional single-row techniques.^{14,37,44,48}

From a technical standpoint, the double-row configuration uses a combination of suture anchors placed medially along the anatomic neck and laterally placed bone tunnels to secure a larger surface of tendon down to bone (**FIGURE 5, ONLINE VIDEO**). The transosseous equivalent technique maximizes the utility of a single-row repair by preserving the suture limbs of the medial single-row and bridging these sutures over the footprint insertion with distal-lateral interference screw fixation.⁵⁴ The geometry of

the construct compresses the tendon, providing optimal tendon-bone contact area, while providing sufficient strength to withstand immediate postoperative rehabilitation.¹⁴

From a clinical standpoint, it remains unknown if the double-row or transosseous equivalent repair techniques will achieve superior healing and performance to traditional single-row techniques. Early evidence suggests that patients experience less pain, better early motion, and overall higher initial satisfaction with a double-row technique; however, the data are still not yet conclusive.⁵³ Recent limited prospective studies have shown equivalent clinical results, with no significant difference in postoperative healing, although the power of the studies is limited.^{22,53} With the advent of these new techniques, the postoperative rehabilitation may be slightly accelerated to maintain a careful balance between healing and minimization of postoperative stiffness.^{16,22,38,67}

MASSIVE ROTATOR CUFF TEARS

HISTORICALLY, THE MANAGEMENT OF massive rotator cuff tears included a wide range of procedures, including open or arthroscopic debridement, repair (complete or partial), and muscle or tendon transfer (upper portion of the subscapularis, latissimus dorsi, pectoralis

major, tendon allografts, synthetic graft material, and xenograft).^{1,2,11,23,50} Although repair is always preferred, it is technically more difficult and associated with a higher incidence of failure.^{7,18,75} The tear is usually chronic, and the quality of the rotator cuff tissue may be poor secondary to residual atrophy. Significant bursal scarring and tendon retraction may be present, and several techniques are employed to aid in the mobilization and reconstruction of these tendon defects. These include the mobilization of existing tendons with appropriate release,^{7,10,21} the transfer of tendons,^{4,7,8,49} the implantation of fascia,⁵ allografts,⁵⁰ and the placement of synthetic material.⁵² Results have generally been more satisfactory when the repair has been performed with mobilization and transposition of existing cuff tissue rather than through implantation of fascia, allografts, or synthetic material.^{7,10}

REHABILITATION

THE POSTOPERATIVE REHABILITATION program following rotator cuff repair should vary based on numerous factors, such as type of surgical approach, size of tear, tissue quality, fixation methods, and patient characteristics. The primary goal of the postoperative program is to protect the repair, promote healing, and to gradually restore passive motion and muscular strength to gradually restore function. In this section, we will discuss several guidelines and factors that affect the postoperative rehabilitation program.

Protection

One of the essential goals following rotator cuff repair surgery is to educate the patient regarding protection of the repair site and the delayed nature of the healing process. Soft tissue-to-bone healing is slow and begins by formation of fibrovascular tissue interface between tendon and bone.⁶² It requires at least 12 weeks of healing to allow adequate pull-out strength of the repair.³⁹ Factors that improve tendon-to-bone healing are

pressure^{71,72} and tendon immobilization. Often abduction pillow braces are utilized to protect the surgery site. Hatakeyama et al³¹ reported less strain on the rotator cuff at 45° and 30° compared to 15° and 0° of shoulder abduction. Furthermore, strain was lowest in the scapular plane compared to the sagittal plane for all 4 abduction positions. Thus, following rotator cuff repair surgery, a postoperative abduction pillow brace supporting the shoulder at 30° to 45° of abduction may be necessary to decrease strain on the supraspinatus tendon repair site. Passive and active ROM exercises can also significantly increase strain on the repair site but should be used with caution.

Twelve Factors Affecting the Rehabilitation Program

Rotator cuff repair surgery is functionally debilitating for the patient. A multifaceted rehabilitation approach is critical to regain ROM, strength, and endurance in a timely and safe manner. The following section will outline 12 factors that significantly affect the postoperative rehabilitation program (**APPENDIX A**).

The first factor to consider is the surgical approach. In particular, patients who have deltoid muscle detachment or release from the acromion, clavicle, or both, as in a traditional open rotator cuff repair, should not perform any active deltoid muscle contractions for 6 to 8 weeks. This is implemented to prevent the avulsion of the deltoid muscle from its insertion on the acromion. Conversely, if a mini-open procedure is performed in which the deltoid muscle is split vertically along the orientation of the deltoid muscle fibers, we will allow mild deltoid isometric contractions in a controlled fashion. Lastly, when an arthroscopic repair is performed, the surgery does not involve the deltoid and there is significantly less postoperative pain than following the mini-open or open rotator cuff repair. Baker and Liu³ reported that 85% of patients had good to excellent results, and 88% of patients were satisfied with the open rotator cuff repair. Most inter-

estingly, patients who underwent mini-open repair returned to previous activity an average of 1 month earlier than those who underwent open repair.

The second factor to consider is the size of the tear. Most authors agree that functional outcome after rotator cuff repair is directly related to the size of the tear.^{17,28,58,70} Romeo et al⁶⁵ reported that tears greater than 5 cm in size resulted in poorer outcomes compared to smaller tears. Furthermore, larger tears involve more of the muscle and are often retracted, requiring greater mobilization of the muscle to achieve closure of the tear. Therefore, the rate of progression for postsurgical rehabilitation should vary based on the size and extent of the tear. For small tears (<1 cm), we tend to progress the rehabilitation slightly quicker than for larger tears. This protocol is referred to as a “type I” rehabilitation program (**APPENDIX B [AVAILABLE ONLINE]**). Accordingly, rehabilitation for medium to large tears (2–4 cm) is slightly slower due to greater tissue injury, thus using a “type II” rehabilitation program (**APPENDIX C [AVAILABLE ONLINE]**). Lastly, large to massive tears (≥5 cm) are frequently a more tenuous repair and require more conservative postsurgical management. This program is referred to as a “type III” rehabilitation program. The type III is the slowest protocol due to the size of the tear, the typically poorer tissue quality, and the amount of retraction usually present before surgery. Our rate of progression following rotator cuff repair surgery is often determined by the amount of retraction present prior to repair, with the more retracted tendon requiring a slower rehabilitation course because of a higher postoperative failure rate.

Tissue quality is also to be considered in determining the rate of postoperative progression. This includes the quality of the tendon, muscular tissue, and bone. For example, some patients will exhibit a medium to large tear but still have preserved muscle quality, while another patient with the same size tear will display poor tissue (eg, thin, fatty, weak). The

quality of muscle tissue can be assessed on preoperative magnetic resonance imaging (MRI) with assessment of muscle atrophy and fatty infiltration. Rehabilitation for the patient with good or adequate tissue would be a slightly more aggressive program, whereas the patient with poor tissue quality would follow a more conservative approach. Based on these factors, surgery-specific findings need to be communicated between the surgeon and the rehabilitation specialist.

Another critical factor affecting the postoperative rate of progression and rehabilitation program is the fixation method utilized. Gerber et al²⁷ stated that “the ideal repair should have high initial strength, allow minimal gap formation and maintain stability until solid healing.” As described above, there are numerous repair configurations and fixation methods that can be utilized to repair the torn rotator cuff tendon. Numerous investigators have reported that double-row fixation is stronger than the single-row technique^{37,69} and that the transosseous equivalent repair is stronger than double-row repair.⁵³ Thus, we believe the rehabilitation program should be adjusted based upon the fixation method employed.

Other critical factors are the location and type of tear. Frequently, small tears are confined to the supraspinatus tendon. Neer⁴⁶ emphasized that the critical area for wear is concentrated on the supraspinatus tendon, thus correlating to the site of subacromial impingement. Recently, Park et al⁵⁵ reported that passive external rotation ROM of the shoulder in a cadaver created strain on the anterior fibers of the supraspinatus tendon following repair, which might have led to gap formation. Tears that extend to involve posterior cuff structures (infraspinatus and teres minor) require greater protection and a restriction in excessive shoulder internal rotation motion. Also, these tears require a slower progression with shoulder external rotation strengthening exercises. Tears extending anteriorly into the subscapularis tendon are rare, but can occur, often in conjunction with an anterior shoul-

der dislocation.^{32,51} Rehabilitation after subscapularis repair should restrict the amount of external rotation motion until early tissue healing has occurred, thus gradually restoring motion. Also, resisted internal rotation exercises should be limited for 4 to 6 weeks. The type of tear is also important to recognize and can be classified based on shape and amount of retraction. The most common types of rotator cuff tear are crescent shaped, U-shaped, and L-shaped. Rotator cuff tears tend to propagate; thus, crescent-shaped tears progress to U-shaped tears and U-shaped tears may progress to L-shaped tears. Furthermore, tears tend to retract proximally, which makes it more difficult for the surgeon to repair due to available tissue and tissue tension. Rotator cuff tears that exhibit a significant amount of retraction should be treated more cautiously following repair.

The seventh and eighth factors are the mechanism of failure of the rotator cuff tear and the timing of the repair. Neer⁴⁶ stated that less than 5% of rotator cuff tears are due to traumatic and single-injury mechanisms, whereas 95% of all tears are due to gradual wear. In our experience, individuals with an acute tear followed by early repair show a greater probability of developing shoulder stiffness postsurgery. Similarly, when other procedures, such as a superior labrum anterior posterior (SLAP) repair or capsular plication, are performed concomitantly with the rotator cuff repair, there is a greater tendency toward postoperative stiffness. Thus, with these patients, we tend to be slightly more aggressive with the initial passive ROM program. Bassett and Cofield⁴ noted that patients who underwent early repair progressed more rapidly in their rehabilitation than patients who underwent a late repair. We have found this statement to be consistent with our clinical experience.

The ninth critical factor is the surrounding tissue quality. This concept refers to the remaining rotator cuff tissue anterior and posterior to the tear. For example, for a rotator cuff tear confined

to the supraspinatus, it is important that the physical therapist be made aware of the subscapularis and infraspinatus/teres minor tissue quality. These muscles play a vital role in establishing humeral head compression and dynamic humeral head stability, thus preventing or reducing the probability of the isolated supraspinatus tear extending or propagating anterior or posterior. If the surrounding tissue quality is fair to poor, then the physical therapist should be cautious and more conservative postoperatively.

Next, the patient's characteristics, such as age, level of activity, lifestyle habits, work situation, and recreational activities should be considered. Several authors have reported that outcomes post rotator cuff repair is less successful in older patients.^{12,36,74,75} This may be due to the fact that older patients tend to have larger rotator cuff tears and more complex abnormalities.⁷⁰ The rehabilitation program should also vary slightly based on arm dominance. Patients often perform more strenuous and skilled activities overhead with their dominant arms. Therefore, the dominant arm may require greater ROM and strength when compared to the non-dominant arm. Factors such as smoking, diabetes mellitus, and general health can all influence the healing rates. Another variable to consider is the patient's work situation. Hawkins et al³³ noted that patients with worker compensation required twice as much time to return to work compared to other patients following rotator cuff repair surgery. Other authors have noted similar outcomes.^{6,43}

The rehabilitation specialist also should consider the patient's goals for return to work and sport. Several investigators have noted a correlation between preoperative shoulder function and outcome after surgical repair.²⁰ Generally, patients who are active before surgery are the ones who most frequently return to an active lifestyle after surgery.

The last 2 factors are access to care and the surgeon's philosophical approach to rehabilitation. It has been our clinical observation that patients who

are treated by a skilled physical therapist do significantly better than patients who are treated by a home therapy program. The physical therapist should make adjustments throughout the rehabilitation program based on the patient's progress, thus ensuring an improved outcome. Lastly, some physicians prefer a more aggressive approach, whereas others remain conservative.

Specific Rehabilitation Concepts

Range of Motion One of the primary concerns following rotator cuff repair surgery is shoulder stiffness. However, the rehabilitation specialist should not be overly aggressive in obtaining ROM, which could compromise the repair. There needs to be a balance between applied force and tissue-healing constraints. There are numerous rehabilitation techniques to restore ROM, although some may be safer and more effective than others. Dockery et al¹⁹ performed 7 shoulder exercises while measuring activity levels of the shoulder musculature using electromyographic surface electrodes. The best approach for performing passive joint mobility exercises while minimizing muscular activity was to have the physical therapist perform the exercises with the patient in supine or when using a continuous passive motion (CPM) device. Conversely, the surrounding musculature was most active when doing the rope-and-pulley ROM exercise. The authors prefer passive ROM exercise initially, then to progress to active assisted ROM exercise once adequate tissue healing occurs. Generally, we restrict passive shoulder external rotation to 45° with the arm at 30° to 45° of abduction in the scapular plane, and forward elevation to 120° to avoid excessive tension on the repair.

Muscle Retraining and Strengthening Exercises Initiating rotator cuff and scapula stabilization strengthening exercises should be approached with caution to prevent stress applied to the healing tissues. Stress applied too early or too aggressively could lead to gap formation, pain, retearing of the repair, and poor

outcomes. When appropriate, we believe isometric exercises should be performed to prevent muscular atrophy and to minimize rotator cuff inhibition. Costouros et al¹⁵ reported that 54% of patients with massive rotator cuff tears were found to also have a peripheral nerve injury, most commonly of the suprascapular nerve. Controlled activities that can safely activate the rotator cuff muscles include submaximal and pain-free multiangle isometrics for the external and internal rotator muscles. Furthermore, we initiate rhythmic stabilization exercises in the supine position to promote a cocontraction of the surrounding musculature. These exercises are designed to restore dynamic stabilization of the glenohumeral joint, which is an essential goal in treating patients with a rotator cuff repair. We begin these exercises in supine and with the glenohumeral joint in the “balanced position.”⁷³ This position is defined as 100° of elevation and slight horizontal abduction (scapular plane). In this position, the physical therapist provides resistance in an alternating manner to require an isometric contraction of the shoulder flexors, extensors, and horizontal adductors/abductors. Note that the amount of force is extremely low, usually approximately 0.5 to 1.5 kg of force. The goal is for the patient to activate the muscles of the rotator cuff but is not to achieve strengthening. We have found this exercise to be completely safe for patients who have undergone a rotator cuff repair.

We utilize this balanced position because of the functional anatomy and the biomechanics of the glenohumeral joint. With the arm abducted to 30°, the deltoid muscle’s insertional angle generates a superiorly directed shear force. In contrast, with the arm elevated to slightly greater than 100°, the deltoid’s insertion angle is horizontally directed, thus a compressive force is generated. This position is chosen because of the combined line of pull of both the rotator cuff and deltoid musculature at this angle, causing a humeral head compressive force during muscle contraction. As the patient re-establishes

glenohumeral joint control and dynamic stabilization, the rhythmic stabilization drills can be performed at lower flexion angles (90°, 60°, 30°). The progression we recommend and utilize is from supine to side lying (gravity eliminated), then to antigravity standing arm elevation.

In addition, rhythmic stabilization drills are performed for the external and internal rotators in the scapular plane. These drills are important in restoring activation and proprioception in the rotator cuff muscles. Once dynamic stabilization has been restored to the glenohumeral joint and an adequate amount of time has transpired to allow tissue healing, a progressive and appropriate muscular strengthening program utilizing isotonic exercise may be initiated. We initiate strengthening with external and internal rotation strengthening exercises with tubing and the arm at 0° of abduction. As strength improves, side-lying external rotation with a dumbbell is performed. Reinold et al⁶⁰ reported that this exercise produces the highest level of electromyographic signal for the posterior cuff muscles and is critical in restoring functional use of the arm. In addition, scapular strengthening is performed for the scapular retractors and depressors. It is vital to restore appropriate scapulohumeral rhythm following rotator cuff repair, which allows improved function of the rotator cuff muscles and greater subacromial space for the rotator cuff.

The strengthening exercises are gradually progressed based on symptoms and the demands of functional goals. We encourage the patient to perform light resistance and higher repetition during the first 3 to 4 months following surgery. The patient is placed on a “fundamental shoulder strengthening program” at approximately 2 to 4 months postsurgery (**APPENDIX D [AVAILABLE ONLINE]**). The return to sports (such as golf, tennis, swimming) or strenuous work depends on the patient’s surgical variables (size of tear, tissue quality, concomitant procedures) and the rehabilitation recovery process. Often we place patients on an interval sports pro-

gram to gradually increase the functional activities. Utilizing this rehabilitation program following rotator cuff repair, Wilk et al⁷⁴ have reported a 90% to 95% success rate utilizing the American Shoulder and Elbow Score (ASES) scoring system.

SUMMARY

WITH A MULTITUDE OF SURGICAL techniques and methods of fixation for rotator cuff repairs, rehabilitation has become particularly challenging for the patient, physical therapist, and treating orthopedic surgeon. In addition to a surgery-specific rotator cuff rehabilitation, effective communication and coordination of care by the physical therapist and surgeon are essential in optimal patient education and outcomes. In the ideal situation, a very well-educated physical therapist who has great communication with the treating surgeon can mobilize the shoulder early, re-establish scapulohumeral rhythms safely, and most likely minimize the risk of stiffness and retear, while facilitating return to function. Treatment options can be individualized according to patient age, chronicity of tear, type of cuff repair, tissue quality, and fixation method. A rational approach to rehabilitation involves early, safe motion to allow optimal tendon healing, yet with minimal stress applied to the repair. As the field of orthopedics, particularly rotator cuff repair, continues to incorporate new technologies, the patient, physical therapist, and surgeon will together play the most significant role in patient satisfaction and outcome. ●

REFERENCES

1. Aldridge JM, 3rd, Atkinson TS, Mallon WJ. Combined pectoralis major and latissimus dorsi tendon transfer for massive rotator cuff deficiency. *J Shoulder Elbow Surg.* 2004;13:621-629. <http://dx.doi.org/10.1016/S105827460400134X>
2. Aoki M, Okamura K, Fukushima S, Takahashi T, Ogino T. Transfer of latissimus dorsi for irreparable rotator-cuff tears. *J Bone Joint Surg Br.* 1996;78:761-766.
3. Baker CL, Liu SH. Comparison of open and ar-

thoroscopically assisted rotator cuff repairs. *Am J Sports Med.* 1995;23:99-104.

4. Bassett RW, Cofield RH. Acute tears of the rotator cuff. The timing of surgical repair. *Clin Orthop Relat Res.* 1983;18-24.
5. Bateman JE. The diagnosis and treatment of ruptures of the rotator cuff. *Surg Clin North Am.* 1963;43:1523-1530.
6. Bayne O, Bateman JE. Long term results of surgical repair of full thickness rotator cuff tears. In: Bateman JE, Welsh R, eds. *Surgery of the Shoulder.* Philadelphia: BC Decker; 1984:167-171.
7. Bigliani LU, Cordasco FA, McIlveen SJ, Musso ES. Operative treatment of failed repairs of the rotator cuff. *J Bone Joint Surg Am.* 1992;74:1505-1515.
8. Bush LF. The torn shoulder capsule. *J Bone Joint Surg Am.* 1975;57:256-259.
9. Caldwell GL, Warner JP, Miller MD, Boardman D, Towers J, Debski R. Strength of fixation with transosseous sutures in rotator cuff repair. *J Bone Joint Surg Am.* 1997;79:1064-1068.
10. Cofield RH. Rotator cuff disease of the shoulder. *J Bone Joint Surg Am.* 1985;67:974-979.
11. Cofield RH. Subscapular muscle transposition for repair of chronic rotator cuff tears. *Surg Gynecol Obstet.* 1982;154:667-672.
12. Cofield RH, Lanzer WH, Hoffmeyer PJ. Surgical repair of chronic rotator repairs. *Orthop Trans.* 1990;14:251-252.
13. Cofield RH, Parvizi J, Hoffmeyer PJ, Lanzer WL, Ilstrup DM, Rowland CM. Surgical repair of chronic rotator cuff tears. A prospective long-term study. *J Bone Joint Surg Am.* 2001;83-A:71-77.
14. Cole BJ, ElAttrache NS, Anbari A. Arthroscopic rotator cuff repairs: an anatomic and biomechanical rationale for different suture-anchor repair configurations. *Arthroscopy.* 2007;23:662-669. <http://dx.doi.org/10.1016/j.arthro.2007.02.018>
15. Costouros JG, Porrmatikul M, Lie DT, Warner JJ. Reversal of suprascapular neuropathy following arthroscopic repair of massive supraspinatus and infraspinatus rotator cuff tears. *Arthroscopy.* 2007;23:1152-1161. <http://dx.doi.org/10.1016/j.arthro.2007.06.014>
16. DeBeer J, Berghs B, van Rooyen K. Arthroscopic rotator cuff repair by footprint reconstruction. *19th Annual San Diego Shoulder Meeting.* San Diego, CA: 2002.
17. Debyre J, Patie D, Elmelik E. Repair of ruptures of the rotator cuff of the shoulder. *J Bone Joint Surg Br.* 1965;47:36-42.
18. DeOrio JK, Cofield RH. Results of a second attempt at surgical repair of a failed initial rotator-cuff repair. *J Bone Joint Surg Am.* 1984;66:563-567.
19. Dockery ML, Wright TW, LaStayo PC. Electromyography of the shoulder: an analysis of passive modes of exercise. *Orthopedics.* 1998;21:1181-1184.
20. Ellman H, Hanker G, Bayer M. Repair of the rotator cuff. End-result study of factors influencing reconstruction. *J Bone Joint Surg Am.* 1986;68:1136-1144.
21. Flatow EL, Soslosky LJ, Ticker JB, et al. Excursion of the rotator cuff under the acromion. Patterns of subacromial contact. *Am J Sports Med.* 1994;22:779-788.
22. Franceschi F, Ruzzini L, Longo UG, et al. Equivalent clinical results of arthroscopic single-row and double-row suture anchor repair for rotator cuff tears: a randomized controlled trial. *Am J Sports Med.* 2007;35:1254-1260. <http://dx.doi.org/10.1177/0363546507302218>
23. Galatz LM, Connor PM, Calfee RP, Hsu JC, Yamaguchi K. Pectoralis major transfer for anterior-superior subluxation in massive rotator cuff insufficiency. *J Shoulder Elbow Surg.* 2003;12:1-5. <http://dx.doi.org/10.1067/mse.2003.128137>
24. Gartsman GM. Arthroscopic management of rotator cuff disease. *J Am Acad Orthop Surg.* 1998;6:259-266.
25. Gartsman GM, Brinker MR, Khan M. Early effectiveness of arthroscopic repair for full-thickness tears of the rotator cuff: an outcome analysis. *J Bone Joint Surg Am.* 1998;80:33-40.
26. Gartsman GM, Hammerman SM. Full-thickness tears: arthroscopic repair. *Orthop Clin North Am.* 1997;28:83-98.
27. Gerber C, Schneeberger AG, Beck M, Schlegel U. Mechanical strength of repairs of the rotator cuff. *J Bone Joint Surg Br.* 1994;76:371-380.
28. Gore DR, Murray MP, Sepic SB, Gardner GM. Shoulder-muscle strength and range of motion following surgical repair of full-thickness rotator-cuff tears. *J Bone Joint Surg Am.* 1986;68:266-272.
29. Gupta R, Leggin BG, Iannotti JP. Results of surgical repair of full-thickness tears of the rotator cuff. *Orthop Clin North Am.* 1997;28:241-248.
30. Harryman DT, 2nd, Mack LA, Wang KY, Jackins SE, Richardson ML, Matsen FA, 3rd. Repairs of the rotator cuff. Correlation of functional results with integrity of the cuff. *J Bone Joint Surg Am.* 1991;73:982-989.
31. Hatakeyama Y, Itoi E, Pradhan RL, Urayama M, Sato K. Effect of arm elevation and rotation on the strain in the repaired rotator cuff tendon. A cadaveric study. *Am J Sports Med.* 2001;29:788-794.
32. Hauser ED. Avulsion of the tendon of the subscapularis muscle. *J Bone Joint Surg Am.* 1954;36-A:139-141.
33. Hawkins RJ, Misamore GW, Hobeika PE. Surgery for full-thickness rotator-cuff tears. *J Bone Joint Surg Am.* 1985;67:1349-1355.
34. Iannotti JP, Bernot MP, Kuhlman JR, Kelley MJ, Williams GR. Postoperative assessment of shoulder function: a prospective study of full-thickness rotator cuff tears. *J Shoulder Elbow Surg.* 1996;5:449-457.
35. Ishii H, Brunet JA, Welsh RP, Unthoff HK. "Bursal reactions" in rotator cuff tearing, the impingement syndrome, and calcifying tendinitis. *J Shoulder Elbow Surg.* 1997;6:131-136.
36. Kessel L, Bayley I. *Shoulder Surgery.* New York: Springer-Verlag; 1982.
37. Kim DH, Elattrache NS, Tibone JE, et al. Biomechanical comparison of a single-row versus double-row suture anchor technique for rotator cuff repair. *Am J Sports Med.* 2006;34:407-414. <http://dx.doi.org/10.1177/0363546505281238>
38. Lafosse L, Brozka R, Toussaint B, Gobezie R. The outcome and structural integrity of arthroscopic rotator cuff repair using the double-row suture anchor technique. *Annual Meeting of the American Shoulder and Elbow Surgeons.* Chicago, IL: 2006.
39. Levine WN, ElAttrache NS, Ahmad CS. Shoulder: rotator cuff/biceps. *American Orthopaedic Society for Sports Medicine Annual Meeting.* Orlando, FL: 2008.
40. Levy HJ, Uribe JW, Delaney LG. Arthroscopic assisted rotator cuff repair: preliminary results. *Arthroscopy.* 1990;6:55-60.
41. Mansat P, Cofield RH, Kersten TE, Rowland CM. Complications of rotator cuff repair. *Orthop Clin North Am.* 1997;28:205-213.
42. Mazzocca AD, Millett PJ, Guanache CA, Santangelo SA, Arciero RA. Arthroscopic single-row versus double-row suture anchor rotator cuff repair. *Am J Sports Med.* 2005;33:1861-1868. <http://dx.doi.org/10.1177/0363546505279575>
43. McLaughlin HI, Asherman EG. Lesions of the musculotendinous cuff of the shoulder. IV. Some observations based upon the results of surgical repair. *J Bone Joint Surg Am.* 1951;33:76-86.
44. Milano G, Grasso A, Zarelli D, Deriu L, Cillo M, Fabbriani C. Comparison between single-row and double-row rotator cuff repair: a biomechanical study. *Knee Surg Sports Traumatol Arthrosc.* 2008;16:75-80. <http://dx.doi.org/10.1007/s00167-007-0382-0>
45. Mormino MA, Gross RM, McCarthy JA. Captured shoulder: a complication of rotator cuff surgery. *Arthroscopy.* 1996;12:457-461.
46. Neer CS, 2nd. Impingement lesions. *Clin Orthop Relat Res.* 1983;70-77.
47. Neer CS, Flatow EL, Lech O. Tears of the rotator cuff: Long term results of anterior acromioplasty and repair. *Orthop Trans.* 1988;12:735.
48. Nelson CO, Sileo MJ, Grossman MG, Serra-Hsu F. Single-row modified mason-allen versus double-row arthroscopic rotator cuff repair: a biomechanical and surface area comparison. *Arthroscopy.* 2008;24:941-948. <http://dx.doi.org/10.1016/j.arthro.2008.03.011>
49. Neviaser JS. Ruptures of the rotator cuff of the shoulder. New concepts in the diagnosis and operative treatment of chronic ruptures. *Arch Surg.* 1971;102:483-485.
50. Neviaser JS, Neviaser RJ, Neviaser TJ. The repair of chronic massive ruptures of the rotator cuff of the shoulder by use of a freeze-dried rotator cuff. *J Bone Joint Surg Am.* 1978;60:681-684.
51. Neviaser RJ, Neviaser TJ, Neviaser JS. Concurrent rupture of the rotator cuff and anterior dislocation of the shoulder in the older patient. *J Bone Joint Surg Am.* 1988;70:1308-1311.
52. Ozaki J, Fujimoto S, Masuhara K, Tamai S, Yoshimoto S. Reconstruction of chronic massive rotator cuff tears with synthetic materials. *Clin*

Orthop Relat Res. 1986;173-183.

53. Park JY, Lhee SH, Choi JH, Park HK, Yu JW, Seo JB. Comparison of the clinical outcomes of single- and double-row repairs in rotator cuff tears. *Am J Sports Med.* 2008;36:1310-1316. <http://dx.doi.org/10.1177/0363546508315039>

54. Park MC, Elattrache NS, Ahmad CS, Tibone JE. "Transosseous-equivalent" rotator cuff repair technique. *Arthroscopy.* 2006;22:1360 e1361-1365. <http://dx.doi.org/10.1016/j.arthro.2006.07.017>

55. Park MC, Idjadi JA, Elattrache NS, Tibone JE, McGarry MH, Lee TQ. The effect of dynamic external rotation comparing 2 footprint-restoring rotator cuff repair techniques. *Am J Sports Med.* 2008;36:893-900. <http://dx.doi.org/10.1177/0363546507313092>

56. Paulos LE, Kody MH. Arthroscopically enhanced "miniapproach" to rotator cuff repair. *Am J Sports Med.* 1994;22:19-25.

57. Posada A, Uribe JW, Hechtman KS, Tjin ATEW, Zvijac JE. Mini-deltoid splitting rotator cuff repair: do results deteriorate with time? *Arthroscopy.* 2000;16:137-141.

58. Post M, Silver R, Singh M. Rotator cuff tear. Diagnosis and treatment. *Clin Orthop Relat Res.* 1983;78-91.

59. Rahme H, Nordgren H, Hamberg H, Westerberg CE. The subacromial bursa and the impingement syndrome. A clinical and histological study of 30 cases. *Acta Orthop Scand.* 1993;64:485-488.

60. Reinold MM, Wilk KE, Fleisig GS, et al. Electromyographic analysis of the rotator cuff and deltoid musculature during common shoulder external rotation exercises. *J Orthop Sports Phys Ther.* 2004;34:385-394. <http://dx.doi.org/10.2519/jospt.2004.0665>

61. Reinold MM, Wilk KE, Reed J, Crenshaw K, Andrews JR. Interval sport programs: guidelines for baseball, tennis, and golf. *J Orthop Sports Phys Ther.* 2002;32:293-298.

62. Rodeo SA, Arnoczky SP, Torzilli PA, Hidaka C, Warren RF. Tendon-healing in a bone tunnel. A biomechanical and histological study in the dog. *J Bone Joint Surg Am.* 1993;75:1795-1803.

63. Rokito AS, Cuomo F, Gallagher MA, Zuckerman JD. Long-term functional outcome of repair of large and massive chronic tears of the rotator cuff. *J Bone Joint Surg Am.* 1999;81:991-997.

64. Rokito AS, Zuckerman JD, Gallagher MA, Cuomo F. Strength after surgical repair of the rotator cuff. *J Shoulder Elbow Surg.* 1996;5:12-17.

65. Romeo AA, Hang DW, Bach BR, Jr., Shott S. Repair of full thickness rotator cuff tears. Gender, age, and other factors affecting outcome. *Clin Orthop Relat Res.* 1999;243-255.

66. Severud EL, Ruotolo C, Abbott DD, Nottage WM. All-arthroscopic versus mini-open rotator cuff repair: a long-term retrospective outcome comparison. *Arthroscopy.* 2003;19:234-238. <http://dx.doi.org/10.1053/jars.2003.50036>

67. Sugaya H, Maeda K, Matsuki K, Moriishi J. Functional and structural outcome after arthroscopic full-thickness rotator cuff repair: single-row versus dual-row fixation. *Arthroscopy.* 2005;21:1307-1316. <http://dx.doi.org/10.1016/j.arthro.2005.08.011>

68. Unthoff HK, Sarkar K. Surgical repair of rotator cuff ruptures. The importance of the subacromial bursa. *J Bone Joint Surg Br.* 1991;73:399-401.

69. Waltrip RL, Zheng N, Dugas JR, Andrews JR. Rotator cuff repair. A biomechanical comparison of three techniques. *Am J Sports Med.* 2003;31:493-497.

70. Watson M. Major ruptures of the rotator cuff. The results of surgical repair in 89 patients. *J Bone Joint Surg Br.* 1985;67:618-624.

71. Weiler A, Hoffmann RF, Bail HJ, Rehm O, Sudkamp NP. Tendon healing in a bone tunnel. Part II: Histologic analysis after biodegradable interference fit fixation in a model of anterior cruciate ligament reconstruction in sheep. *Arthroscopy.* 2002;18:124-135.

72. Weiler A, Peine R, Pashmineh-Azar A, Abel C, Sudkamp NP, Hoffmann RF. Tendon healing in a bone tunnel. Part I: Biomechanical results after biodegradable interference fit fixation in a model of anterior cruciate ligament reconstruction in sheep. *Arthroscopy.* 2002;18:113-123.

73. Wilk KE. The shoulder. In: Malone TR, McPoil T, Nitz A, eds. *Orthopedic and Sports Physical Therapy.* St Louis, MO: Mosby; 1997:401-458.

74. Wilk KE, Crockett HS, Andrews JR. Rehabilitation after rotator cuff surgery. *Tech Shoulder Elbow Surg.* 2000;1:128-144.

75. Wolfgang GL. Surgical repair of tears of the rotator cuff of the shoulder. Factors influencing the result. *J Bone Joint Surg Am.* 1974;56:14-26.

76. Yamaguchi K. Complications of rotator cuff repair. *Tech Orthop.* 1997;12:33-41.

77. Yamaguchi K, Levine WN, Marra G, Galatz LM, Klepps S, Flatow EL. Transitioning to arthroscopic rotator cuff repair: the pros and cons. *Instr Course Lect.* 2003;52:81-92.

 **MORE INFORMATION**
WWW.JOSPT.ORG

APPENDIX A

FACTORS AFFECTING THE POSTOPERATIVE ROTATOR CUFF REPAIR REHABILITATION PROGRAM			
1. Surgical approach	Poor	U-shaped	Adequate
Open and mini-open procedures	4. Fixation method	L-shaped	Poor
All-arthroscopic	Single-row	Retracted	10. Patient characteristics
2. Size of the tear	Double-row	7. Mechanism of failure	Smoking
Small (<1 cm)	Double-row (hybrid procedure)	Acute: traumatic single event	Diabetes
Medium (1-3 cm)	Suture bridge	Biological: gradual wear	General health
Large (3-5 cm)	5. Location of tear	8. Timing of surgery	11. Timing of surgery
Massive (>5cm)	Supraspinatus	Immediate	Supervised
Number of tendons involved	Infraspinatus/teres minor	Delayed	Independent home program
3. Tissue quality	Subscapularis	9. Rotator cuff tissue quality anterior and posterior to the tear site	12. Physician philosophical approach
Good	6. Type of tear	Good	Conservative
Adequate	Crescent-shaped		Aggressive

REHABILITATION FOLLOWING ARTHROSCOPIC ROTATOR CUFF REPAIR: SMALL TO MEDIUM TEARS

Phase I: Immediate Postsurgical Phase (Days 1-14)

Precautions:

- No lifting of objects
- No excessive shoulder extension
- No excessive arm motions
- No overhead motions
- No excessive external rotation (ER)/internal rotation (IR) range of motion (ROM) for 6-8 weeks unless directed by physician
- No excessive stretching or sudden movements
- No supporting of body weight by hands
- Keep incision clean and dry

Goals:

- Maintain integrity of the repair
- Promote tissue healing
- Gradually increase passive ROM
- Diminish pain and inflammation
- Prevent muscular inhibition

Days 1 to 6

- 30° abduction pillow brace
- Pendulum exercises
- Active assisted ROM exercises (L-Bar)
 - ER/IR in scapular plane at 45° of abduction (pain-free ROM)
- Passive ROM
 - Flexion to tolerance (painful ROM)
 - ER/IR in scapular plane at 45° of abduction (pain-free ROM)*

* Limit ER and IR ROM to 25°-30°

Elbow/hand gripping and ROM exercises: perform 4-6 times per day

Submaximal pain-free shoulder isometrics (initiate days 4-5)

- Flexion with elbow bent to 90°
 - ER
 - IR
 - Elbow flexors
- Cryotherapy for pain and inflammation
- Ice 15-20 min, approximately 4-6 times per day, or as pain determines

Sleeping

- Sleep in pillow brace until instructed to discontinue

Days 7 to 14

- Continue use of pillow brace
 - Pendulum exercises
 - Progress passive ROM to tolerance
 - Flexion to at least 115°
 - ER in scapular plane at 45° abduction to 30°-35°
 - IR in scapular plane at 45° abduction to 30°-35°
 - Active assisted ROM exercises (L-Bar)
 - ER/IR in scapular plane at 45° abduction
 - Flexion to tolerance*
- * Therapist provides assistance by supporting arm, especially with arm lowering
- Continue elbow/hand ROM and gripping exercises
- Continue isometrics (submaximal and subpainful)*
- * May apply electrical muscle stimulation to shoulder external rotators for muscle re-education
- Flexion with bent elbow
 - Extension with bent elbow
 - Abduction with bent elbow

- ER/IR with arm in scapular plane
- Elbow flexion

Initiate rhythmic stabilization ER/IR at 45° abduction

Continue use of ice for pain control

- Use ice at least 6-7 times per day

Sleeping

- Continue sleeping in brace until physician instructs when to discontinue

Phase II: Protection Phase (Day 15-Week 6)

Precautions:

- No heavy lifting of objects
- No carrying heavy objects
- No excessive behind the back movements
- No supporting of body weight by hands and arms
- No sudden jerking motions

Goals:

- Allow healing of soft tissue
- Do not overstress healing tissue
- Gradually restore full passive ROM (weeks 4-5)
- Re-establish dynamic shoulder stability
- Decrease pain and inflammation

Days 15-28

Continue use of sling or brace (physician or therapist will determine when to discontinue)

Passive ROM to tolerance

- Flexion to 140°-155°
- ER at 90° abduction to 45°-50°
- IR at 90° abduction to 30°-45°

Active assisted ROM to tolerance

- Flexion (continue use of arm support)
- ER/IR in scapular plane at 45° abduction
- ER/IR at 90° abduction

Rhythmic stabilization drills

- ER/IR in scapular plane
- Flexion/extension at 100° flexion and 125° flexion

Continue all isometric contractions

Initiate scapular isometrics

Continue use of cryotherapy as needed

Continue all precautions

- No lifting
- No excessive motion

Weeks 4-5

Patient should exhibit full passive ROM by week 4

Continue all exercises listed above

Initiate ER/IR strengthening using exercise tubing at 0° of abduction (use towel roll)

Initiate manual resistance ER supine in scapular plane (light resistance)

Initiate prone rowing with arm at 30° of abduction to neutral arm position

Initiate prone shoulder extension with elbow flexed to 90°

Initiate ER strengthening exercises

Initiate isotonic elbow flexion

Continue use of ice as needed

May use heat prior to ROM exercises

May use pool for light AROM exercises

Rhythmic stabilization exercises (flexion at 45°, 90°, 125° and ER/IR)

Weeks 5-6

May use heat prior to exercises

Continue active assisted ROM and stretching exercises, especially for movements that are not full

- Shoulder flexion
- ER at 90° abduction

Initiate active ROM exercises

- Shoulder flexion scapular plane to 90° of flexion
- Shoulder abduction to 90° of abduction

Progress isotonic strengthening exercise program

- ER tubing
- Side-lying ER
- Prone rowing at 45° of abduction
- Prone horizontal abduction (bent elbow) at 90° of abduction
- Biceps curls (isotonics) (very light resistance)

Phase III: Intermediate Phase (Weeks 7-14)

Goals:

Full active ROM (weeks 8-10)

Maintain full passive ROM

Dynamic shoulder stability

Gradual restoration of shoulder strength

Gradual return to functional activities

Week 7

Continue stretching and passive ROM (as needed to maintain full ROM)

Continue dynamic stabilization drills

Progress active ROM and light strengthening program

- ER/IR tubing
- ER side-lying
- Lateral raises to 90° of abduction*
- Full can in scapular plane to 90° of elevation*
- Prone rowing
- Prone horizontal abduction
- Prone extension
- Elbow flexion
- Elbow extension

* Patient must be able to elevate arm without shoulder or scapular hiking before initiating isotonics; if unable, continue dynamic rhythmic stabilization glenohumeral joint exercises

Week 8

Continue all exercise listed above

If physician permits, may initiate light functional activities

Week 10

Continue all exercise listed above

Progress to fundamental shoulder exercises (**APPENDIX D**)

Therapist may initiate isotonic resistance (0.5-kg weight) during flexion and abduction*

* If nonpainful normal motion is exhibited and no substitution patterns

Weeks 11-14

Progress all exercises

- Continue ROM and flexibility exercises
- Progress strengthening program (increase 0.5 kg/10 days if nonpainful)*

* Be sure when progressing patient no residual pain is present following exercises

Phase IV: Advanced Strengthening Phase (Weeks 15-24)

Goals:

Maintain full nonpainful ROM

Enhance functional use of upper extremity

Improve muscular strength and power

Gradual return to functional activities

Weeks 15-20

Continue ROM and stretching to maintain full ROM

Self-capsular stretches

Progress shoulder strengthening exercises

- Fundamental shoulder exercises

Initiate interval golf program (if appropriate)⁶¹

Weeks 20-24

Continue all exercises listed above

Progress golf program to playing golf (if appropriate)

Initiate interval tennis program (if appropriate)⁶¹ week 24 (may wait until 6 mo to initiate, physician will determine)

May initiate swimming, week 26

Phase V: Return to Activity Phase (Weeks 24-36)

Goals:

Gradual return to strenuous work activities

Gradual return to recreational sport activities

Maintain integrity of rotator cuff repair

Weeks 24-36

Continue fundamental shoulder exercise program (at least 4 times weekly)

Continue stretching, if motion is tight

Continue progression to sport and/or work activity/participation⁶¹

* Should continue fundamental shoulder exercise program until 12 mo following surgery or until instructed to discontinue

Copyright © 2004 by the Advanced Continuing Education Institute, LLC. All Rights Reserved. Any redistribution or reproduction of any materials herein is strictly prohibited.

REHABILITATION FOLLOWING ARTHROSCOPIC ROTATOR CUFF REPAIR: MEDIUM TO LARGE TEARS

Phase I: Immediate Postsurgical Phase (Days 1-14)

Precautions:

- No lifting of objects
- No excessive arm motions
- No excessive external rotation (ER) or internal rotation (IR) motions
- No excessive shoulder extension
- No excessive stretching or sudden movements
- No supporting of body weight by hands
- Keep incision clean and dry
- Precautions isolated supraspinatus repair
 - Caution with excessive passive and active IR range of motion (ROM) for 6-8 weeks
- Precautions combined supraspinatus and infraspinatus repair
 - Caution with excessive passive and active IR ROM for 8 weeks
- Precautions isolated subscapularis repair
 - No ER for 4 weeks
 - Progress ER slowly from 4 weeks until 8-10 weeks

Goals:

- Maintain integrity of the repair
- Promote tissue healing
- Gradually increase passive ROM
- Diminish pain and inflammation
- Prevent muscular inhibition

Days 1 to 6

- 30° abduction pillow brace
- Pendulum exercises
- Active assisted ROM exercise (L-Bar)
 - ER/IR in scapular plane at 45° of abduction (pain-free ROM)
- Passive ROM
 - Flexion to tolerance (painful ROM)
 - ER/IR in scapular plane at 45° of abduction (pain-free ROM)*

* Limit ER and IR ROM to 25°-30°

- Elbow/hand gripping and ROM exercises: perform 4-6 times per day
- Submaximal pain-free isometrics (initiate days 4-5)
 - Flexion with elbow bent to 90°
 - ER
 - IR
 - Elbow flexors

Cryotherapy for pain and inflammation

- Ice 15-20 min approximately 4-6 times daily
- Sleeping
- Sleep in pillow brace until instructed to discontinue

Days 7 to 14

- Continue use of pillow brace
- Pendulum exercises
- Progress passive ROM to tolerance
 - Flexion to at least 115°
 - ER in scapular plane at 45° abduction to 30°-35°
 - IR in scapular plane at 45° abduction to 30°-35°
- Active assisted ROM exercises (L-Bar)
 - ER/IR in scapular plane at 45° abduction
 - Flexion to tolerance*

* Therapist provides assistance by supporting arm, especially with arm lowering; initiate at 14 days postoperatively

Continue elbow/hand ROM and gripping exercises

Continue isometrics (submaximal and subpainful)*

* May apply electrical muscle stimulation to shoulder external rotators for muscle re-education; initiate at 10-14 days postoperatively

- Flexion with bent elbow
- Extension with bent elbow
- Abduction with bent elbow
- ER/IR with arm in scapular plane
- Elbow flexion

Initiate rhythmic stabilization ER/IR at 45° abduction

Continue use of ice for pain control

- Use ice at least 6-7 times daily

Sleeping

- Continue sleeping in brace until physician instructs to discontinue use

Phase II: Protection Phase (Day 15-Week 8)

Precautions:

- No heavy lifting of objects
- No carrying heavy objects
- No excessive behind the back movements
- No supporting of body weight by hands and arms
- No sudden jerking motions

Goals:

- Allow healing of soft tissue
- Do not overstress healing tissue
- Gradually restore full passive ROM (week 4-5)
- Re-establish dynamic shoulder stability
- Decrease pain and inflammation

Days 15-28

Continue use of sling or brace (physician or therapist will determine when to discontinue)

Passive ROM to tolerance

- Flexion to 140°-155°
- ER at 90° abduction to 30°-45° at week 4
- IR at 90° abduction to 30°-45° at week 4

Active assisted ROM to tolerance

- Flexion (continue use of arm support)
- ER/IR in scapular plane at 45° abduction
- ER/IR at 90° abduction

Rhythmic stabilization drills

- ER/IR in scapular plane
- Flexion/extension at 100° flexion and 125° flexion

Continue all isometric contractions

Initiate scapular isometrics

Continue use of cryotherapy as needed

Continue all precautions

- No lifting
- No excessive motion

Weeks 4-5

Patient should exhibit full passive ROM by weeks 4-6

Continue all exercises listed above

Initiate ER/IR strengthening using exercise tubing at 0° of abduction (use towel roll)

Initiate manual resistance ER supine in scapular plane (light resistance)

Initiate prone rowing with arm at 30° abduction to neutral arm position

Initiate prone shoulder extension with elbow flexed to 90°

Initiate ER strengthening exercises

Initiate isotonic elbow flexion
Continue use of ice as needed
May use heat prior to ROM exercises
May use pool for light active ROM exercises
Rhythmic stabilization exercises (flexion at 45°, 90°, 125° and ER/IR at multiple angles)

Weeks 6-8

May use heat prior to exercises

Continue AAROM and stretching exercises

- Especially for movements that are not full
 - Shoulder flexion stopping at 90° in side-lying (gravity eliminated position)
 - ER at 90° abduction

Initiate active ROM exercises

- Shoulder flexion in scapular plane in side-lying at week 6 (no weight)
- Shoulder abduction at week 8 (if no substitution pattern or pain is present)

Progress isotonic strengthening exercise program

- ER tubing
- Side-lying ER
- Prone rowing
- Prone horizontal abduction (bent elbow)
- Biceps curls (isotonics) very light weight

Phase III: Intermediate Phase (Weeks 8-16)

Goals:

Full active ROM (week 8-10)
Maintain full passive ROM
Dynamic shoulder stability
Gradual restoration of shoulder strength
Gradual return to functional activities

Week 8

Continue stretching and passive ROM (as needed to maintain full ROM)

Continue dynamic stabilization drills

Progress active ROM "light" strengthening program

- ER/IR tubing
- ER side-lying
- Lateral raises to 90° of abduction*
- Full can in scapular plane to 90° of flexion*
- Prone rowing
- Prone horizontal abduction
- Prone extension
- Elbow flexion
- Elbow extension

** Patient must be able to elevate arm without shoulder or scapular hiking before initiating isotonic; if unable, continue glenohumeral joint stabilization drills and exercises*

Continue all exercises listed above

If physician permits, may initiate light functional activities

Week 10

Continue all exercises listed above

Progress to fundamental shoulder exercises (**APPENDIX D**)

Therapist may initiate isotonic resistance (0.5-kg weight) during flexion and abduction*

** If nonpainful normal motion is exhibited and no substitution pattern is present*

Weeks 12-16

Progress all exercises

- Continue ROM and flexibility exercises
- Progress strengthening program (increase 0.5 kg/10 days if nonpainful)*

** Be sure when progressing patient no residual pain is present following exercises*

Phase IV: Advanced Strengthening Phase (Weeks 16-26)

Goals:

Maintain full nonpainful ROM

Maintain integrity of repair

Enhance functional use of upper extremity

Improve muscular strength and power

Gradual return to functional activities

Weeks 16-20

- Continue ROM and stretching to maintain full ROM
- Self-capsular stretches
- Progress shoulder strengthening exercises
 - Fundamental shoulder exercises
- Initiate interval golf program (if appropriate),⁶¹ week 16

Weeks 20-26

- Continue all exercises listed above
- Gradually increase resistance but patient should exhibit no pain during or after exercise and no substitution pattern

Phase V: Return to Activity Phase (Weeks 26-36)

Goals:

Gradual return to strenuous work activities

Gradual return to recreational sport activities

Week 26

Continue fundamental shoulder exercise program (at least 4 times weekly)*

Progress golf program to playing golf (if appropriate)⁶¹

Initiate interval tennis program (if appropriate)⁶¹

May initiate light swimming (if appropriate), weeks 26-29

Continue stretching, if motion is tight

Continue progression to sport or work activity

** Should continue fundamental shoulder exercise program until 12 mo following surgery or until instructed to discontinue*

Copyright © 2004 by the Advanced Continuing Education Institute, LLC. All Rights Reserved. Any redistribution or reproduction of any materials herein is strictly prohibited.

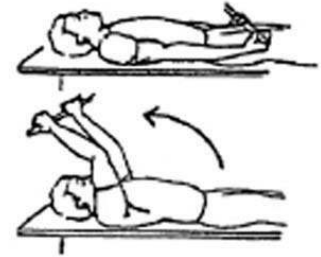
APPENDIX D

FUNDAMENTAL SHOULDER EXERCISES

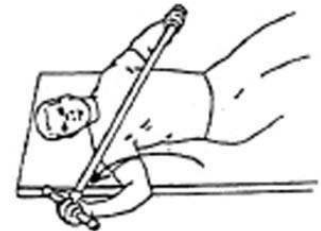Range of Motion Exercise

1. **L-Bar Flexion:** Lie on back and grip L-Bar between index finger and thumb, elbows straight. Raise both arms overhead as far as possible, keeping thumbs up. Hold for _____ seconds and repeat _____ times.

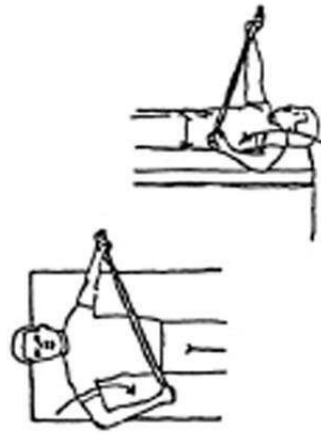
Illustration



2. **L-Bar External Rotation, Scapular Plane:** Lie on back with involved arm 45° from body and elbow bent at 90°. Grip L-Bar in the hand of involved arm and keep elbow in flexed position. Using uninvolvement arm, push involved arm into external rotation. Hold for _____ seconds, return to starting position. Repeat _____ times.



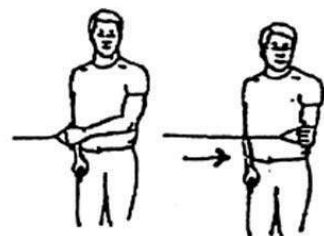
3. **L-Bar Internal Rotation, Scapular Plane:** Lie on back with involved arm 45° from body and elbow bent at 90°. Grip L-Bar in the hand of involved arm and keep elbow in flexed position. Using the uninvolvement arm, push involved arm into internal rotation. Hold for _____ seconds, return to starting position. Repeat _____ times.



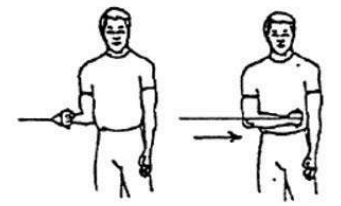
Strengthening Exercise

1. **Tubing, External Rotation:** Standing with involved elbow fixed at side, elbow bent to 90° and involved arm across the front of the body. Grip tubing handle while the other end of tubing is fixed. Pull out with arm, keeping elbow at side. Return tubing slowly and controlled. Perform _____ sets of _____ reps.

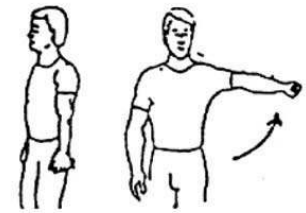
Illustration



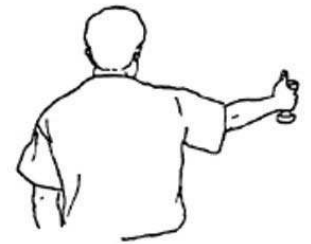2. **2. Tubing, Internal Rotation:** Standing with elbow at side fixed at 90° and shoulder rotated out. Grip tubing handle while other end of tubing is fixed. Pull arm across body keeping elbow at side. Return tubing slowly and controlled. Perform _____ sets of _____ reps.



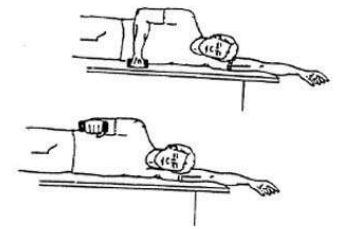
3. **3. Lateral Raises to 90°:** Standing with arm at side, elbow straight, and palm against side. Raise arm to side, rotating palm up as arm reaches 90°. Do not go above shoulder height. Hold for _____ seconds and lower slowly. Perform _____ sets of _____ reps.



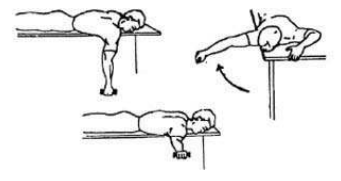
4. **4. "Full Can":** Stand with elbow extended and thumb up. Raise arm to shoulder level at 30° angle in front of body. Do not go above shoulder level. Hold for _____ seconds and lower slowly. Perform _____ sets of _____ reps.



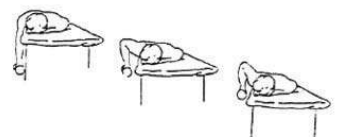5. **5. Sidelying External Rotation:** Lie on uninvolved side, with involved arm at side of body and elbow bent to 90°. Keeping the elbow of involved arm fixed to side, raise arm. Hold _____ seconds and lower slowly. Perform _____ sets of _____ reps.



6. **6. Prone Horizontal Abduction:** Lie on table, face down, with involved arm hanging straight to floor and palm facing down. Raise arm out to the side, parallel to the floor. Hold _____ seconds and lower slowly. Perform _____ sets of _____ reps.



7. **7. Prone Rowing:** Lying on stomach with involved arm hanging over the side of the table, dumbbell in hand and elbow straight. Slowly raise arm, bending elbow, and bring dumbbell as high as possible. Hold at the top for _____ seconds, then lower slowly. Perform _____ sets of _____ reps.



Reproduced with permission from Wilk KE, Crockett HS, Andrews JR. Rehabilitation after rotator cuff repair surgery. *Tech Shoulder Elbow Surg.* 2000;1:128-144. Copyright © 2004 by the Advanced Continuing Education Institute, LLC.