

# Topographic Analysis of the Capitellum and Distal Femoral Condyle: Finding the Best Match for Treating Osteochondral Defects of the Humeral Capitellum



Jason J. Shin, M.D., Marc Haro, M.D., Adam B. Yanke, M.D., Randy Mascarenhas, M.D., Anthony A. Romeo, M.D., Brian J. Cole, M.D., M.B.A., Nozomu Inoue, M.D., Ph.D., and Nikhil N. Verma, M.D.

**Purpose:** The purpose of this study was to determine the donor zone of most congruent topographic match by comparing 4 donor sites from the femur with 4 potential recipient sites of osteochondritis dissecans at the capitellum. **Methods:** Computed tomography was performed on 5 right elbows and 6 right medial and 6 right lateral distal femoral hemicondyles, which included the femoral notch. Three-dimensional computed tomography models were created and exported into point-cloud models. A local coordinate map of the distal humerus and distal femoral articular surfaces was created. The capitellum was compared with the medial and lateral distal femoral condyles, with 2 donor zones in each condyle (medial trochlea and medial intercondylar notch or lateral trochlea and lateral intercondylar notch). In each capitellum 4 combinations of 10-mm defects were simulated (central and lateral, 30° and 45° anterior to shaft of humerus), resulting in 480 capitellum-femur comparative combinations being tested. The capitellum surfaces were virtually placed on a point on the femoral articular surface in 3-dimensional space. The least distances (i.e., the shortest distance from the point in question to the corresponding point in space) between the point clouds on the distal humerus and distal femoral articular surfaces were calculated. **Results:** There was a less than 0.1-mm difference in the topographic articular surface match among the 4 commonly used donor sites of the distal femur and 4 recipient sites of the capitellum. However, the best match for any given 10-mm capitellar defect (central 30°, central 45°, lateral 30°, and lateral 45°) was the same such that the lateral trochlea on the femur always yielded the best fit compared with the 3 other graft locations ( $P < .005$ ). **Conclusions:** Our results indicate that there is a less than 0.1-mm difference in the topographic articular surface match among the 4 commonly used donor sites of the distal femur and the capitellum. The findings suggest that all 4 donor sites provide close articular matching for the capitellum articular surface, with the lateral trochlea articular surface providing the best match. **Clinical Relevance:** These data suggest that a single donor plug may be obtained from multiple sites in the knee and placed into capitellar lesions with an excellent topographic articular surface match. The findings of our study will be useful to surgeons when managing capitellar osteochondritis dissecans lesions.

**O**steochondritis dissecans (OCD) of the humeral capitellum is a localized lesion resulting in separation and fragmentation of the cartilage and underlying bone. Although OCD is largely considered to be an idiopathic condition, its relatively high incidence in adolescent baseball players and gymnasts supports

evidence that repetitive microtrauma to the radio-capitellar joint, as well as overuse injury to the anterolateral capitellum, which has a vulnerable epiphysis with a tenuous blood supply, may be responsible for this condition as well. Patients often present with lateral elbow pain, loss of motion, mechanical symptoms, and

*From the Division of Sports Medicine, Department of Orthopedic Surgery, Rush University Medical Center, Chicago, Illinois, U.S.A.*

*The authors report the following potential conflict of interest or source of funding: The cadavers used in this study were funded through the LiveActive With Rush Fund. A.A.R. receives support from Arthrex, DJO Surgical, Smith & Nephew, and Ossur. B.J.C. receives support from Arthrex, DJ Orthopaedics, Johnson & Johnson, Regentis, Zimmer, Medipost, Smith & Nephew, Carticept, and Regentis. N.N.V. receives support from Smith & Nephew, MinInvasive, Arthrex, Vindico Medical-Orthopedics Hyperguide, and Omeros.*

*Received April 30, 2014; accepted November 21, 2014.*

*Address correspondence to Jason J. Shin, M.D., Department of Orthopaedics, Royal University Hospital, University of Saskatchewan, 103 Hospital Drive, Saskatoon, SK S7N 0W8, Canada. E-mail: [jasonjwshin@gmail.com](mailto:jasonjwshin@gmail.com)*

*© 2015 by the Arthroscopy Association of North America  
0749-8063/14369/\$36.00*

*<http://dx.doi.org/10.1016/j.arthro.2014.11.039>*

effusion. Early in the disease process, lesions can be difficult to appreciate on plain radiographs. It is often not until late in the disease process that sclerosis, articular surface irregularity, or loose bodies can be seen on radiographs.<sup>1,2</sup>

Magnetic resonance imaging is a sensitive tool to diagnose capitellar OCD, and it can also be very useful in aiding in the establishment of a treatment plan. Capitellar OCD lesions that do not show signs of instability can often be initially treated conservatively, especially in patients with open growth plates. If there are radiographic signs of fragment instability, conservative measurements fail, or there are signs of more advanced disease, surgery may be indicated.

Several authors have reported significantly improved short- and long-term results with osteochondral autograft transplantation surgery (OATS) as opposed to isolated debridement of the lesion.<sup>3-5</sup> OATS has been proposed to treat lesions that involve 50% of the articular surface or more. The donor plugs are press-fitted into the lesion to restore the surface topography and to provide subchondral replacement in the defect.<sup>6</sup> One difficult aspect of this procedure is ascertaining where the optimal graft harvest site is located. Most frequently, grafts are harvested from the periphery of the femoral condyle, at the level of the patellofemoral joint, away from the weight-bearing surfaces, and more specifically, the superolateral aspect of the lateral femoral condyle, as well as the intercondylar notch, has been described.<sup>7-9</sup> However, no studies to our knowledge have evaluated the topographic osteochondral similarities of the capitellum and the distal femur.

The purpose of this study was to determine the donor zone of most congruent topographic match by comparing 4 donor sites from the femur with 4 potential recipient sites of OCD at the capitellum. Our hypothesis was that each distal femoral donor site would provide a good match to the capitellar surface.

## Methods

### Specimen Preparation

Institutional review board exemption was approved for this computational analysis study using cadaveric specimens. We obtained 5 fresh-frozen right elbows and 6 right medial and lateral distal femoral hemicondyles from human cadavers from a tissue bank (Biological Resource Center of Illinois, Rosemont, IL). No specimens came from the same cadaver (i.e., the elbows were not matched to the knees). The distal femoral condyles were used to simulate donor sites. After all soft tissue was removed from the specimens, computed tomography (CT) images of the specimens were acquired in the coronal, axial, and sagittal planes by use of 0.625-mm contiguous slices (120 kV, 100 mA, 1.0-second duration, 20-cm field of view, 512 × 512

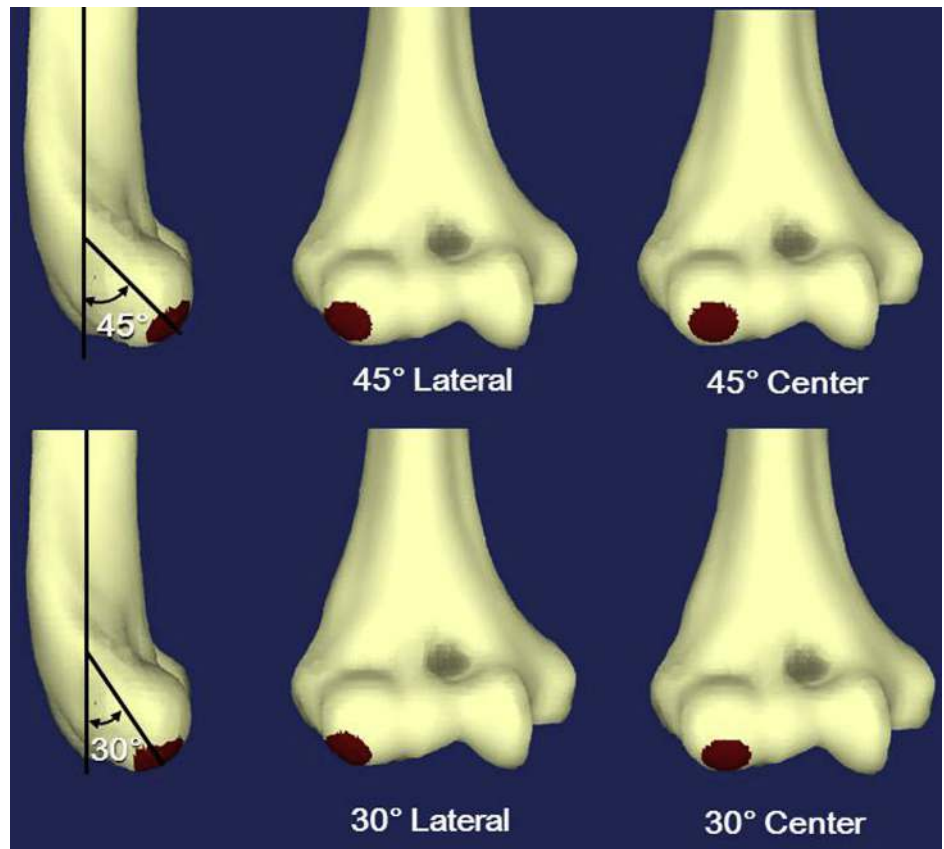
matrices). There was no evidence of degenerative changes on the distal humeri or femoral hemicondyles, either grossly or on CT imaging. An image-processing software program (Mimics; Materialise, Leuven, Belgium) was used to create 3-dimensional (3D) CT models of the distal humerus and the femoral condyles. To define the joint surface area covered by cartilage for the graft harvest site on the distal femur, segmentation was performed for both the cartilage and the subchondral bone, individually. Point-cloud models—sets of data points in a 3D coordinate system—were then acquired using the 3D reconstruction software package.

### Three-Dimensional CT Computer Model Creation of Capitellum Articular Surface Defect

Capitellum articular surface defects, 10 mm in diameter, were created at 4 locations on each capitellum joint surface: center and lateral third of the capitellum at 30° and 45° anterior relative to the shaft of the humerus (Fig 1). The locations of the capitellar lesions were chosen based on our clinical experience, as well as what has previously been described in the literature.<sup>2,10</sup> The humerus was virtually rotated 30° or 45° posteriorly (shoulder extension), and the centroid of the center defect was determined as the most distal point within the capitellum. The point-cloud data within a distance of 5.0 mm from the centroid were defined as the dataset of the center defect. The lateral defects at 30° and 45° were created by moving the center defects laterally until the most lateral edge of the defects reached the edge of the capitellum.

### Three-Dimensional CT Computer Model Creation of Distal Femoral Articular Surfaces

The subchondral bone area covered by the cartilage at the distal femur was determined as a contact area with the cartilage model by using a least-distance algorithm. Within the subchondral bone area in the distal femur, 4 locations were selected as donor sites: lateral trochlea, lateral intercondylar notch, medial trochlea, and medial intercondylar notch. Regarding the trochlea, we used a modification of the method described by Schub et al.,<sup>7</sup> and selected regions of interest were defined as the midpoint between the most proximal tip to the joint line on the sagittal plane, on the lateral- or medial-most edge of the less weight-bearing portion of the condyle. Regarding the intercondylar notch, which was visualized in a flexed knee position and in the coronal plane, locations were described as a clock face, with regions of interest defined as the 10- and 2-o'clock positions. Because only right knees were used, the simulated donor sites were centered at the 10-o'clock position on the lateral intercondylar notch and at the 2-o'clock position on the medial intercondylar notch. The simulated donor regions of interest were 10 mm in diameter and are illustrated in Figure 2. These regions were



**Fig 1.** Four donor sites in the right elbow.

chosen as typical regions from which 10-mm plugs may be harvested with minimal donor-site morbidity. Simulated lesions and donor plugs were limited to 10 mm in diameter because larger lesions would be better treated by either harvesting multiple, smaller grafts or using osteochondral allografts.

### Three-Dimensional Articular Surface Matching of Capitellum-Femur

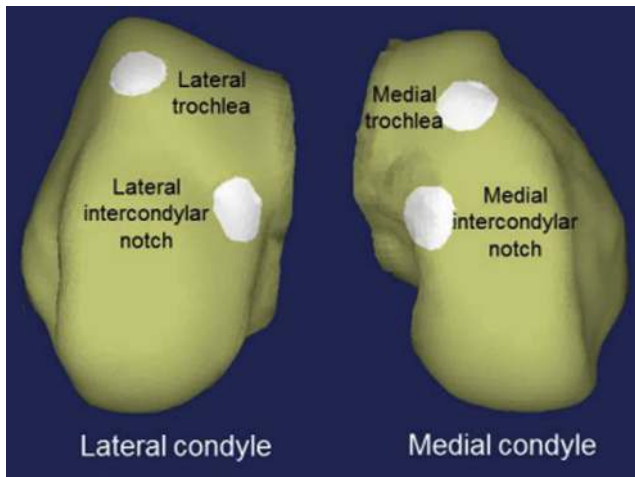
The subchondral surfaces of 5 capitella were compared with 6 medial and 6 lateral distal femoral condyles with 2 donor zones in each condyle (medial trochlea and medial intercondylar notch or lateral trochlea and lateral intercondylar notch). Although cartilage segmentation was performed to define sites of harvest on the distal femur, cartilage surface topographic matching was not performed. In each capitellum, 4 combinations of 10-mm defects were simulated (central 30°, central 45°, lateral 30°, and lateral 45°), resulting in 480 capitellum-femur comparative combinations being tested (5 capitella  $\times$  4 defect locations  $\times$  [(6 medial femurs  $\times$  2 harvest sites) + (6 lateral femurs  $\times$  2 harvest sites)]).

The capitellum articular surface model was virtually placed on the surface of the distal femoral condyle model. Orientation of the capitellum articular surface model was adjusted so that its axis matched that of the femoral condyle. Distances between the capitellum

articular surface model and the donor femoral surface were calculated in 3D space. The “least distance” was defined as the shortest distance from the point in question to the corresponding point in space, where a perfect congruent match would equal a least distance of 0.00 mm for the given data points on the simulated articular surfaces. A mean value of the least distances was calculated for each position and each orientation of the capitellum articular surface model (Fig 3). The capitellum surface model was then rotated 360° around the axis perpendicular to the articular surface in 1° increments, and the least distance was calculated at each rotating angle (Fig 4). This was performed for all combinations of simulated graft donor sites on the femoral condyles and the recipient capitellum surfaces.

### Statistical Analysis

Analysis was performed using repeated-measures analysis of variance for a given region of the capitellum (central *v* lateral and 30° *v* 45°). Within each given defect, the fit was compared among different femoral condyle sources (lateral trochlea at 45°, lateral intercondylar notch at 10-o’clock position, medial trochlea, and medial intercondylar notch at 2-o’clock position). If the analysis of variance result was significant, post hoc analysis was performed with a Tukey HSD (honest significant difference) test. Significance was set at  $P < .05$ .



**Fig 2.** Donor sites in the right lateral and medial hemicondyles.

### Results

The mean width of the medial condyles measured  $24.9 \pm 1.2$  mm (range, 23.5 to 26.8 mm) (mean age,  $21.0 \pm 5.4$  years), whereas the lateral condyles measured  $28.4 \pm 2.8$  mm (range, 24.1 to 32.5 mm) (mean age,  $24.5 \pm 6.6$  years). The mean capitellum width was  $16.9 \pm 0.9$  mm (range, 15.5 to 17.7 mm) (mean age,  $61.8 \pm 15.6$  years) (Table 1).

For a 10-mm defect in the central  $30^\circ$  region of the capitellum, grafts taken from the distal femur restored topography with a mean least-distance difference ranging between  $0.417 \pm 0.021$  mm and  $0.489 \pm 0.035$  mm, whereas the central  $45^\circ$  capitellum defect was restored with a mean least-distance difference ranging between  $0.435 \pm 0.020$  mm and  $0.506 \pm 0.029$  mm. For a 10-mm defect in the lateral  $30^\circ$  region of the capitellum, grafts taken from the distal femur restored topography with a mean least-distance difference ranging between  $0.446 \pm 0.020$  mm and  $0.512 \pm 0.027$  mm, whereas the lateral  $45^\circ$  capitellum defect was restored with a mean least-distance difference ranging between  $0.441 \pm 0.018$  mm and  $0.504 \pm 0.022$  mm. The mean least distances of all combinations are summarized in Table 2.

The best match for any given 10-mm capitellar defect (central  $30^\circ$ , central  $45^\circ$ , lateral  $30^\circ$ , and lateral  $45^\circ$ ) was the same such that the lateral trochlea on the femur always yielded the best fit compared with the 3 other donor graft locations ( $P < .005$ ). Our results indicate that there is a less than 0.1-mm difference in the topographic articular surface match among the 4 commonly used donor sites of the distal femur and 4 recipient sites of the capitellum.

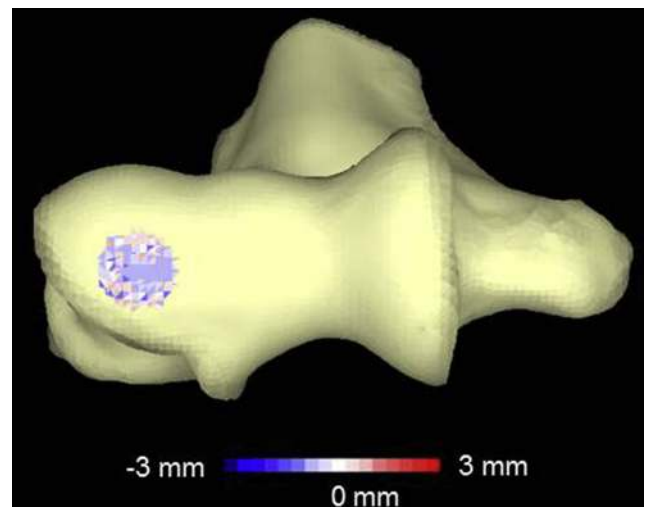
### Discussion

The principal finding of this investigation is that all 4 donor sites provide close articular matching for the

capitellum articular surface, with the lateral trochlea articular surface providing the best match. Unstable capitellar OCD lesions are not common but are, unfortunately, difficult problems to treat. In the past, if the lesion was not amenable to fixation, the only treatment options included debridement of the lesion and, in some situations, marrow stimulation techniques or lateral closing-wedge osteotomy. Bauer et al.<sup>11</sup> found a 40% recurrence rate of symptoms and loss of motion, and over 60% of their patients showed radiocapitellar degenerative changes. In their study smaller lesions appeared to fare better with fragment excision, but larger lesions did not fare well.

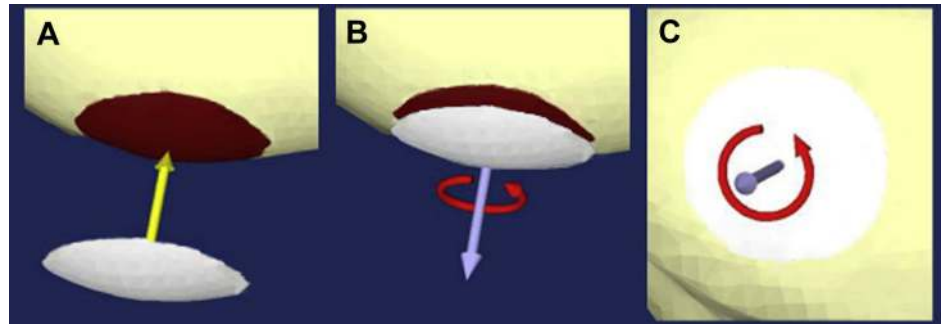
Only relatively recently have surgeons advocated the use of OATS to treat capitellar OCD. The fifth or sixth ribs and the distal femur are 2 commonly reported donor harvest sites. Technical concerns and lack of surgeon familiarity associated with operating on the chest wall may limit widespread application of this harvesting technique. In addition, this technique provides bone but not articular cartilage. In the knee the graft is typically harvested from minimal weight-bearing articular portions, such as the superolateral aspect of the lateral femoral condyle or intercondylar notch.

Several recent studies have reported overall good short- and intermediate-term results using OATS procedures from the distal femur to the capitellum, providing excellent healing and high rates of return to activity.<sup>3,12-14</sup> Moreover, donor-site morbidity has not been an issue.<sup>14,15</sup> Nishimura et al.<sup>16</sup> reported that at 3 months after OATS to treat capitellum OCD, 10 of 12



**Fig 3.** Three-dimensional model of the distance distribution of the right lateral trochlear graft superimposed on the right capitellum. The blue gradient color represents penetration into the capitellum subchondral bone surface, whereas red represents prominence. The white color indicates perfect congruence between the surfaces.

**Fig 4.** (A) The donor and recipient surfaces were superimposed, and (B, C) the capitellar surface model was rotated 360° around the axis perpendicular to the articular surface to calculate the least distance.



male patients had no pain at the knee harvest site. In a long-term study by Vogt et al.,<sup>14</sup> at 10 years' follow-up after a single autologous osteochondral graft was harvested from the ipsilateral proximal lateral femoral condyle, 4 patients (aged 15, 15, 18, and 21 years at the time of surgery), who had graft sizes ranging from 10 to 11 mm, achieved a postoperative Lysholm score of 100 in the donor knee. Nevertheless, donor-site morbidity remains a concern, and a 10-mm graft is the maximum size that we would consider for an autologous graft harvest; whenever possible, we opt for use of an allograft in larger lesions. After harvesting, donor sites may be backfilled to limit resorption of osseous wall defects and to decrease postoperative bleeding using a combination of graft from the capitellum and bone wax or allograft.<sup>3,16,17</sup>

Although results have been promising, several factors must be taken into account when planning an OATS procedure of the capitellum.<sup>18</sup> As with all OATS procedures, it is vital to have a congruous relation between the 2 articular surfaces. An ideal articular surface match for the purposes of resurfacing would be one in which there is a perfect congruous relation among all points of the 2 surfaces. Failure to produce a congruous surface can lead to altered contact pressures, edge loading of the graft, impaired integration of host and graft, and possibly early failure.<sup>19-22</sup> Other factors that affect the success of the procedure include overall surface coverage, as well as side and shape of the osteochondral plugs.<sup>23</sup> Thus, for successful osteochondral grafting, an exact anatomic restoration of the joint surface is essential.<sup>24</sup> Given the anatomic congruence between the radius and capitellum, an articular match is likely

crucial to achieve proper joint function and to minimize the risk of subsequent arthrosis. Furthermore, the capitellum is a relatively spherical structure, and this makes it difficult to place multiple plugs into a small area and obtain a stable construct. The relatively small size of the radiocapitellar joint affords limited access, which makes placing multiple plugs in the optimal orientation technically demanding. Given these technical limitations, the ability to place a single plug may offer a significant advantage.

Matching the topography of the distal femur with other joints has been studied previously to ensure that appropriate grafts can be selected, and a recent study by Schub et al.<sup>7</sup> compared cartilage depth between the capitellum and common donor sites in the distal femur for OATS procedures, without assessing the surface contour. However, histologic evidence shows that healing and integration of host and graft occur at the subchondral bone level as opposed to the cartilage level.<sup>6</sup> Thus restoring the anatomic bony contour is critical to optimize transplant integration and potentially to improve the short- and long-term results of this procedure. Similar technology has been used to evaluate the proximal medial tibia and distal lateral tibia to allow for accurate allograft harvesting for glenoid deficiencies with good success.<sup>20,25</sup> To our knowledge, there have been no similar studies conducted that have looked at the matching topography of the distal femur and capitellum to find the optimal donor site for the treatment of OCD lesions of the capitellum. Finding a location that has an ideal match to the bony and articular surface of the capitellum would greatly aid surgeons intraoperatively and, hopefully, would improve long-term results. By finding the ideal match in the knee, a single congruous plug could be obtained and then placed into the capitellum, potentially improving stability, eliminating the problem of plug crowding that is seen with mosaicplasty, and increasing the congruity of the articular surface after plug placement.

Schub et al.<sup>7</sup> found that the average cartilage depths of the knee are universally greater than those of the elbow and that the closest matches are at the posterior

**Table 1.** Demographic Data and Characteristics of Specimens

	No. of Specimens	Age, yr	Sex, n	Width, mm
Capitellum	5	61.8 ± 15.6	3 M and 2 F	16.9 ± 0.9
Medial DFC	6	21.0 ± 5.4	4 M and 2 F	24.9 ± 1.2
Lateral DFC	6	24.5 ± 6.6	5 M and 1 F	28.4 ± 2.8

NOTE. Data presented as mean ± SD unless otherwise indicated. DFC, distal femoral condyle; F, female; M, male.

**Table 2.** Descriptive Statistics of All 480 Capitellum–Distal Femur Combinations

Femoral Condyle Donor Site	Capitellum Recipient Site, mm			
	Central 30°	Central 45°	Lateral 30°	Lateral 45°
Medial notch	0.489 ± 0.035	0.506 ± 0.029	0.505 ± 0.029	0.497 ± 0.023
Lateral notch	0.486 ± 0.034	0.504 ± 0.039	0.512 ± 0.027	0.504 ± 0.022
Medial trochlea	0.467 ± 0.018	0.480 ± 0.020	0.497 ± 0.027	0.502 ± 0.024
Lateral trochlea	0.417 ± 0.021*	0.435 ± 0.020*	0.446 ± 0.020*	0.441 ± 0.018*

NOTE. Data presented as mean ± SD.

\*The lateral trochlea on the femur always yielded the best fit compared with the 3 other graft locations ( $P < .005$ ).

pole of the medial femoral condyle and distal-most anterolateral femoral condyle. The finding of their study provides further support for harvesting from the lateral trochlea region to best match the cartilage depth, as well as bony topography. Matching donor and recipient sites based on bony contour and cartilage depth may result in reduced shear stress and prolong donor plug viability, which may translate into optimal clinical results. Ahmad et al.<sup>26</sup> in 2001 used a stereophotogrammetry method to assess the topography of 5 fresh-frozen cadaveric knees. Their examination showed that the lateral trochlea and medial trochlea are convex ovoid, whereas the intercondylar notch and central trochlea are saddle shaped. This difference in curvature may account for the findings in our study because the capitellum surface also has a convex topography.

The strengths of our study include using a 3D point-cloud acquisition tool that has been proved effective.<sup>20,27,28</sup> Moreover, unlike previous topographic studies that required removal of all tissue to scan the surface, our method could be modified by leaving surrounding soft tissue intact and using a noninvasive imaging method to map the joint surfaces, which could provide practical applications in clinical settings in patients being evaluated to undergo OATS procedures.

### Limitations

One limitation of our study is that we analyzed only right elbows, which were compared with right distal femoral condyles. We assume that the results of the right side can be transferred to matching left elbows and left knees. Second, the mean age of the elbows, 61.8 years (range, 45 to 80 years), is significantly older than the age of the population usually affected by OCD. Furthermore, the elbows and femoral hemicondyles were not obtained from the same cadavers (as would be the case in autograft transfers). In addition, including more specimens in the study would allow for more generalizability. However, the availability of cadaveric specimens is limited. These limitations in terms of the possibility of sampling bias and specimen number were accounted for by comparisons of multiple combinations and permutations, 480 in total. The associations observed in this study are sufficiently strong, given that we achieved statistical significance in all observed

comparisons with our current sample size. In addition, the defect model assessed in the capitellum was limited to a single defect size of 10 mm. Smaller defects result in less topographic mismatch after restoration compared with larger defects.<sup>19</sup> Moreover, OCD lesions are generally limited to 10 mm in diameter or less, and larger defects are best treated with multiple plugs or fixation.<sup>2,29</sup> Finally, we investigated the shape of the bony surface and did not consider the cartilage thickness. A study matching cartilage shape and thickness, as well as the subchondral bone contour, will be needed in the future to optimize ideal graft fit. Other future studies may include biomechanical studies comparing contact pressures using grafts from specific donor locations. 3D finite-element analysis and experimental study of wear models with varying degrees of congruence to the native anatomy may provide critical threshold values to determine clinically acceptable matching of fit.

### Conclusions

Our results indicate that there is a less than 0.1-mm difference in the topographic articular surface match among the 4 commonly used donor sites of the distal femur and the capitellum. The findings suggest that all 4 donor sites provide close articular matching for the capitellum articular surface, with the lateral trochlea articular surface providing the best match.

### References

1. Yadao MA, Field LD, Savoie FH III. Osteochondritis dissecans of the elbow. *Instr Course Lect* 2004;53:599-606.
2. Baker CL III, Romeo AA, Baker CL Jr. Osteochondritis dissecans of the capitellum. *Am J Sports Med* 2010;38:1917-1928.
3. Iwasaki N, Kato H, Ishikawa J, Saitoh S, Minami A. Autologous osteochondral mosaicplasty for capitellar osteochondritis dissecans in teenaged patients. *Am J Sports Med* 2006;34:1233-1239.
4. Kosaka M, Nakase J, Takahashi R, et al. Outcomes and failure factors in surgical treatment for osteochondritis dissecans of the capitellum. *J Pediatr Orthop* 2013;33:719-724.
5. Shimada K, Tanaka H, Matsumoto T, et al. Cylindrical costal osteochondral autograft for reconstruction of large defects of the capitellum due to osteochondritis dissecans. *J Bone Joint Surg Am* 2012;94:992-1002.

6. Kock NB, Van Susante JL, Buma P, Van Kampen A, Verdonshot N. Press-fit stability of an osteochondral autograft: Influence of different plug length and perfect depth alignment. *Acta Orthop* 2006;77:422-428.
7. Schub DL, Frisch NC, Bachmann KR, Winalski C, Saluan PM. Mapping of cartilage depth in the knee and elbow for use in osteochondral autograft procedures. *Am J Sports Med* 2013;41:903-907.
8. Reddy S, Pedowitz DI, Parekh SG, Sennett BJ, Okereke E. The morbidity associated with osteochondral harvest from asymptomatic knees for the treatment of osteochondral lesions of the talus. *Am J Sports Med* 2007;35:80-85.
9. Iwasaki N, Kato H, Kamishima T, Suenaga N, Minami A. Donor site evaluation after autologous osteochondral mosaicplasty for cartilaginous lesions of the elbow joint. *Am J Sports Med* 2007;35:2096-2100.
10. Mihata T, Quigley R, Robicheaux G, McGarry MH, Neo M, Lee TQ. Biomechanical characteristics of osteochondral defects of the humeral capitellum. *Am J Sports Med* 2013;41:1909-1914.
11. Bauer M, Jonsson K, Josefsson PO, Linden B. Osteochondritis dissecans of the elbow. A long-term follow-up study. *Clin Orthop Relat Res* 1992;284:156-160.
12. Iwasaki N, Kato H, Ishikawa J, Masuko T, Funakoshi T, Minami A. Autologous osteochondral mosaicplasty for osteochondritis dissecans of the elbow in teenage athletes: Surgical technique. *J Bone Joint Surg Am* 2010;92:208-216 (suppl 1, pt 2).
13. Ovesen J, Olsen BS, Johannsen HV. The clinical outcomes of mosaicplasty in the treatment of osteochondritis dissecans of the distal humeral capitellum of young athletes. *J Shoulder Elbow Surg* 2011;20:813-818.
14. Vogt S, Siebenlist S, Hensler D, et al. Osteochondral transplantation in the elbow leads to good clinical and radiologic long-term results: An 8- to 14-year follow-up examination. *Am J Sports Med* 2011;39:2619-2625.
15. Ansah P, Vogt S, Uebliacker P, Martinek V, Woertler K, Imhoff AB. Osteochondral transplantation to treat osteochondral lesions in the elbow. *J Bone Joint Surg Am* 2007;89:2188-2194.
16. Nishimura A, Morita A, Fukuda A, Kato K, Sudo A. Functional recovery of the donor knee after autologous osteochondral transplantation for capitellar osteochondritis dissecans. *Am J Sports Med* 2011;39:838-842.
17. Jackson DW, Lalor PA, Aberman HM, Simon TM. Spontaneous repair of full-thickness defects of articular cartilage in a goat model. A preliminary study. *J Bone Joint Surg Am* 2001;83:53-64.
18. Nakagawa Y, Matsusue Y, Ikeda N, Asada Y, Nakamura T. Osteochondral grafting and arthroplasty for end-stage osteochondritis dissecans of the capitellum. A case report and review of the literature. *Am J Sports Med* 2001;29:650-655.
19. Bartz RL, Kamaric E, Noble PC, Lintner D, Bocell J. Topographic matching of selected donor and recipient sites for osteochondral autografting of the articular surface of the femoral condyles. *Am J Sports Med* 2001;29:207-212.
20. Gupta AK, Forsythe B, Lee AS, et al. Topographic analysis of the glenoid and proximal medial tibial articular surfaces: A search for the ideal match for glenoid resurfacing. *Am J Sports Med* 2013;41:1893-1899.
21. Koh JL, Wirsing K, Lautenschlager E, Zhang LO. The effect of graft height mismatch on contact pressure following osteochondral grafting: A biomechanical study. *Am J Sports Med* 2004;32:317-320.
22. Nakagawa Y, Suzuki T, Kuroki H, Kobayashi M, Okamoto Y, Nakamura T. The effect of surface incongruity of grafted plugs in osteochondral grafting: A report of five cases. *Knee Surg Sports Traumatol Arthrosc* 2007;15:591-596.
23. Koulalis D, Di Benedetto P, Citak M, O'Loughlin P, Pearle AD, Kendoff DO. Comparative study of navigated versus freehand osteochondral graft transplantation of the knee. *Am J Sports Med* 2009;37:803-807.
24. Nishizawa Y, Matsumoto T, Araki D, et al. Matching articular surfaces of selected donor and recipient sites for cylindrical osteochondral grafts of the femur: Quantitative evaluation using a 3-dimensional laser scanner. *Am J Sports Med* 2014;42:658-664.
25. Provencher MT, Ghodadra N, Romeo AA. Arthroscopic management of anterior instability: Pearls, pitfalls, and lessons learned. *Orthop Clin North Am* 2010;41:325-337.
26. Ahmad CS, Cohen ZA, Levine WN, Ateshian GA, Mow VC. Biomechanical and topographic considerations for autologous osteochondral grafting in the knee. *Am J Sports Med* 2001;29:201-206.
27. Duan CY, Espinoza Orias AA, Shott S, et al. In vivo measurement of the subchondral bone thickness of lumbar facet joint using magnetic resonance imaging. *Osteoarthritis Cartilage* 2011;19:96-102.
28. Watanabe S, Inoue N, Yamaguchi T, et al. Three-dimensional kinematic analysis of the cervical spine after anterior cervical decompression and fusion at an adjacent level: A preliminary report. *Eur Spine J* 2012;21:946-955.
29. Yamamoto Y, Ishibashi Y, Tsuda E, Sato H, Toh S. Osteochondral autograft transplantation for osteochondritis dissecans of the elbow in juvenile baseball players: Minimum 2-year follow-up. *Am J Sports Med* 2006;34:714-720.