

Pectoralis major transfer for treatment of irreparable subscapularis tear: a systematic review

Jason J. Shin · Maristella F. Saccomanno ·
Brian J. Cole · Anthony A. Romeo ·
Gregory P. Nicholson · Nikhil N. Verma

Received: 28 April 2014 / Accepted: 8 August 2014
© European Society of Sports Traumatology, Knee Surgery, Arthroscopy (ESSKA) 2014

Abstract

Purpose Irreparable ruptures of the subscapularis tendon lead to impaired function of the shoulder and presents a surgically complex problem. Transfer of the pectoralis major tendon has been reported as a possible treatment option. The purpose of this systematic review is to critically examine the outcomes of pectoralis major transfers for the treatment of irreparable subscapularis tears.

Methods A systematic review of the literature was performed using search of electronic databases. No language restrictions were applied. Case reports, review articles, and operative techniques without outcome data were excluded. All the outcomes reported by each study were analyzed and when possible, data were pooled to generate frequency-weighted values to summarize outcomes.

Results Eight studies with a total 195 shoulders were included in this systematic review. The mean age of patients was 58.8 years (range 18–81 years) and the mean follow-up was 33.4 months (range 6–80 months). Constant scores improved from a mean pre-operative score of 37.8 ± 6.8 , to a mean postoperative score of 61.3 ± 6.5 ($p < 0.0001$). Pain scores could not be pooled as different scales were used. Nevertheless, a trend in pain reduction was noted

in all papers. Functional outcomes were less favorable in patients with massive rotator cuff tears or previous shoulder replacements. Moreover, the Constant scores were significantly higher in patients following subcoracoid transfer of the pectoralis major tendon compared to patients who received supracoracoid transfer ($p < 0.001$). The overall reported incidence of postoperative nerve palsy is low (one transient musculocutaneous nerve palsy and one axillary nerve dysfunction out of 195 cases).

Conclusions The systematic review based on frequency-weighted means demonstrated improvement in shoulder function, strength and pain relief after pectoralis major transfer for irreparable subscapularis tear.

Level of evidence IV.

Keywords Subscapularis · Irreparable rotator cuff tear · Pectoralis major · Tendon transfer

Introduction

The biomechanical significance of the subscapularis tendon includes contributions to anterior stability, providing strength in internal rotation and maintaining a balanced force couple in the transverse plane of the glenohumeral joint [5].

Subscapularis muscle–tendon unit dysfunction can produce significant anterior shoulder pain and weakness in motion. Subscapularis tendon tears can occur from overuse or chronic attenuation secondary to age, but are more likely to result from traumatic events such as falls and/or shoulder dislocation. Satisfactory results have been reported after open or arthroscopic surgical repairs of acute tears of the subscapularis tendon [14, 26, 28]. Repair of chronic tears has not produced such positive results [14, 20, 34]. This

J. J. Shin (✉)
Department of Orthopaedics, Royal University Hospital,
University of Saskatchewan, Saskatoon, SK S7N 0W8, Canada
e-mail: jasonjwshin@gmail.com

M. F. Saccomanno
Department of Orthopaedics, Catholic University,
Largo A. Gemelli, 8, 00168 Rome, Italy

B. J. Cole · A. A. Romeo · G. P. Nicholson · N. N. Verma
Division of Sports Medicine, Department of Orthopaedic
Surgery, Rush University Medical Center, Rush Medical College
of Rush University, Chicago, IL, USA

poses a surgical challenge as subscapularis tendon tears are often missed early in the course of treatment because patients lack the classic rotator cuff symptoms [6]. Additionally, diagnosis may be delayed as preoperative magnetic resonance evaluation of subscapularis has low sensitivity [1, 2]. Such degenerative subscapularis tears are usually found in patients older than 40 years of age and may also be accompanied by supraspinatus tears [3]. If atrophy, fatty infiltration or considerable retraction is present, direct repair is especially prone to failure and the poor quality of the rotator cuff in these ruptures often does not allow for direct tendon-to-bone reconstruction [3, 16, 20].

First described in 1997 by Wirth and Rockwood [38], the transfer of the pectoralis major tendon has been described as a salvage procedure in the treatment of irreparable subscapularis tears. Subsequent reported outcomes have been few and involved small series with variable results. Theoretical advantages of pectoralis major transfer procedure have been reported. Biomechanically, pectoralis major transfer partially restores the function of the subscapularis by recreating the anterior force couple and subsequently exerts an internal rotation centering force on the glenohumeral joint. As demonstrated by Burkhart [5], the improved balance in the force coupling plane is critical in providing a balanced fulcrum and allows the deltoid to effectively contribute to shoulder elevation. Furthermore, because the function of the pectoralis and subscapularis tendons is similar, biofeedback programs and retraining are minimized in the rehabilitation process [30].

The purpose of this study was to systematically review the literature and consolidate the existing evidence on the outcomes of pectoralis major transfers for the treatment of irreparable subscapularis tears. Three specific aims were to:

1. Evaluate functional outcomes, strength, pain relief and range of motion after pectoralis major tendon transfer for irreparable subscapularis cuff tears.
2. Appraise predictive factors which lead to a successful outcome.
3. Assess the complications following this procedure.

The hypothesis was that patients would have improvement in shoulder pain and function after undergoing transfer of pectoralis major for irreparable subscapularis tears.

Materials and methods

A systematic review was conducted according to the Preferred Reporting Items for Systematic reviews and Meta-Analyses (PRISMA) guidelines without a formal protocol or registration number [29] Two authors searched the Medline and EMBASE electronic databases to identify studies

which reported outcomes following pectoralis major transfer for irreparable subscapularis tendon.

Literature search was performed on October 15, 2013, without applying language or time restriction. The primary outcome measure of this review was functional outcome based on a validated shoulder function score—the Constant score [8, 9]. Other outcome measures of this review were validated subjective and objective functional outcome scores, clinical evaluation, pain, strength, subjective shoulder value, radiological findings, and complications (including rate of infection, re-tear and revision). To prevent missing relevant studies, the following general search terms were used: irreparable subscapularis, muscle transfer shoulder, tendon transfer shoulder, and pectoralis major transfer shoulder. No filters or clinical queries were used, generating a sensitive search.

Patients of all ages who underwent pectoralis major transfer for irreparable subscapularis tears were included, while (1) case reports, (2) review articles, (3) operative technique articles without outcome data, and (4) anatomic/biomechanical studies were excluded. Only studies published in peer reviewed journals were included.

Potentially relevant studies were assessed and consensus regarding which studies to include was determined through discussion. References of the applicable studies and review articles were manually cross-referenced for completeness. No attempt was made to contact the authors of studies for raw or missing data.

Two reviewers independently extracted available data from all eligible studies using a piloted form. Information gathered included study characteristics such as level of evidence (LOE), number of patients, duration of follow-up, and patient profile including age, sex, arm dominance, and prior surgeries. Collected surgical details included technique and associated procedures. Postoperative rehabilitation protocol was also noted. Clinical outcome data including functional outcome scores, postoperative range of motion, patient satisfaction, imaging outcomes, and complications were obtained from the studies.

Study methodological quality was evaluated with the Modified Coleman Methodology Score (MCMS), [7] which has been used in previous orthopedic and shoulder publications [17, 19]. The MCMS score is a sum of fifteen components, with a scaled potential score between 0 and 100, (excellent, 85–100; good, 70–84; fair, 55–69; and poor, <55) assessing the quality of reporting.

Statistical analysis

Comparable outcome data from individual studies were pooled to generate summary outcomes reported as frequency-weighted values (weighted mean and standard deviation). Number of shoulders in individual studies were

used to determine the weight of reported outcomes and used to calculate the weighted values. A paired *t* test was used for continuous data and a Wilcoxon signed-rank test was used for categorical data. Statistical analysis was performed using GraphPad (version 5.01, GraphPad software, San Diego, California). Treatment effect was defined as significant if $p < 0.05$.

Results

Using the search strategy described previously, we obtained 726 unique articles from MEDLINE and EMBASE. A total 602 studies were excluded based on title, and additional 114 studies were excluded after reviewing the abstract. Two additional studies were excluded based on review of the full text. Eight studies were included in the review (Fig. 1): 6 studies were published in English, 1 was published in German and English and 1 in French. It was not possible to read the full text of the French study. However, taking into account, the small number of studies available on this topic, we included the results from the detailed abstract of the French study which was reported in English. No additional studies were identified from the references.

Of the eight studies included in the systematic review, one study was published as Level II [22], one as Level III [27] and six studies were published as Level IV [11–13, 18, 32, 36]. All the included studies were retrospective in nature. The studies were published between the years 2000 and 2011. Study characteristics are summarized in Table 1. Based on a scaled maximum of 100, the mean overall study quality based on MCMS was 47.6 (range 33–58). No studies were considered good or excellent, one was considered fair, and seven were considered poor.

None of the studies included a control comparison group of patients treated without tendon transfer. Irreparable rupture of the subscapularis tendon was the only inclusion criteria well defined by each study. Patients affected by massive rotator cuff tear or instability, shoulder replacements and previous surgeries were also included. Traumatic and atraumatic tears were included. Only one study reported a preoperative MRI as inclusion criteria to document the state of the subscapularis tendon [22]. Two studies divided their patients into groups and performed subgroup analysis [11, 22]. The study by Jost et al. [22] divided their patients into three groups: Group 1 included those with an isolated subscapularis tendon tear, Group 2, those with a massive tear of subscapularis and a reparable supraspinatus tear, and Group 3, those with massive tear with an irreparable supraspinatus tear; the study by Elhassan et al. [11] divided the patients into three groups: Group 1, those with an isolated irreparable tear of the subscapularis tendon after failed instability surgery, Group 2, patients with rupture of

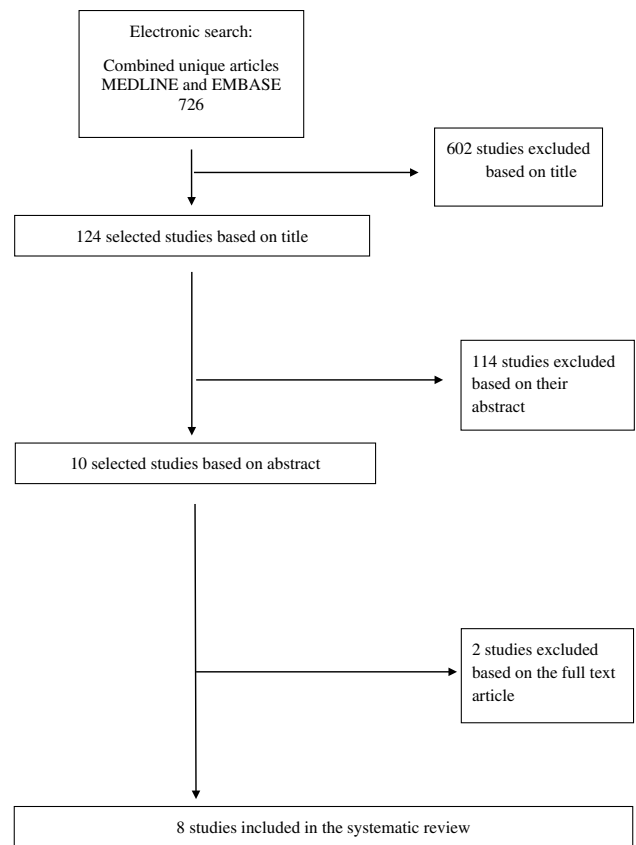


Fig. 1 Flowchart

subscapularis following shoulder replacement, and Group 3, those with rupture of subscapularis associated with a massive rotator cuff tear. None of the studies included partial tears. One study [12] included only patients that underwent one or more previous surgeries.

Main characteristics of the included studies were the following: a total of 191 patients and 195 shoulders were reported at the baseline; the dominant arm was involved in 109 cases (53.4 %); the frequency-weighted mean age of the participants was 58.8 ± 7.6 years (range 18–81); the frequency-weighted mean follow-up was 33.4 ± 11.0 months (range 6–80).

Surgical technique

Variations in surgical techniques, postoperative rehabilitation protocols, reported outcomes, and mean duration of follow-up are reported in Tables 1 and 2. Surgical technique was described in detail in each paper. Five papers [13, 18, 27, 32, 36] utilized the technique described by Resch et al. [32]. It is performed using the deltopectoral approach to expose the conjoint tendon and the tendon of the pectoralis major. The superior one-half to two-thirds of the pectoralis major tendon is detached from the humerus. The detached

Table 1 Characteristics of included studies

Study	Sample size		Male/female	Mean age (year)	Surgical technique	Postoperative rehabilitation	F/U
	Baseline	Final					
Vidil et al. [36]	5	5	NR	54	Transfer clavicular portion of PecM Attached to LT with transosseous sutures	Few days postoperative: AROM + PROM 2 months: active contractions	19
Resch et al. [32]	12	12	10/2	65	Transfer clavicular portion of PecM Passed behind conjoined tendon Attached to LT with transosseous sutures	Postop: sling and PROM (ER limited to neutral) 6 weeks: AROM 12 weeks: full loading	28
Galatz et al. [12]	14	14	11/3	67.5	Transfer entire PecM passed behind conjoined tendon Attached to GT with transosseous sutures	Postop: immobilization in abduction, 6 weeks: passive ROM (ER limited to 10°–20°) 12 weeks: active ROM	17.5
Jost et al. [22]	28 (30)	28 (30)	26/2	53	Transfer entire PecM Behind conjoined tendon Attached to GT with transosseous sutures	Postop: Immobilized in abduction 6 weeks: PROM 12 weeks: AROM and load bearing	32
Hackl et al. [8]	25	23	19/6		Transfer superior 1/2–2/3rd PecM Behind conjoined tendon Attached to LT with transosseous sutures	Postop: sling + PROM (no ER) 7 weeks: AROM 12 weeks: full load	19
ElHassan et al. [11]	30	30	18/12	37 55 58	Transfer sternal portion of PecM Passed superficial to conjoined tendon Attached to GT with transosseous sutures or bone anchors	Postop: sling 6 weeks: PROM + AROM 4 months: strengthening	49 53 57
Gavriilidis et al. [13]	15	15			Transfer clavicular part of PecM Behind conjoined tendon Attached to LT with suture anchors	Postop: sling in abduction for 3 weeks + PROM 6 weeks: AROM 12 weeks: strengthening started	37
Lederer et al. [27]	62 (64)	53 (54)	40/13	63	Transfer two-thirds of PecM Behind conjoined tendon With or without adherent bone chip Attached to LT with transosseous sutures	Postop: sling immobilization + PROM (restricted ER) 6 weeks: AROM 3 months: strengthening	35

AROM active range of motion, ER external rotation, F/U follow-up, GT greater tuberosity, IR internal rotation, LT lesser tuberosity, NR not reported, PecM Pectoralis major, PROM passive range of motion

Table 2 Postoperative subjective shoulder outcomes and complication

Study	Constant	ASES	SST	SSV	VAS for Pain	Complication
Vidil et al. [36]	27.5					
Resch et al. [32]	54.4			63	9.6 of 15	
Galatz et al. [12]		47.7			3.2 of 10	1 transient MC neuropraxia 1 re-rupture of transferred tendon
Jost et al. [22]	62			55	9 of 15	2 ruptures of transferred tendon 1 rupture of supraspinatus/infraspinatus 1 infection 1 DVT 1 mechanical conflict of coracoid process with humeral head
Hackl et al. [18]	68					
ElHassan et al. [11]	(1) 60.8 (2) 41.9 (3) 52.3				Out of 10 (1) 3.8 (2) 6.1 (3) 4.2	1 axillary nerve dysfunction 1 deep infection 13 failures
Gavriilidis et al. [13]	68.17				14.0 of 15	2 hematoma 1 cuff tear arthropathy 2 re-rupture
Lederer et al. [27]	63.4		9 of 12		4 of 10	7 re-rupture

ASES American Shoulder and Elbow Surgeons score, DVT deep vein thrombosis, MC Musculocutaneous, SST Simple shoulder test, SSV Subjective shoulder value, VAS visual analog scale

portion is then split by blunt dissection and the clavicular portion is transferred deep to the coracoid between the joint tendon and the musculocutaneous nerve. The tendon is attached to the lesser tuberosity with transosseous non-absorbable sutures. A modified version of the Resch technique [32] was used by the remaining three papers [11, 12, 22], and their description can be found in Table 1.

Post operative rehabilitation

A majority of the studies used postoperative sling immobilization for 6 weeks [11, 12, 18, 22, 32, 36]. Lederer et al. [27] utilized 4 weeks, while Gavriilidis et al. [13] reported 3 weeks in a sling with 15° of abduction with a pillow. Passive range of motion was started within 1–3 days after surgery in all but one study [11, 13, 22, 27, 32, 36]. Galatz et al. [12] utilized a prolonged immobilization therapy to allow scarring with the humeral head in a captured position under the acromion to prevent antero-superior subluxation. All studies allowed active range of motion between 6 and 8 weeks postoperatively.

Functional outcome scores

Eleven patients (5.5 %) were lost at follow-up, leaving 180 patients and 183 shoulders for the final analysis. Function was evaluated using the following scores: Constant Score, American Shoulder and Elbow Surgeons (ASES) Score [33], Simple Shoulder Test (SST) [15], subjective shoulder value (SSV) [23], and pain score (Table 2). All

but one study [12] reported Constant scores. Patients had a frequency-weighted mean Constant pre- and postoperative score of 37.8 ± 6.8 and 61.3 ± 6.5 , respectively, ($p < 0.001$). Only Galatz et al. [12] reported ASES score and reported an improvement from a mean of 27.2 (range 10–56) to 47.7 (range 10–80) post treatment. Lederer et al. [27] reported improvement in SST from mean of 6 (range 2–9) to 9 (range 2–12) ($p = 0.01$). Patient satisfaction through SSV was reported by two studies [22, 32]. The frequency-weighted mean SSV was 22.0 ± 1.4 preoperatively and 57.3 ± 3.7 postoperatively ($p < 0.0001$). Six studies [11–13, 22, 27, 32] reported significant improvement in pain, but because of variable reporting scales, we were unable to pool the data.

Clinical examination

Range of motion

Five studies [12, 13, 22, 27, 32] reported changes in range of motion. Frequency-weighted mean in forward elevation preoperatively was 102.3 ± 40.3 compared to postoperatively, 130.3 ± 25.9 ($p < 0.0001$). Abduction improved from 108.1 ± 14.4 preoperatively to 135.4 ± 14.2 postoperatively, ($p < 0.0001$). Four studies reported external rotation at the side [12, 22, 27, 32]. External rotation was reduced significantly from 55.6 ± 14.2 preoperatively to 44.7 ± 8.8 postoperatively, ($p < 0.001$). Only one study [13] reported changes in internal rotation from 76.7 ± 18.3 preoperatively to 78.0 ± 18.2 postoperatively.

Strength

Although strength evaluation is part of the Constant score, only two studies specifically reported strength [22, 27]. Lederer et al. [27] reported postoperative internal rotation strength of 6.8 kg (range 2–13 kg). Jost et al. [22] reported significant improvement between preoperative and postoperative strength in abduction, 1.8 ± 1.8 kg to 3.6 ± 2.8 , respectively ($p = 0.001$).

Special tests for subscapularis function

In five studies [13, 22, 27, 32, 36] that reported lift-off test, all 126 patients had positive test preoperatively and 56 (44.4 %) patients remained positive post surgically. Difference was not statistically significant ($p = 0.06$). Two studies [27, 36] reported pre and postoperative belly press test. Sixty-one patients had positive belly press test preoperatively compared to 30 (49.2 %) postoperatively ($p = 0.47$).

Pectoralis major transfer after shoulder arthroplasty

Although three studies [11, 12, 18, 36] reported having patients who previously had either hemi- or total shoulder arthroplasty, we were unable to pool the data and provide a subgroup analysis as only one study [11] separately reported functional outcomes in these patients. Among eight patients who previously had shoulder arthroplasty (three hemi and five total shoulder arthroplasties), Elhassan et al. [11] reported minimal improvement in mean Constant score (32.9–41.9, $p = 0.7$) and visual analog pain scale (7.8–6.1, $p = 0.7$) after pectoralis major transfer. At last follow-up, the belly press test was positive in all eight patients.

Functional outcomes: pectoralis major transfer over versus under conjoint

In five studies [12, 13, 18, 27, 32], the pectoralis major tendon was routed deep to the conjoint tendon, two studies [11, 22] reported passing the tendon superficial to the conjoint and one study [36] did not describe their specific technique. Of these seven [12, 13, 18, 22, 27, 32] studies, six [13, 18, 22, 27, 32] used Constant outcome scores and reported weighted average preoperative scores of 38.8 ± 8.4 in the subcoracoid transfer group and 38.2 ± 5.4 in the supracoracoid transfer group ($p = 0.581$). Frequency-weighted mean postoperative Constant score of 63.0 ± 4.0 in the under group was significantly higher than the over group score of 57.3 ± 7.0 ($p < 0.001$), although given the small difference, clinical significance is not likely.

Imaging outcomes

Six studies reported imaging outcomes at follow-up using X-ray, ultrasonography (U/S), computer topography (CT) scan, and magnetic resonance imaging (MRI) (Table 3) [11, 13, 22, 27, 32, 36]. Numerous imaging modalities and inconsistent reporting across studies did not allow for pooling of data or summarizing of the imaging outcomes.

Complications and subsequent surgeries

The papers reported the following major and minor complications: one permanent axillary nerve dysfunction (0.5 %), one transient musculocutaneous nerve neuropraxia (0.5 %), two deep infections (1 %) requiring surgery, twenty-five re-ruptures of transferred pectoralis major (12.8 %), one deep venous thrombosis of the axillary vein (0.5 %) treated with oral anticoagulants without sequelae, two hematomas (1 %) and one cuff tear arthropathy (0.5 %) (Table 2) [11–13, 22].

Only Elhassan et al. [11] reported the management of failed transfers. In the instability group, out of three failures, one patient underwent a revision of the fixation of the transfer and two additional patients underwent glenohumeral fusion. In the arthroplasty group, out of six total failures, one patient underwent hardware removal and antibiotic impregnated cement spacer insertion, one patient was converted to a reverse implant, one patient underwent a revision total shoulder arthroplasty, one patient underwent a revision through a teres major transfer and the last two patients did not have any further surgeries. All patients that underwent subsequent surgeries experienced considerable relief in pain, but minimal functional improvement. In the rotator cuff group, none of the patients underwent further surgery.

Discussion

The most important findings of the present systematic review were considerable pain relief, significant improvement in strength, increased forward elevation and decrease in external rotation after pectoralis major transfer. Although patients had significant clinical improvement, the final frequency-weighted mean Constant score was 61.26, highlighting the salvage aspect of this procedure and suggesting that patients and surgeons should not expect a return to normal function.

In case of irreparable subscapularis tendon tears, despite severe shoulder functional limitations, the options for reconstruction are limited and the treatment depends on the patient's age and symptoms, as well as presence of glenohumeral osteoarthritis. Goals of the muscle transfer are pain relief, partial recovery of strength and modest improvement in range of motion. In such salvage cases,

Table 3 Postoperative objective shoulder assessment and imaging studies

Study	ROM (°)			Imaging			
	FE	ABD	ER	Xray	U/S	CT	MRI
Vidil et al. [36]				Humeral head same as preoperative films			
Resch et al. [32]	129	113	30		Intact for all		Intact in 6 of 7 imaged
Galatz et al. [12]	60		28				
Jost et al. [22]	132	126	50	Humeral head centered in 25 of 30			Obtained in 29 of 30 2 ruptures of transferred tendon 1 rupture of supraspinatus/infraspinatus revealed atrophy and degeneration
Hackl et al. [18]							
ElHassan et al. [11]						(1) 3 rupture of transfer (2) 6 rupture of transfer	(3) 4 rupture of transfer 1 Goutallier stage III 3 Goutallier stage II
Gavriilidis et al. [13]	149.33	135.33					9 (70 %) intact 2 (15 %) intact but thin 2 (15 %) avulsion
Lederer et al. [27]	142.59	137.2	49.37				52 of 54 MRI 42 intact, no atrophy 4 complete rupture 3 thin insufficient scar 3 intact with (Goutallier > I)

ABD abduction, CT computed tomography, ER external rotation, FE forward elevation, MRI magnetic resonance imaging, ROM range of motion, U/S ultrasound

pectoralis major tendon transfer has been considered a reliable option that may provide pain relief and improvement in patient reported outcome scores [13, 30, 37]. It is certainly an alternative option that can give acceptable results, although based on the results of this study, patients should be provided reasonable expectations regarding improvement, but not normalization, of shoulder function.

The pectoralis major muscle originates anterior to the chest wall, with the clavicular head originating from the medial half of the clavicle, while the sternocostal head originates from the sternum, the superior six ribs and the aponeurosis of the external oblique muscle. Clavicular and sternal heads both insert onto the lateral lip of the intertubercular groove of the proximal humerus [10]. The pectoralis major muscle transfer contracts in phase with the subscapularis, thus making it an appropriate substitute. Nevertheless, the subscapularis function cannot be restored completely [25]. The anatomic position of the periscapular muscles and the resulting force vectors in relation to the positions of the native rotator cuff muscles are not equivalent and this balance in the force couple is rarely achieved. As evidenced by the variations and modifications in technique [11, 12, 22, 32, 38], the ideal method for pectoralis major transfer has not been defined. Main differences between the described

techniques include: transferring the entire tendon versus splitting the tendon; and passing the pectoralis major over or under the conjoint tendon. Certain techniques may allow for improved glenohumeral kinematics and closer mimicking of the native function of the subscapularis. Wirth and Rockwood [38] described a split by using the superior 2.5–3 cm of the pectoralis major tendon. This technique was later modified by Resch et al. [32], in which the split pectoralis tendon was routed deep to the conjoint tendon, reproducing a more subscapularis-like vector. In a cadaveric biomechanical analysis, Konrad et al. [25] demonstrated that kinematics of the glenohumeral joint was restored to values closer to those of the intact shoulder when the pectoralis major tendon was routed underneath the conjoint tendon. Compared to passing the tendon over the conjoint tendon [22], the Konrad et al. [25] theorized that the line of action is closer to that of the subscapularis when it is passed underneath. Furthermore, routing the pectoralis tendon deep to the conjoint tendon has an additional advantage of providing an anterior buttress between the coracoid process and the humeral head, as well as a dynamic transfer to restore balance to the anterior–posterior force couple [21]. Such theoretical advantages may explain the clinical results of this systematic review, where the Constant score in the subcoracoid transfer group was

significantly higher than the supracoracoid transfer group score. However, the number of transfers above the coracoid were small, and the difference is not likely clinically significant. Further study is necessary in this regard. The use of the superior as well as the inferior part of the pectoralis major transfer has been described. As suggested by Jennings et al. [21], using the superior aspect of the tendon may be less efficient in providing the inferior vector which is required to counteract the superior pull of the deltoid. In a cadaveric study, the authors reported that the length and width of the inferior tendon is sufficient to be used in transfers without undue tension and/or neural damage.

Although uncommon and possibly underreported, musculocutaneous nerve injury, is certainly one of the major complications that may be encountered secondary to compression or traction when passing a bulky tendon deep to the coracoid [12, 21]. Despite biomechanical advantages, the anatomical variability in the path of the musculocutaneous nerve poses a challenge in transferring the pectoralis major tendon underneath the conjoint tendon. In an anatomical study, Klepps et al. [24] suggested that protection of the musculocutaneous nerve can be achieved by a split pectoralis major transfer, release of the proximal musculocutaneous branches, or debulking of the pectoralis major muscle. Recently, Ruiz-Iban et al. [35], after dissecting 52 cadaveric shoulders, noted that in 31 % of cases, the transferred tendon and the musculocutaneous nerve came into contact and in another 21 % of cases, there was insufficient space between the coracoid and the branches of the musculocutaneous nerve to allow pectoralis major muscle transfer. Therefore, the authors of the study confirmed previous results and suggested identifying the nerve and its branches in order to safely pass the muscle underneath the coracoid.

In a case report by Owens et al. [31], despite utilizing the split technique by transferring 25 % of the pectoralis major tendon, postoperatively, the patient experienced symptoms of acute brachial plexus compression. This case report highlights the potential for nerve compression even with split transfer. At the end of the case, the nerve must always be palpated with the index finger and, if there is too much tension on the nerve, the diameter of the muscle belly must be reduced [32]. In the present cohort of 195 shoulders, only one patient experienced transient musculocutaneous nerve palsy [12] and one patient experienced axillary nerve dysfunction [11]. Lederer et al. [27] reported that “the risk of injury to the musculocutaneous nerve is low when the appropriate technique is used for careful blunt preparation.”

Specific preoperative factors were noted to influence overall outcome [11, 22]: associated tears and previous arthroplasty procedures. Evidence seems to suggest that pectoralis major transfer for isolated subscapularis tears results in significantly better outcome compared to transfer associated to massive rotator cuff tears. In the setting of massive rotator

cuff tears, if the supraspinatus tendon could be repaired in combination with pectoralis major transfer, the results are significantly better than in irreparable supraspinatus tendon [22]. Moreover, in patients with centered glenohumeral joint and isolated subscapularis insufficiency, improvement in pain and function can be expected with pectoralis major transfer. The transfer is more likely to fail, if preoperatively the shoulder is subluxed or there is advanced fatty infiltration of the supraspinatus and infraspinatus [11]. Rupture of the subscapularis tendon is an encountered complication of shoulder replacement [4] and may result in pain, weakness, and instability. Three of the selected studies included arthroplasty patients, and the results of pectoralis major transfer were poorer with high rate of complication in this group [11, 12, 36]. In older patients with massive cuff insufficiency and concomitant glenohumeral joint arthritis or subscapularis insufficiency after total shoulder replacement, reverse total shoulder arthroplasty is certainly the most appropriate option to manage. However, in active younger patients, pectoralis major transfer may be a viable option to delay a reverse shoulder arthroplasty.

The present systematic review has several limitations. Most of the limitations were secondary to the low methodological quality of the studies. All studies were retrospective and did not provide control groups nor compared pectoralis major transfer with other treatments. Secondly, taking into account that indications for transfer procedure are limited and patients who would benefit are not commonly encountered, the studies were underpowered. Thirdly, patients in the studies were non-homogenous with respect to age and sex across the studies. There was variability in the inclusion and exclusion criteria between studies. Fourthly, most of the studies included patients who had one or more previous surgeries or concomitant procedures with the transfer. The impact of such variables on the outcomes of pectoralis major transfer is unclear. Limitations specific to the systematic review are that only electronic databases were used and no attempt was made to contact the trialist for missing raw data. More studies are needed in order to clarify which option can better restore anatomy and biomechanics of subscapularis tendon while minimizing the risk of neurovascular injuries. Future studies should provide results with longer follow-up and include postoperative MRI studies to assess the integrity of the tendon transfer.

Conclusion

Although the present systematic review combined mostly observational studies, it provides an overview of the current literature. Frequency-weighted means of available data demonstrated improvement in shoulder function, strength and pain relief after pectoralis major tendon transfer for

irreparable subscapularis tears. Despite theoretical risks, musculocutaneous nerve injury is rare and subcoracoid pectoralis major transfer result in better clinical outcomes.

Conflict of interest Authors declare that they have no relevant conflict of interest in connection with the submitted article.

References

- Adams CR, Brady PC, Koo SS, Narbona P, Arrigoni P, Karnes GJ, Burkhart SS (2012) A systematic approach for diagnosing subscapularis tendon tears with preoperative magnetic resonance imaging scans. *Arthroscopy* 28:1592–1600
- Adams CR, Schoolfield JD, Burkhart SS (2010) Accuracy of preoperative magnetic resonance imaging in predicting a subscapularis tendon tear based on arthroscopy. *Arthroscopy* 26:1427–1433
- Bartl C, Salzmann GM, Seppel G, Eichhorn S, Holzapfel K, Wortler K, Imhoff AB (2011) Subscapularis function and structural integrity after arthroscopic repair of isolated subscapularis tears. *Am J Sports Med* 39:1255–1262
- Boileau P, Sinnerton RJ, Chuinard C, Walch G (2006) Arthroplasty of the shoulder. *J Bone Joint Surg Br* 88:562–575
- Burkhart SS (1991) Arthroscopic treatment of massive rotator cuff tears. Clinical results and biomechanical rationale. *Clin Orthop Relat Res* 267:45–56
- Cofield RH, Parvizi J, Hoffmeyer PJ, Lanzer WL, Ilstrup DM, Rowland CM (2001) Surgical repair of chronic rotator cuff tears. A prospective long-term study. *J Bone Joint Surg Am* 83-A:71–77
- Coleman BD, Khan KM, Maffulli N, Cook JL, Wark JD (2000) Studies of surgical outcome after patellar tendinopathy: clinical significance of methodological deficiencies and guidelines for future studies. *Victorian Institute of Sport Tendon Study Group. Scand J Med Sci Sports* 10:2–11
- Constant CR, Gerber C, Emery RJ, Sojbjerg JO, Gohlke F, Boileau P (2008) A review of the Constant score: modifications and guidelines for its use. *J Shoulder Elbow Surg* 17:355–361
- Constant CR, Murley AH (1987) A clinical method of functional assessment of the shoulder. *Clin Orthop Relat Res* 214:160–164
- Elhassan B, Christensen TJ, Wagner ER (2014) Feasibility of latissimus and teres major transfer to reconstruct irreparable subscapularis tendon tear: an anatomic study. *J Shoulder Elbow Surg* 23:492–499
- Elhassan B, Ozbaydar M, Massimini D, Diller D, Higgins L, Warner JJ (2008) Transfer of pectoralis major for the treatment of irreparable tears of subscapularis: does it work? *J Bone Joint Surg Br* 90:1059–1065
- Galatz LM, Connor PM, Calfee RP, Hsu JC, Yamaguchi K (2003) Pectoralis major transfer for anterior-superior subluxation in massive rotator cuff insufficiency. *J Shoulder Elbow Surg* 12:1–5
- Gavriilidis I, Kircher J, Magosch P, Lichtenberg S, Habermeyer P (2010) Pectoralis major transfer for the treatment of irreparable anterosuperior rotator cuff tears. *Int Orthop* 34:689–694
- Gerber C, Hersche O, Farron A (1996) Isolated rupture of the subscapularis tendon. *J Bone Joint Surg Am* 78:1015–1023
- Godfrey J, Hamman R, Lowenstein S, Briggs K, Kocher M (2007) Reliability, validity, and responsiveness of the simple shoulder test: psychometric properties by age and injury type. *J Shoulder Elbow Surg* 16:260–267
- Goutallier D, De Abreu L, Postel JM, Le Guilloux P, Radier C, Zilber S (2011) Is the trapezius transfer a useful treatment option for irreparable tears of the subscapularis? *Orthop Traumatol Surg Res* 97:719–725
- Griesser MJ, Harris JD, Campbell JE, Jones GL (2011) Adhesive capsulitis of the shoulder: a systematic review of the effectiveness of intra-articular corticosteroid injections. *J Bone Joint Surg Am* 93:1727–1733
- Hackl W, Wambacher M, Kralinger F, Smekal V (2007) Pectoralis major transfer in the treatment of chronic subscapularis insufficiency. *Oper Orthop Traumatol* 19:433–441
- Harris JD, Siston RA, Pan X, Flanagan DC (2010) Autologous chondrocyte implantation: a systematic review. *J Bone Joint Surg Am* 92:2220–2233
- Ide J, Tokiyoshi A, Hirose J, Mizuta H (2007) Arthroscopic repair of traumatic combined rotator cuff tears involving the subscapularis tendon. *J Bone Joint Surg Am* 89:2378–2388
- Jennings GJ, Keereweer S, Buijze GA, De Beer J, DuToit D (2007) Transfer of segmentally split pectoralis major for the treatment of irreparable rupture of the subscapularis tendon. *J Shoulder Elbow Surg* 16:837–842
- Jost B, Puskas GJ, Lustenberger A, Gerber C (2003) Outcome of pectoralis major transfer for the treatment of irreparable subscapularis tears. *J Bone Joint Surg Am* 85-A:1944–1951
- Jost B, Pfirrmann CW, Gerber C, Switzerland Z (2000) Clinical outcome after structural failure of rotator cuff repairs. *J Bone Joint Surg Am* 82:304–314
- Klepps SJ, Goldfarb C, Flatow E, Galatz LM, Yamaguchi K (2001) Anatomic evaluation of the subcoracoid pectoralis major transfer in human cadavers. *J Shoulder Elbow Surg* 10:453–459
- Konrad GG, Sudkamp NP, Kreuz PC, Jolly JT, McMahon PJ, Debski RE (2007) Pectoralis major tendon transfers above or underneath the conjoint tendon in subscapularis-deficient shoulders. An in vitro biomechanical analysis. *J Bone Joint Surg Am* 89:2477–2484
- Lanz U, Fullick R, Bongiorno V, Saintmard B, Campens C, Lafosse L (2013) Arthroscopic repair of large subscapularis tendon tears: 2- to 4-year clinical and radiographic outcomes. *Arthroscopy* 29:1471–1478
- Lederer S, Auffarth A, Bogner R, Tauber M, Mayer M, Karpik S, Matis N, Resch H (2011) Magnetic resonance imaging-controlled results of the pectoralis major tendon transfer for irreparable anterosuperior rotator cuff tears performed with standard and modified fixation techniques. *J Shoulder Elbow Surg* 20:1155–1162
- Mall NA, Chahal J, Heard WM, Bach BR Jr, Bush-Joseph CA, Romeo AA, Verma NN (2012) Outcomes of arthroscopic and open surgical repair of isolated subscapularis tendon tears. *Arthroscopy* 28:1306–1314
- Moher D, Liberati A, Tetzlaff J, Altman DG, PRISMA Group (2010) Preferred reporting items for systematic reviews and meta-analyses: the PRISMA statement. *Int J Surg* 8:336–341
- Omid R, Lee B (2013) Tendon transfers for irreparable rotator cuff tears. *J Am Acad Orthop Surg* 21:492–501
- Owens BD, Nelson BJ, Taylor DC (2008) Acute brachial plexus compression after pectoralis major transfer for subscapularis insufficiency. *Am J Sports Med* 36:173–175
- Resch H, Povacz P, Ritter E, Matschi W (2000) Transfer of the pectoralis major muscle for the treatment of irreparable rupture of the subscapularis tendon. *J Bone Joint Surg Am* 82:372–382
- Richards RR, An KN, Bigliani LU, Friedman RJ, Gartsmann GM, Gristina AG, Iannotti JP, Mow VC, Sidles JA, Zuckerman JD (1994) A standardized method for the assessment of shoulder function. *J Shoulder Elbow Surg* 3:347–352
- Robertson CM, Chen CT, Shindle MK, Cordasco FA, Rodeo SA, Warren RF (2012) Failed healing of rotator cuff repair correlates with altered collagenase and gelatinase in supraspinatus and subscapularis tendons. *Am J Sports Med* 40:1993–2001
- Ruiz-Iban MA, Murillo-Gonzalez JA, Diaz-Heredia J, Avila-Lafuente JL, Cuellar R (2013) Pectoralis major transfer for

- subscapular deficiency: anatomical study of the relationship between the transferred muscle and the musculocutaneous nerve. *Knee Surg Sports Traumatol Arthrosc* 21:2177–2183
36. Vidil A, Augereau B (2000) Transfer of the clavicular portion of the pectoralis major muscle in the treatment of irreparable tears of the subscapularis muscle. *Rev Chir Orthop Reparatrice Appar Mot* 86:835–843
37. Warner JJ (2001) Management of massive irreparable rotator cuff tears: the role of tendon transfer. *Instr Course Lect* 50:63–71
38. Wirth MA, Rockwood CA Jr (1997) Operative treatment of irreparable rupture of the subscapularis. *J Bone Joint Surg Am* 79:722–731