



## Clinical outcomes of hemiarthroplasty and biological resurfacing in patients aged younger than 50 years

LCDR James Hammond, DO<sup>a</sup>, Emery C. Lin, MD<sup>b</sup>, Daniel P. Harwood, MA<sup>b</sup>,  
Tristan W. Juhan, MA<sup>b</sup>, Eric Gochanour, MA<sup>b</sup>, Emma L. Klosterman, MA<sup>b</sup>,  
Brian J. Cole, MD, MBA<sup>b</sup>, Gregory P. Nicholson, MD<sup>b</sup>, Nikhil N. Verma, MD<sup>b</sup>,  
Anthony A. Romeo, MD<sup>b,\*</sup>

<sup>a</sup>Division of Sports Medicine, Department of Orthopaedics, Naval Medical Center Portsmouth, Portsmouth, VA, USA

<sup>b</sup>Division of Sports Medicine, Department of Orthopedic Surgery, Rush University Medical Center, Chicago, IL, USA

**Background:** Total shoulder arthroplasty as a treatment for glenohumeral degenerative joint disease is well accepted but has been less predictable with regard to outcomes and durability in a younger aged population, typically aged younger than 50 years. This younger population has a greater potential for glenoid component loosening. This has led surgeons to perform hemiarthroplasty or hemiarthroplasty with biological resurfacing of the glenoid in an effort to avoid the potential problems with a polyethylene glenoid and obtain durable and acceptable results for these patients.

**Methods:** The study included 44 patients, with 23 undergoing hemiarthroplasty alone and 21 undergoing hemiarthroplasty with biological resurfacing of the glenoid. All patients were aged younger than 50 years. Preoperative diagnoses, comorbidities, demographics, and range of motion were collected. Preoperative and postoperative radiographs were obtained. Preoperative and postoperative objective scoring measures (Single Assessment Numeric Evaluation, American Shoulder and Elbow Surgeons score, visual analog scale, Simple Shoulder Test, Constant-Murley) were used.

**Results:** Mean follow-up was 3.8 years for the hemiarthroplasty group and 3.6 years for the biological resurfacing group. Six patients in the hemiarthroplasty and 12 patients in the biological resurfacing group were considered failures due to revision surgery or an American Shoulder and Elbow Surgeons score <50. The hemiarthroplasty group had significantly better visual analog scale and Single Assessment Numeric Evaluation scores.

**Conclusions:** There was a significant failure rate in the hemiarthroplasty and the biologic resurfacing groups compared with results in the literature. Improved outcomes and lower failure rates were observed in the hemiarthroplasty group compared with the biological resurfacing group in this study.

**Level of evidence:** Level III, Retrospective Cohort, Treatment Study.

© 2013 Journal of Shoulder and Elbow Surgery Board of Trustees.

**Keywords:** Hemiarthroplasty; biological resurfacing; glenohumeral arthritis; lateral meniscal allograft

Expedited Institutional Review Board approval was granted by the Rush University Research and Clinical Trials Administration Office (ORA #08091503).

\*Reprint requests: Anthony A. Romeo, MD, 1611 W Harrison St, Ste 300, Chicago, IL 60612, USA.

E-mail address: [shoulderelbowdoc@gmail.com](mailto:shoulderelbowdoc@gmail.com) (A.A. Romeo).

The primary indication for shoulder arthroplasty is painful glenohumeral arthritis in patients aged older than 60 years who have failed conservative measures. It has been well established in the literature that patients younger than 50 years tend to have worse outcomes with shoulder

arthroplasty.<sup>11,15</sup> In young, active patients, the documented incidence of glenoid loosening is about 39% in midterm to long-term follow-up.<sup>1</sup> In an attempt to provide pain relief and avoid a glenoid component, shoulder hemiarthroplasty (HA) alone, without a glenoid component, is an option in young, active patients who participate in sports and heavy labor.<sup>5</sup> However, progressive glenoid erosion and pain have been found to be a primary mode of failure for young patients with shoulder HA. To this end, biological resurfacing (BR) of the glenoid with Achilles tendon allograft, lateral meniscal allograft, autogenous fascia lata, or extracellular matrix products have been used as an interposition arthroplasty on the glenoid side in conjunction with humeral HA. This was used to provide a “wetable” surface on the glenoid side and avoid metal-on-bone contact and glenoid erosion and pain.<sup>2,4,6,7,14,16</sup> Creighton et al<sup>3</sup> noted significant decreases in force at the glenoid surface under stress testing of a lateral meniscal allograft in a cadaveric model, which supports the rationale for BR.

The purpose of this study was to evaluate retrospectively 2 cohorts of patients: the first group received a HA alone, and the second received a HA with BR by the senior authors (B.J.C., G.P.N., N.N.V., and A.A.R.) at a large, high-volume shoulder surgical practice. The working hypothesis was that the BR group would have improved clinical results, less glenoid wear in early to midterm follow-up, and fewer conversions to total shoulder arthroplasty (TSA).

## Methods

Records of all patients who had undergone HA between June 2002 and June 2010 were retrospectively reviewed. We identified 23 consecutive patients (25 shoulders) who met the study criteria for HA alone and 21 consecutive patients who had undergone HA with BR of the glenoid.

Inclusion criteria were (1) age younger than 50 years at the initial HA or HA with BR, (2) arthritis from any cause, and (3) no history of infection or current infection at the time of the initial office visit. Clinical failure criteria were defined as a need for revision surgery or an American Shoulder and Elbow Surgeons (ASES) score under 50.

### Patient demographics

The 20 shoulders available for follow-up in the HA group were a mean age of  $33.9 \pm 9.4$  years (range, 16.8-49.6 years). The average follow up was  $3.8 \pm 1.9$  years (range, 1.0-7.4 years). Demographic information for the cohort is in Table I. Ten patients had no prior surgery, and 10 were noted to have had at least 1 prior surgery. These operations included arthroscopic debridement (n = 7), stabilization (n = 10), superior labrum anterior posterior repair (n = 2), resection for chondroblastoma (n = 1), and bony glenoid reconstruction (n = 1). Primary indications for surgery were avascular necrosis (AVN; n = 7), post-traumatic degenerative joint disease (DJD; n = 5), postsurgical DJD (n = 2), primary osteoarthritis (OA; n = 1), chondroblastoma (n = 1), glenoid dysplasia (n = 1), and rheumatoid arthritis (RA; n = 2). All patients with AVN had Cruess stage III or less.

**Table I** Patient demographics

Variable	Hemiarthroplasty (n = 20)	Biological resurfacing (n = 20)
Age, mean $\pm$ SD, y	33.9 $\pm$ 9.4	37.7 $\pm$ 8.9
Male, %	50	59
Dominant arm injury, %	40	50
Job injury, %	10	4
Diabetes, %	0	0
Tobacco history, %	0	13
Legal claim, %	10	4
Prior surgery, %	50	59

SD, standard deviation.

The 20 shoulders available for follow-up in the BR group were a mean age of  $37.7 \pm 8.9$  years (range, 19.0-53.7 years). The average follow-up was  $3.6 \pm 1.2$  years (range, 2.0-5.9 years). Demographic information for the cohort is in Table I. Eight patients had undergone no prior surgery, with 12 patients noted to have had at least 1 prior surgery, which included stabilization for recurrent instability (n = 15), arthroscopic debridement (n = 5), loose body removal (n = 2) and thermal capsulorrhaphy (n = 1). Primary indications for surgery were postcapsulorrhaphy DJD (n = 10), OA (n = 6), and AVN (n = 1). The patient with AVN had Cruess stage II.

Patients meeting the study criteria were contacted to participate in the study. Operative reports and clinic notes were reviewed to identify factors of interest, including type of arthritis, previous procedures, mechanism of injury, diagnosis at the time of surgery, and concomitant procedures. Preoperative range of motion (ROM), demographic information (age, sex, hand dominance, side of shoulder surgery), occupation, history of diabetes, and tobacco use were recorded.

At follow-up, a shoulder examination was performed by a trained, independent observer assessing active and passive ROM and strength on the operative and nonoperative side. ROM was assessed with a goniometer. Strength of forward flexion and external rotation was quantified with a manual muscle dynamometer (PowerTrack II, JTech Medical, Salt Lake City, UT, USA). Forward flexion strength was measured with the arm in the scapular plane with the patient standing. External rotation strength was measured with the arm at the side and the elbow in 90° of flexion. The maximum value from 3 trials was recorded. This value was divided by the power obtained from the contralateral arm to obtain a normalized value. The maximum normalized value allowed was 1.

Each patient was also given a postoperative questionnaire including 4 standardized assessment tools: Single Assessment Numeric Evaluation (SANE), pain score on a visual analogue scale (VAS), Simple Shoulder Test (SST), and American Shoulder and Elbow Surgeons (ASES) score. A normalized Constant-Murley score was computed by calculating each patient's score by age-matched and sex-matched normal Constant-Murley scores reported in the literature.<sup>11</sup>

Preoperative and postoperative true anteroposterior (Grashey views) and axillary shoulder radiographs were reviewed by an independent observer. Measurements were recorded to assess maintenance of joint space or degree of glenoid erosion by observing the distance from the center of the humeral head to the

center of the glenoid articular surface on a nontemplating anteroposterior Grashey view using digital measuring software.

All objective scoring data, ROM scores, and strength scores were compared statistically by using paired tests.  $P < .05$  was considered statistically significant.

### Operative technique

All procedures were performed in the beach chair position through a deltopectoral approach. The subscapularis was incised through the tendon, retaining a lateral stump for transosseous suture and tendon-to-tendon suture reattachment. No lesser tuberosity osteotomies were performed.

The humeral head was then delivered and cut with an oscillating saw along the anatomic neck after osteophyte excision. The diameter of the humeral head was measured. The humeral canal was prepared and trialed to determine appropriate size and version. The appropriate humeral component was then implanted and subscapularis closure performed.

In patients undergoing BR of the glenoid, attention was then turned to exposure of the glenoid. Appropriate releases were performed, and retractors were placed to expose the glenoid sufficiently to allow reaming. The glenoid was reamed with standard glenoid reamers to remove the remaining articular cartilage and create a bleeding bony bed while retaining subchondral bone. Attempts were made to maintain as much labrum as possible to serve as an attachment point for the biological replacement. The graft was then trialed to ensure the most appropriate fit and sutured into place circumferentially using permanent suture. The labrum was used as the attachment point, and if insufficient labrum remained, the sutures were placed transosseously through the glenoid rim (Fig. 1). No suture anchors were used.

The final stem was then inserted with the method preferred by each surgeon for that particular patient via a cemented or uncemented technique. For those who received a humeral head resurfacing, this portion of the procedure was completed according to the technique used for that particular system. The shoulder was reduced, and the construct was assessed for stability and tension. The wound was irrigated and a layered closure was performed.

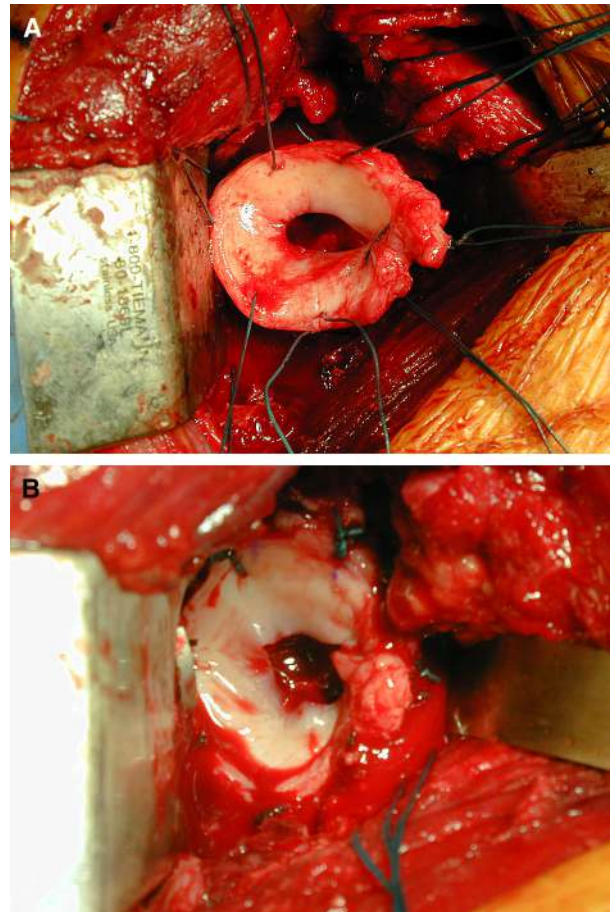
No reaming on the glenoid surface was performed in those undergoing HA alone. In addition, all HA patients received a stemmed humeral implant. Resurfacing heads were only used in 5 patients in the BR group.

All patients were immobilized with a sling device. Patients in the HA group were allowed use of the hand, wrist, and elbow in the sling. Pendulums were begun on the first postoperative day. Passive and active assisted ROM was begun by 1 week and continued for 4 weeks. After 6 weeks, active mobilization was allowed with gradual progression to strengthening and isometric exercises. Resistive exercises were instituted at 6 to 8 weeks.

Patients in the BR group were allowed to use the hand, wrist, and elbow in the sling and allowed pendulum exercises. However, because of the biological interposition, formal passive and active assisted ROM was typically delayed until 3 to 4 weeks postprocedure.

### Results

Twenty-three consecutive patients (25 shoulders) were identified who met the study criteria for the HA group, of



**Figure 1** (A) Intraoperative photograph of the lateral meniscal allograft with preplaced sutures outside the wound. (B) Lateral meniscal allograft resurfacing the glenoid.

whom 15 were seen in the clinic, 5 were available only for questionnaire and telephone follow-up, and 5 were lost to follow-up. Twenty-one consecutive patients (21 shoulders) were identified who met the study criteria for the BR group, of whom 17 were seen in clinic, 3 were available only for questionnaire and telephone follow-up, and 1 was lost to follow-up.

Human acellular dermal tissue matrix (HADTM) was used in 8 of the BR patients, and a lateral meniscal allograft was used for the glenoid surface in 12. In addition, all patients in the HA group received stemmed humeral components, whereas 15 of 20 patients in the BR group received stemmed humeral components.

### Clinical outcomes

Preoperative data for the BR and HA patients were recorded. Limited SST, VAS, and ASES scores were obtained in the BR group and were not useful for comparison. In the BR group, the mean preoperative forward flexion was  $119^\circ \pm 37^\circ$ , mean internal rotation in abduction was  $32^\circ \pm 20^\circ$ , mean external rotation in abduction was  $28^\circ \pm 21^\circ$ , and mean abduction was  $92^\circ \pm 58^\circ$ . In the HA group, the mean

**Table II** Results of hemiarthroplasty and biological resurfacing groups

Variable	Hemiarthroplasty	Biological resurfacing	P	Power
	Mean $\pm$ SD (range)	Mean $\pm$ SD (range)		
Visual analog scale*	1.8 $\pm$ 3.8 (0-8)	4.8 $\pm$ 2.2 (1-9)	.002	0.71
ASES	67.0 $\pm$ 21.7 (23-100)	59.5 $\pm$ 22.1 (30-88.3)	.15	0.15
Simple Shoulder Test	7.5 $\pm$ 3.9 (0-12)	6.9 $\pm$ 3.6 (2-12)	.60	0.07
SANE*	77.5 $\pm$ 22.9 (30-100)	54.5 $\pm$ 21.7 (15-85)	.024	0.75
Constant-Murley	67.9 $\pm$ 20.5 (30.8-101.8)	53 $\pm$ 18.1 (21.5-78.2)	.079	0.42
Range of motion				
Forward flexion, $^{\circ}$	130 $\pm$ 38 (70-180)	123 $\pm$ 32 (63-170)	.56	0.088
IR (abduction), $^{\circ}$	46 $\pm$ 20 (20-90)	38 $\pm$ 28 (0-75)	.97	0.12
ER (abduction), $^{\circ}$	71 $\pm$ 21 (39-108)	51 $\pm$ 33 (0-90)	.66	0.37
ER (side), $^{\circ}$	48 $\pm$ 15 (20-75)	52 $\pm$ 29 (0-95)	.074	0.069

ASES, American Shoulder and Elbow Surgeons; ER, external rotation; IR, internal rotation; SANE, Single Assessment Numeric Evaluation; SD, standard deviation.

\* Denotes statistical significance  $P < .05$ .

preoperative forward flexion was  $116^{\circ} \pm 36^{\circ}$ , mean internal rotation in abduction was  $35^{\circ} \pm 17^{\circ}$ , mean external rotation in abduction was  $33^{\circ} \pm 22^{\circ}$ , and mean abduction was  $128^{\circ} \pm 33^{\circ}$ . There was no statistical significance between groups. Comparison of preoperative and postoperative ROM within the BR and HA groups revealed no significant differences.

Preoperative objective scoring measures were available in the HA group. The preoperative SST was  $3.9 \pm 3.6$ , VAS was  $5.1 \pm 1.4$ , and ASES was  $26.7 \pm 11.2$ . The SANE and Constant-Murley scores were not available preoperatively. Statistical significance was obtained when comparing preoperative and postoperative objective scoring measures for SST ( $P < .03$ ), VAS ( $P < .0003$ ), and ASES ( $P < .000000008$ ).

Table II summarizes the postoperative clinical outcomes. Compared with the BR patients, the HA patients had significantly better VAS ( $1.8 \pm 2.5$  vs  $4.8 \pm 2.2$ ) and SANE ( $77.5 \pm 22.9$  vs  $54.5 \pm 21.8$ ) scores ( $P < .05$ ). There were no significant differences between groups for postoperative SST, ASES, Constant-Murley score, or ROM (forward flexion, external rotation, or internal rotation). In the HA population, 6 patients (30%) were considered clinical failures. Three patients had undergone a revision procedure to TSA at a mean of  $3.9 \pm 2.0$  years (range, 1.8-5.6 years) from the index surgery, and 3 others had ASES scores under 50.

In the BR population, 12 patients (60%) were considered clinical failures. Six patients had undergone a revision procedure (4 TSAs, 1 reverse TSA, 1 graft removal) at a mean of  $2 \pm 1.8$  years (range, 0.2-4.5 years) from the index surgery, and 6 others had ASES scores under 50.

### Radiographic outcomes

A total of 12 HA shoulders were available for radiographic follow-up at a mean of  $2.4 \pm 1.5$  years (range,

0.8-5.3 years). Three patients showed mild glenoid erosion ( $<5$  mm; Fig. 2), 3 showed moderate glenoid erosion (5-10 mm), and 1 showed severe glenoid erosion ( $>10$  mm).

A total of 14 BR shoulders were available for radiographic follow-up at a mean of  $2.9 \pm 1.2$  years (minimum, 1.1-5.2 years). At follow-up, 6 patients (40%) had  $<1$  mm of joint space, 5 (33%) had 1 to 3 mm of joint space (Fig. 3), and 2 (13.3%) had  $>3$  mm of joint space remaining. No notable changes were noted in humeral component loosening or alignment.

### Patients requiring revision

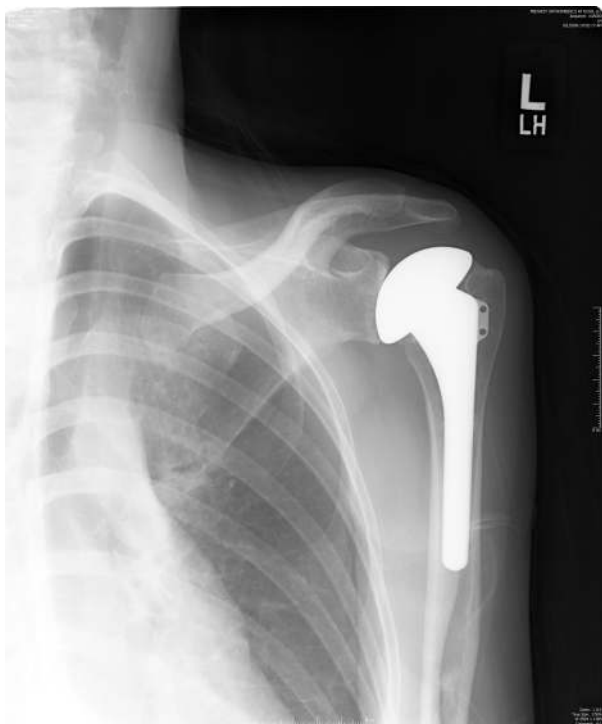Three HA patients had complications that required revision to TSA. Patient 1 was a 21-year-old former competitive swimmer and softball player who had persistent chronic pain and instability despite multiple procedures and elected to undergo a humeral head resurfacing. Initial pain relief and improved function was noted, but then the patient presented with a gradual increase in pain with loss of function concurrent with radiographic glenoid erosion. A revision to TSA was performed 5.5 years after the initial humeral resurfacing.

Patient 2 had multiple stabilization procedures, including bony glenoid reconstruction and subsequently developed OA. The patient elected to undergo a HA, but had persistent instability and pain that ultimately required conversion to a TSA. At last follow-up, the instability had clinically resolved.

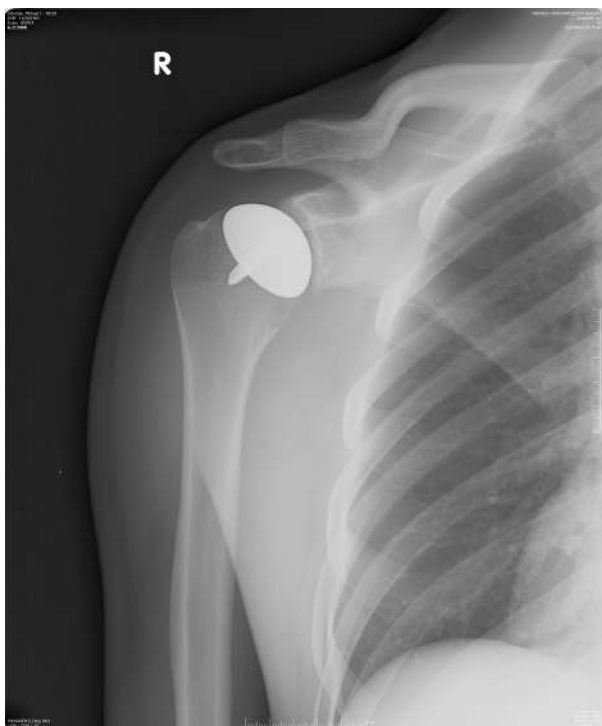Patient 3 had a medical history significant for fibromyalgia and RA with degenerative changes and underwent a HA. The pain persisted postoperatively despite conservative management, and revision to a TSA was performed 1.8 years after the index procedure.

In the BR group, 6 patients had undergone a revision procedure. Patient 1 was a 46-year-old construction worker who presented with degenerative arthritis with pain and loss





**Figure 2** Anteroposterior radiograph of a patient after hemiarthroplasty.



**Figure 3** Anteroposterior radiograph of a patient after biological resurfacing with humeral head resurfacing.

of function. The patient opted to undergo a HA with meniscal allograft. Because of persistent pain and lack of improvement, an arthroscopic debridement procedure was

performed, which did not alleviate symptoms. A revision to a TSA was performed 11 months after the meniscal allograft.

Patient 2 was a 26-year-old female football player who presented with pain and persistent stiffness with evidence of degenerative changes after multiple surgeries. HA with meniscal allograft was performed, and 6 months post-procedure, the pain had improved but the stiffness had not. At this point, an arthroscopic capsular release and intra-articular debridement was performed. No conversion to a TSA was required at the latest follow-up.

Patient 3 presented with pain and loss of function with degenerative changes after a work-related injury and 2 prior surgeries. HA with HADTM was performed. The pain and loss of function persisted postoperatively, which led to a total shoulder replacement 7 months after the index procedure.

Patient 4 was an 18-year-old with a history of instability events and previous surgeries with degenerative changes on imaging. A humeral head resurfacing with lateral meniscal allograft was performed. She did well for 6 months, and then developed stiffness and pain in the shoulder. It did not respond to conservative measures, and an arthroscopic capsular release was performed 1 year after the index procedure. Slow, progressive loss of motion and pain continued without resolution, and 3.5 years after the allograft, a revision to a total shoulder was performed.

Patient 5 initially underwent HA with lateral meniscal allograft due to arthritis. Three months postoperatively, the allograft meniscus had to be removed due to infection. The patient subsequently did well without further intervention.

Patient 6 was a 44-year-old man who presented with severe shoulder pain and a history of 2 shoulder injuries. HA with HADTM resurfacing was performed. Postoperatively, the patient experienced persistent pain that was felt to be glenoid-related, and revision to a TSA was performed 1 year later.

## Discussion

The management of young active patients with glenohumeral arthritis is challenging and remains controversial. Total shoulder arthroplasty and, in some cases, reverse shoulder arthroplasty have become predictable answers for improving pain and function in the appropriately indicated older patient.<sup>5,12</sup> In a recent meta-analysis comparing TSA with humeral head replacement for treatment of primary glenohumeral OA, Radnay et al<sup>12</sup> found TSA resulted in significantly better pain relief, postoperative ROM, and patient satisfaction, with a lower revision rate.<sup>12</sup> However, given the issues of the longevity of TSA, primarily due to previously documented issues with glenoid loosening, alternative solutions have been sought for the higher demand, younger patient with glenohumeral arthritis. The goal would be to provide symptom relief, restore shoulder function, and provide durability without compromising a future TSA.

HA emerged in an attempt to bypass the glenoid component. However, HA causes wear on the native glenoid, which leads to decreased clinical and functional results, as demonstrated by Levine et al.<sup>8</sup> As reported by Rispoli et al,<sup>13</sup> glenoid arthrosis after HA also can lead to increased pain that ultimately is the primary reason for conversion to TSA. Parsons et al<sup>10</sup> also evaluated glenoid arthrosis and found that patients with joint space <1 mm had a significantly lower Constant-Murley score than those with joint space >1 mm. In our HA group, there were 3 failures, of which only 1 was due to significant painful glenoid arthrosis, another was caused by instability, and the last was due to persistent pain without erosion, likely due to concomitant fibromyalgia and RA.

BR of the glenoid has been used to provide an interposition arthroplasty on the glenoid side to address the glenoid wear seen in HA alone. Several resurfacing options have been used, including lateral meniscal allograft, joint capsule, graft jacket, autogenous fascia lata, and Achilles allograft. Krishnan et al<sup>6</sup> reported their results using anterior capsule, autogenous fascia lata, and Achilles tendon allograft. They noted 50% excellent results overall, with poorer results in patients in whom anterior capsule was used.<sup>6</sup> Nicholson et al<sup>9</sup> reported significant improvement in ASES, SST, and VAS in patients who underwent lateral meniscus allograft in 18-month follow-up, with 94% of patients stating they would undergo the procedure again. This was supported by Wirth,<sup>16</sup> who published his results with meniscal allograft in 30 patients monitored for an average of 3 years. Significant improvement was noted in VAS pain scale, SST, and ASES questionnaire vs preoperative measures.<sup>16</sup> Elhassan et al<sup>4</sup> also reported results of glenoid BR using Achilles tendon allograft, fascia lata, and anterior capsule. In their group, 10 of 13 patients required revision to TSA at a mean of 14 months.<sup>4</sup>

In our study, a 60% failure rate was found in the BR group. Overall the BR maintained the joint surface because no glenoid erosion occurred, so it can be assumed that this was not the mode of failure. Five were revised to TSA and 1 required graft removal. All failures occurred within the first year, with most of those patients not obtaining any benefit from the procedure. This time to revision was nearly twice as fast as that in the HA group (2 vs 3.9 years). Most revisions were secondary to persistent pain and stiffness, with one being due to infection. These results are less promising than most studies in the literature and raise more concern regarding this procedure.

Glenoid erosion, as noted, is the primary identifiable reason for persistent pain and reason for failure for HA. In this study, BR maintained joint space, but a significant failure rate was still observed. The primary mode of failure in the BR group was persistent pain, stiffness, and ASES scores under 50. This suggests a separate mode of failure. ROM scores were not significantly different between groups. These findings are not completely understood in this population and have not been elucidated in the literature.

The present study has some limitations. Most significantly, the retrospective design prevented a randomization of the patients treated by HA or HA with BR. Patients were selected for each surgery based on the physician's decision about which operation would most benefit the patient. Indications for BR included symptomatic bipolar disease and anticipation of return to high-intensity athletic or work-related activity, which might have resulted in a selection bias for BR to have a worse initial state.

In addition, the study involved a time period of growing interest in BR, which might have influenced surgeon indications. However, the HA and BR groups did not differ significantly in age, sex, prior surgery, or other demographic factors. The indication for surgery for all patients was bipolar glenohumeral arthritis requiring surgery and age younger than 50 years at a single institution. However, there were significant differences in the etiology diagnosed at the time of the index procedure, which were not controlled for and might have influenced postoperative outcomes. For example, the HA group contained a significant number of patients with a primary diagnosis of AVN relative to the BR group. In addition, a greater number of patients in the BR group carried a primary diagnosis of postcapsulorrhaphy DJD. This would imply a tighter joint capsule, which would require more soft tissue releases to gain glenoid exposure, particularly in those undergoing humeral head resurfacing because the head is not completely resected.

Finally, this study included a relatively short-term follow-up of patients. However, the high failure rate in this study despite the relatively short follow-up, particularly in the BR group, is concerning, and has been reported by other authors.

## Conclusions

The management of young, active patients with symptomatic glenohumeral arthritis is a treatment challenge, and results have been varied with differing treatment options. This is reflected in the inconsistent outcomes reported in the orthopedic literature. Alternative treatments to TSA have been investigated in this patient population in an effort to improve postoperative outcomes and avoid the likely need for revision surgery secondary to failure of the glenoid component over time. BR of the glenoid in combination with humeral head HA has been described with varying results. In our short-term evaluation of patients younger than 50 years, treated with HA alone or HA with BR, we found that HA provided significantly greater pain relief and subjective overall improvement, with fewer failures than BR. Although HA with or without BR remains an option for patients with symptomatic glenohumeral arthritis aged

younger than 50 years, we believe that using HA alone may require fewer revisions and have more reproducible results.

### Military disclaimer

The views expressed in this article are those of the author(s) and do not necessarily reflect the official policy or position of the Department of the Navy, Department of Defense or the United States Government. LCDR James Hammond is a military service member. This work was prepared as part of his official duties. Title 17 U.S.C. 105 provides that "Copyright protection under this title is not available for any work of the United States Government." Title 17 U.S.C. 101 defines a United States Government work as a work prepared by a military service member or employee of the United States Government as part of that person's official duties.

### Disclaimer

A.R. has a financial relationship with the following entities: speakers' bureau (Arthrex Inc, DJO Surgical, and the Joint Restoration Foundation), consultancy (Arthrex Inc), grant/research support (AANA, MLB), and other travel expenses (Arthrex Inc). N.V. has a financial relationship with the following entities: board membership (Smith & Nephew, Shoulder Advisory Board, Vindico Medical), consultancy (Smith & Nephew), grant/research support (AANA, MLB), royalties (Smith and Nephew), stock/stock options (Omeros), and fellowship and research support (Arthrex Inc, Smith & Nephew, Ossur, Linvatec). G.N. has a financial relationship with the following entities: consultation fees (Tornier Inc) and royalty payments (Zimmer Inc). B.C. has a financial relationship with the following entities: board member/owner/officer/committee appointments (Carticept, Regentis, International Committee AANA), royalties (Arthrex Inc, DJ Ortho), paid consultant (Zimmer, Arthrex Inc, DePuy), research or institutional support (Arthrex Inc, Zimmer, DePuy, OREF/Stryker, NIH/MIMAS, Johnson & Johnson Regenerative Therapeutics LLC, Arthrosurface), and fellowship support (Smith & Nephew). The other authors, their immediate families, and any research foundations with which they are affiliated have not received any financial payments or other benefits from any commercial entity related to the subject of this article.

### References

- Bohsali KI, Wirth MA, Rockwood CA Jr. Complications of total shoulder arthroplasty. *J Bone Joint Surg Am* 2006;88:2279-92. <http://dx.doi.org/10.2106/JBJS.F.00125>
- Burkhead WZ Jr, Krishnan SG, Lin KC. Biologic resurfacing of the arthritic glenohumeral joint: historical review and current applications. *J Shoulder Elbow Surg* 2007;16:S248-53. <http://dx.doi.org/10.1016/j.jse.2007.03.006>
- Creighton RA, Cole BJ, Nicholson GP, Romeo AA, Lorenz EP. Effect of lateral meniscus allograft on shoulder articular contact areas and pressures. *J Shoulder Elbow Surg* 2007;16:367-72. <http://dx.doi.org/10.1016/j.jse.2006.06.004>
- Elhassan B, Ozbaydar M, Diller D, Higgins LD, Warner JJ. Soft-tissue resurfacing of the glenoid in the treatment of glenohumeral arthritis in active patients less than fifty years old. *J Bone Joint Surg Am* 2009;91:419-24. <http://dx.doi.org/10.2106/JBJS.H.00318>
- Iannotti JP, Norris TR. Influence of preoperative factors on outcome of shoulder arthroplasty for glenohumeral osteoarthritis. *J Bone Joint Surg Am* 2003;85:251-8.
- Krishnan SG, Nowinski RJ, Harrison D, Burkhead WZ. Humeral hemiarthroplasty with biologic resurfacing of the glenoid for glenohumeral arthritis. Two to fifteen-year outcomes. *J Bone Joint Surg Am* 2007;89:727-34. <http://dx.doi.org/10.2106/JBJS.E.01291>
- Lee KT, Bell S, Salmon J. Cementless surface replacement arthroplasty of the shoulder with biologic resurfacing of the glenoid. *J Shoulder Elbow Surg* 2009;18:915-9. <http://dx.doi.org/10.1016/j.jse.2009.01.014>
- Levine WN, Djurasovic M, Glasson JM, Pollock RG, Flatow EL, Bigliani LU. Hemiarthroplasty for glenohumeral osteoarthritis: results correlated to degree of glenoid wear. *J Shoulder Elbow Surg* 1997;6:449-54.
- Nicholson GP, Goldstein JL, Romeo AA, Cole BJ, Hayden JK, Twigg SL, et al. Lateral meniscus allograft biologic glenoid arthroplasty in total shoulder arthroplasty for young shoulders with degenerative joint disease. *J Shoulder Elbow Surg* 2007;16:S261-6. <http://dx.doi.org/10.1016/j.jse.2007.03.003>
- Parsons IM, Millett PJ, Warner JJ. Glenoid wear after shoulder hemiarthroplasty: quantitative radiographic analysis. *Clin Orthop Relat Res* 2004;421:120-5.
- Pfahler M, Jena F, Neyton L, Sirveaux F, Mole D. Hemiarthroplasty versus total shoulder prosthesis: results of cemented glenoid components. *J Shoulder Elbow Surg* 2006;15:154-63. <http://dx.doi.org/10.1016/j.jse.2005.07.007>
- Radnay CS, Setter KJ, Chambers L, Levine WN, Bigliani LU, Ahmad CS. Total shoulder replacement compared with humeral head replacement for the treatment of primary glenohumeral osteoarthritis: a systematic review. *J Shoulder Elbow Surg* 2007;16:396-402. <http://dx.doi.org/10.1016/j.jse.2006.10.017>
- Rispoli DM, Sperling JW, Athwal GS, Schleck CD, Cofield RH. Humeral head replacement for the treatment of osteoarthritis. *J Bone Joint Surg Am* 2006;88:2637-44. <http://dx.doi.org/10.2106/JBJS.E.01383>
- Savoie FH 3rd, Brislin KJ, Argo D. Arthroscopic glenoid resurfacing as a surgical treatment for glenohumeral arthritis in the young patient: midterm results. *Arthroscopy* 2009;25:864-71. <http://dx.doi.org/10.1016/j.arthro.2009.02.018>
- Sperling JW, Cofield RH, Rowland CM. Neer hemiarthroplasty and Neer total shoulder arthroplasty in patients fifty years old or less. Long-term results. *J Bone Joint Surg Am* 1998;80:464-73.
- Wirth MA. Humeral head arthroplasty and meniscal allograft resurfacing of the glenoid. *J Bone Joint Surg Am* 2009;91:1109-19. <http://dx.doi.org/10.2106/JBJS.H.00677>