



A long-head of biceps tendon rupture in a fast pitch softball player: A case report

Amon T. Ferry, MD^{a,*}, Gregory H. Lee, MD^a, Richard Murphy, MD^b,
Anthony A. Romeo, MD^a, Nikhil N. Verma, MD^a

^aDivision of Sports Medicine, Department of Orthopaedic Surgery, Rush University Medical Center, Chicago, IL

^bOmaha Orthopedic Clinic and Sports Medicine, Omaha, NE

Rupture of the long head of the biceps tendon (LHBT) is a common tendon injury, and can be the result of a degenerative process or a sudden traumatic event. Compression and repetitive trauma to the tendon as it passes beneath the subacromial arch can result in microtears that weaken the tendon and lead to rupture. Traumatic ruptures in young athletes are seldom described but can occur during a sudden overload event,¹⁶ where forced extension of the elbow against an eccentrically contracting biceps muscle overcomes the tensile strength of the tendon.¹¹ Jobe et al⁶ suggested that LHBT rupture in throwers can be associated with glenohumeral instability, and when forces during activity exceed the anterior static restraints, the muscles fatigue, resulting in anterior and superior migration of the humeral head and worsening of the pre-existing subacromial impingement.

Previous case reports of LBHT ruptures in younger athletes have been in weightlifters² and been attributable to anabolic steroid abuse. To our knowledge, there is no report in the literature of an isolated LHBT in an underhand thrower. In our experience, biceps tenosynovitis and anterior shoulder pain are common complaints in elite windmill pitchers. It is possible that the unique stresses placed on the LHBT, due to increased biceps muscle activity or increased tendon excursion in the windmill-pitching motion, creates a risk for tendinosis and rupture.

*Reprint requests: Amon Ferry, MD, Department of Orthopedic Surgery, Rush University Medical Center, 1643 W. Harrison St., Suite 1471, Jelke Building, Chicago, IL 60612.

E-mail address: atferry@hotmail.com (A.T. Ferry).

Case report

A 24-year-old, otherwise healthy, right-hand dominant, female, professional softball pitcher initially presented complaining of anterosuperior pain in her right shoulder, aggravated with overhead activity and pitching. On initial physical exam, she had a significant deficit in glenohumeral internal rotation, as well as clinical signs of impingement with reproduction of her pain in abduction and internal rotation. A magnetic resonance arthrogram was obtained, which failed to show an abnormality. At that time, the patient was treated with a subacromial injection consisting of short- and long-acting local anesthetics and a corticosteroid, as well as posterior capsular stretching exercises, and was withheld from pitching for one week. She returned 2 weeks later with continued complaints of posterior shoulder pain that prevented her from pitching more than 1 inning and limited her to 70-80% of her normal strength. At that time, she had reproduction of her pain with abduction and external rotation of her arm. She was treated with a glenohumeral injection and was again withheld from play for 1 week, avoiding any heavy lifting and working with a therapist. She had significant improvement in clinical exam and symptoms immediately following the injection.

Two weeks later, the patient experienced a pop while pitching and noticed a deformity of her throwing arm. The injury occurred in the 2nd inning, but she continued to pitch an additional 3 innings with only mild discomfort and no significant decrease in her effectiveness. On physical exam, the patient had a Popeye-deformity of the arm, which was clearly asymmetric to the opposite side. No bruising or ecchymosis was noted. She did, however, have mild tenderness to palpation over the biceps interval. Range of motion and strength of the shoulder was full and symmetric to her contralateral side. The patient had negative liftoff and belly press signs and no complaints of or physical exam findings consistent with instability. Three days after the injury, an

MRI was obtained and confirmed the diagnosis of proximal rupture of the long head of biceps tendon with retraction of the tendon 7-8 cm down the bicipital groove. No other abnormalities were noted.

The patient returned to pitching and was able to finish the remaining 3 weeks of the season with only occasional cramping of her pitching arm. She elected to undergo a proximal biceps tenodesis during the off-season to eliminate cramping, as well as for improved cosmesis. Approximately 9 weeks after injury, the patient underwent a diagnostic arthroscopy that identified the proximal biceps stump and a small (8-10 mm) partial thickness SLAP tear (Figure 1). The rotator cuff and subscapularis tendons were noted to be intact. Treatment at that time included arthroscopic debridement of the proximal tendon stump and open subpectoral biceps tenodesis. A number-2 Fiberwire (Arthrex, Naples, FL) suture was placed into the tendon stump using a Bunnell-type suture, and the tendon and suture were then inserted into the humerus through a proximal burr hole with the sutures tied inferiorly over a bone bridge.

One year from surgery, the patient had returned to competitive pitching at the professional level with no subjective deficit in either pitch speed or location. Clinically, she had no obvious deformity compared to her normal contralateral arm (Figure 2) and had full symmetric range of motion and strength in both elbow flexion and forearm supination of both upper extremities.

Discussion

Because of the relative dearth of literature examining LHB activity in underhand throwers, much of our understanding of the stresses on the musculoskeletal structures around the shoulder during this pitching motion comes from the literature on overhand pitching. This is not entirely inappropriate, as recent studies have reported the distraction forces across the shoulder and elbow joints to be similar during underhand and overhand pitching, suggesting that underhand throwing athletes are at a similar risk for overuse injuries and that the demands of resisting glenohumeral distraction places the biceps-labral complex at risk.^{17,18}

The function of the biceps muscle is primarily as an elbow flexor and forearm supinator²⁰; however, there is no consensus in the literature regarding its role in shoulder motion and stability. It has been proposed that the LBHT may function as a humeral head depressor⁸ in the presence of rotator cuff deficiency or as a dynamic stabilizer of the glenohumeral joint¹⁵ in patients with instability. In the throwing athlete, the LHB is among several muscles that help to position the shoulder and elbow in space.⁵ The LHB has also been identified as a muscle that provides a large deceleration force during the pitching motion.¹ In each of these instances, significant activity of LHB muscle leads to increased tension through the LBHT and places it at risk for overuse injuries.

In an effort to elucidate the role of the LHB muscle in shoulder motion and stability, previous studies have examined its electromyographic (EMG) activity in various shoulder motions with the elbow immobilized. Sakurai

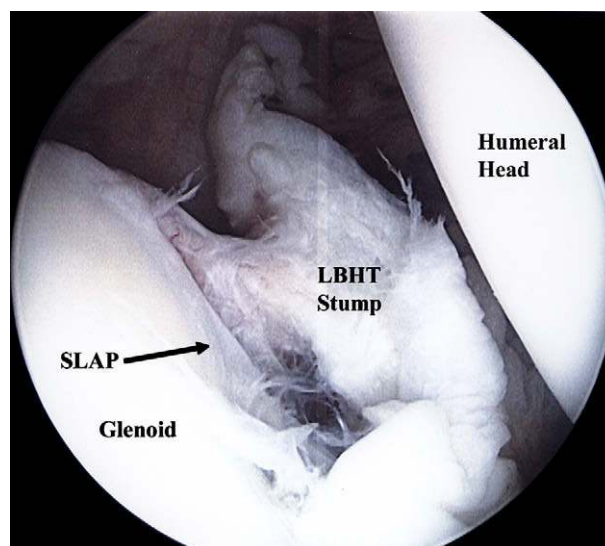


Figure 1 Arthroscopic view of glenohumeral joint as viewed from the posterior portal showing the intraarticular proximal LBHT stump attached to the superior glenoid labrum and associated SLAP tear.

et al¹⁴ recorded significant LHB activity in a variety of shoulder positions and concluded that the LHB does function in shoulder activity. Other studies, however, demonstrated no clinically significant EMG activity during shoulder motion in normal patients, as well as those with rotator cuff tears, and thus concluded that the LHB has no role in shoulder motion.^{9,20} The LHB muscle has been shown to be active during overhand throwing, particularly during the early and late cocking stages of pitching.⁵ Furthermore, a significant increase in LHB muscle activity has been shown during the acceleration phase of pitching in patients with anterior glenohumeral instability, compared to normal controls, and suggests that the LHB may play a role not only in the early and late cocking phases, but also in stabilization of the glenohumeral joint while pitching.⁴ To our knowledge, no published reports have studied the activity of the LHB in windmill pitching. Clearly, further studies are needed to understand which intrinsic and extrinsic factors may lead to recruitment of the LHB muscle during general shoulder activity, and, more specifically, in the overhand and underhand throwing athletes.

Special considerations are necessary when evaluating and treating throwing athletes with biceps tendon pathology, especially in the underhand thrower. Compared to baseball teams, softball teams typically have fewer pitchers. They, therefore, tend to throw in multiple consecutive games, leading to higher pitch counts, far exceeding those allowed in baseball. In a previous study surveying 8 collegiate softball teams competing in the 1989 women's NCAA tournament, time-loss injuries occurred in 50% of players, and 80% of these injuries were in the upper extremity.¹⁰ Overall, the function of the LHB and its contribution to the throwing motion, either underhand or

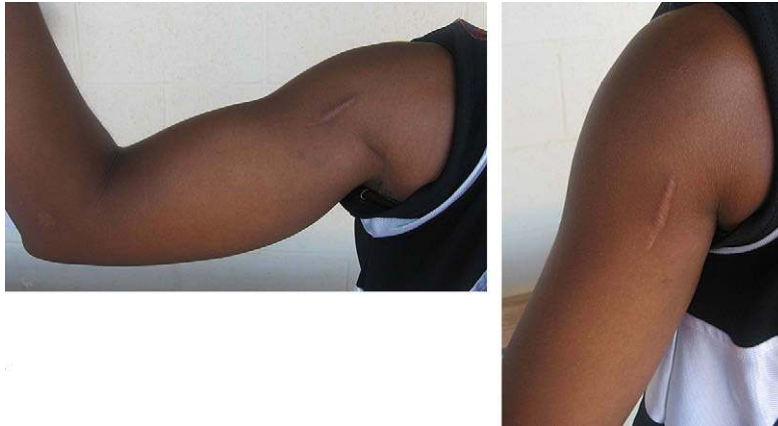

Figure 2 Clinical photographs showing post-operative scar from open tenodesis and resolution of cosmetic deformity.

windmill, remains incompletely understood. However, because of the uncertainty regarding the exact role of the LHB in these elite athletes and the potential adverse impact on throwing ability, there has been a general reluctance to treat biceps pathology with tenotomy or tenodesis.

In caring for a professional softball team, we have found that anterior shoulder pain is a common complaint among windmill pitchers and often localizes to the biceps tendon. We hypothesize 2 possible mechanisms for this finding. First, the biceps muscle may be more active during the windmill pitching motion, particularly during the deceleration phase of throwing, where the shoulder is in low degrees of flexion and undergoing a distractive force. In this position, the biceps may be required to provide deceleration both at the elbow and shoulder. Second, the shoulder goes through a nearly 360° arc of motion during windmill pitching, a significant increase compared to overhand throwing. This increased motion may result in an increased LHBT excursion through the groove that can contribute to an increased incidence of tenosynovitis and pain.

The use of corticosteroid injections in this case may have weakened or retarded the healing of an already injured tendon and placed it at a higher risk for rupture. However, a recent review of the literature focusing on the use of corticosteroids in athletes failed to identify a consensus regarding the possible damage to musculoskeletal structures with the use of injectable corticosteroids.¹² In our experience, subacromial and glenohumeral corticosteroid injections have been used safely and effectively to treat shoulder pain of various etiologies in the elite athlete. The athlete in this case sustained an injury to the LHBT in her throwing arm related to the repetitive trauma of windmill pitching. Patients with obvious clinical signs of a LHBT rupture, as seen in this patient, do not necessarily require an MRI scan to make the diagnosis. In this case, we were concerned that, with the new injury, there might be concomitant pathology that would need to be addressed at the time of surgery, and a repeat MRI was thus ordered.

The management of LHBT rupture is controversial. It has been suggested that in the elderly, low demand patient, it is reasonable to treat them nonoperatively. In this patient group, outcomes of arthroscopic tenotomy have been acceptable and equivalent to tenodesis indicating that the loss of LHB tendon continuity is well tolerated.^{3,13} A previous study examining the pullout strength of the distal LHBT in the bicipital groove after tenotomy found that only 110N (approximately equal to 5 pounds in the hand) was required to cause distal migration of the tendon in the groove, compared to a pullout strength that averaged 310N for tenodesis with a biotenodesis screw.¹⁹ Therefore, it is widely accepted that in younger, higher demand patients, the tendon will migrate distally and lead to a poorly tolerated cosmetic deformity and cramping with repetitive biceps activity. In this group of patients, surgical tenodesis is recommended to re-establish a normal length-tension relationship on the muscle-tendon unit.⁷

In this patient, we have found no negative impact on shoulder function and pitching ability following LHB rupture and tenodesis. During the season following her surgery, the patient had no further complaints of anterior shoulder pain or biceps cramping. Her performance would suggest a limited or non-critical role of the LHB in windmill pitching, even at the professional level.

References

1. Andrews JR, Carson WG Jr, McLeod WD. Glenoid labrum tears related to the long head of the biceps. *Am J Sports Med* 1985;13:337-41.
2. Cope MR, Ali A, Bayliss NC. Biceps rupture in body builders: Three case reports of rupture of the long head of the biceps at the tendon-labrum junction. *J Shoulder Elbow Surg* 2004;13:580-2.
3. Gill TJ, McIrvin E, Mair SD, Hawkins RJ. Results of biceps tenotomy for treatment of pathology of the long head of the biceps brachii. *J Shoulder Elbow Surg* 2001;10:247-9.
4. Glousman R, Jobe F, Tibone J, Moynes D, Antonelli D, Perry J. Dynamic electromyographic analysis of the throwing shoulder with glenohumeral instability. *J Bone Joint Surg Am* 1988;70:220-6.

5. Gowan ID, Jobe FW, Tibone JE, Perry J, Moynes DR. A comparative electromyographic analysis of the shoulder during pitching. Professional versus amateur pitchers. *Am J Sports Med* 1987;15:586-90.
6. Jobe FW, Kvitne RS, Giangarra CE. Shoulder pain in the overhand or throwing athlete. The relationship of anterior instability and rotator cuff impingement. *Orthop Rev* 1989;18:963-75.
7. Klonz A, Reilmann H. [Biceps tendon: diagnosis, therapy and results after proximal and distal rupture]. *Orthopade* 2000;29:209-15.
8. Kumar VP, Satku K, Balasubramaniam P. The role of the long head of biceps brachii in the stabilization of the head of the humerus. *Clin Orthop* 1989;244:172-5.
9. Levy AS, Kelly BT, Lintner SA, Osbahr DC, Speer KP. Function of the long head of the biceps at the shoulder: electromyographic analysis. *J Shoulder Elbow Surg* 2001;10:250-5.
10. Loosli AR, Requa RK, Garrick JG, Hanley E. Injuries to pitchers in women's collegiate fast-pitch softball. *Am J Sports Med* 1992;20:35-7.
11. Moorman CT, Silver SG, Potter HG, Warren RF. Proximal rupture of the biceps brachii with slingshot displacement into the forearm. A case report. *J Bone Joint Surg Am* 1996;78:1749-52.
12. Nichols AW. Complications associated with the use of corticosteroids in the treatment of athletic injuries. *Clin J Sport Med* 2005;15:370-5.
13. Phillips BB, Canale ST, Sisk TD, Stralka SW, Wyatt KP. Ruptures of the proximal biceps tendon in middle-aged patients. *Orthop Rev* 1993;22:349-53.
14. Sakurai G, Ozaki J, Tomita Y, Nishimoto K, Tamai S. Electromyographic analysis of shoulder joint function of the biceps brachii muscle during isometric contraction. *Clin Orthop* 1998;354:123-31.
15. Warner JJ, McMahon PJ. The role of the long head of the biceps brachii in superior stability of the glenohumeral joint. *J Bone Joint Surg Am* 1995;77:366-72.
16. Warren RF. Lesions of the long head of the biceps tendon. St. Louis: C.V. Mosby; 1985. Vol 34.
17. Werner SL, Guido JA, McNeice RP, Richardson JL, Delude NA, Stewart GW. Biomechanics of youth windmill softball pitching. *Am J Sports Med* 2005;33:552-60.
18. Werner SL, Jones DG, Guido JA Jr, Brunet ME. Kinematics and kinetics of elite windmill softball pitching. *Am J Sports Med* 2006;34:597-603.
19. Wolf RS, Zheng N, Weichel D. Long head biceps tenotomy versus tenodesis: a cadaveric biomechanical analysis. *Arthroscopy* 2005;21:182-5.
20. Yamaguchi K, Riew KD, Galatz LM, Syme JA, Neviaser RJ. Biceps activity during shoulder motion: an electromyographic analysis. *Clin Orthop* 1997;336:122-9.