

Incidence of Early Development of Radiolucent Lines in Keeled Polyethylene Glenoid Components After Total Shoulder Arthroplasty

Shane J. Nho, MD, MS, Rachel M. Frank, BA, BS, Nikhil N. Verma, MD, and Anthony A. Romeo, MD

Abstract

Glenoid loosening after total shoulder arthroplasty (TSA) remains a major concern. The purpose of this study was to determine the incidence of radiolucent lines (RLLs) after TSA performed with modern glenoid bone preparation and cement techniques for keeled-back glenoid components.

One hundred ten consecutive patients with osteoarthritis were included in this study. Patients had undergone primary TSA with a keeled-back glenoid component. Mean age was 64.0 years (SD, 10.6 years; range, 27-91 years). Two independent, blinded observers assessed the initial postoperative radiographs for RLLs using the Molé, Torchia, and Franklin classification systems.

On 93 (84.5%) of the 110 radiographs, there was no evidence of RLLs; on the other 17 radiographs (15.5%), there was evidence of RLLs. Mean Torchia score was 0.02 (SD, 0.13) on the anteroposterior view and 0.14 (SD, 0.34) on the axillary lateral view. Mean Franklin score was 0.02 (SD, 0.13) on the anteroposterior view and 0.21 (SD, 0.62) on the axillary lateral view. Incidence of early RLLs in keeled-back glenoid components prepared with modern cement and bone compaction techniques was 15.5%, similar to what other investigators have reported for pegged-back glenoid components.

Loosening of the glenoid component remains a major concern, as it is one of the most common reasons for revision shoulder arthroplasty. Estimated incidence of radiolucent lines (RLLs) varies widely from series to series, with reported rates ranging from 28.4% to more than 90%.¹⁻⁶ Studies

Dr. Nho is Assistant Professor of Orthopedic Surgery, Ms. Frank is medical student and research fellow, Dr. Verma is Assistant Professor of Orthopedic Surgery, and Dr. Romeo is Professor of Orthopedic Surgery and Section Head, Shoulder and Elbow, Division of Sports Medicine, Department of Orthopedic Surgery, Rush University Medical Center, Rush Medical College of Rush University, Chicago, Illinois.

Address correspondence to: Anthony A. Romeo, MD, Rush University Medical Center, 1611 W Harrison St, Suite 300, Chicago, IL 60612 (tel, 312-432-2377; fax, 312-563-0579; e-mail, shoulderelbowdoc@gmail.com).

Am J Orthop. 2010;39(7):333-337. Copyright Quadrant HealthCom Inc. 2010. All rights reserved.

with long-term serial radiographs have found RLL progression as early as 1 to 3 years after recognition.^{7,8} Although the incidence of RLLs and glenoid component loosening has been reported in numerous series,^{2-5,7-11} the significance of RLLs around the glenoid is still unclear, because the number of patients who required revision surgery for a radiographically loose glenoid component is relatively small.

Most articles in the RLL literature describe early surgical techniques and first-generation cement application.¹⁻⁶ The initial keeled-back glenoid components were prepared with an unguided hand-held motorized burr and digitally packed cement. These initial case series raised concern about the presence of RLLs identified with radiographs as early as the immediate postoperative period.⁵ As a result, glenoid component implantation changed dramatically. More recent studies, evaluating the rate of early RLLs, have suggested that RLL incidence has improved with meticulous glenoid bone preparation assisted with guides that provide the ability to accurately machine the glenoid to match the glenoid component, cement pressurization, and glenoid component design.^{6,12,13}

Pegged-back glenoids appeared to have a lower incidence of early RLLs and gained favor over keeled-back glenoids.^{6,11,13} The improvement with pegged-back components was attributed to the design of the component as well as to improved initial fixation, with the press-fit technique requiring less cement, which is thought to be a possible cause of thermal necrosis. Modern keeled-back glenoid components, however, are now implanted with a similar surgical technique, including bone compaction with identical keel geometry as the prosthetic component, and cement pressurization.

The purpose of the present study was to determine the incidence of early development of RLLs after total shoulder arthroplasty (TSA) performed with modern glenoid bone preparation and cement techniques for contemporary keeled-back glenoid components. Our hypothesis was that, with improvements in glenoid bone preparation and cement techniques, the RLL rate for keeled-back glenoid components would be less than previously reported in clinical series and would be similar to recently reported rates for pegged-back components.

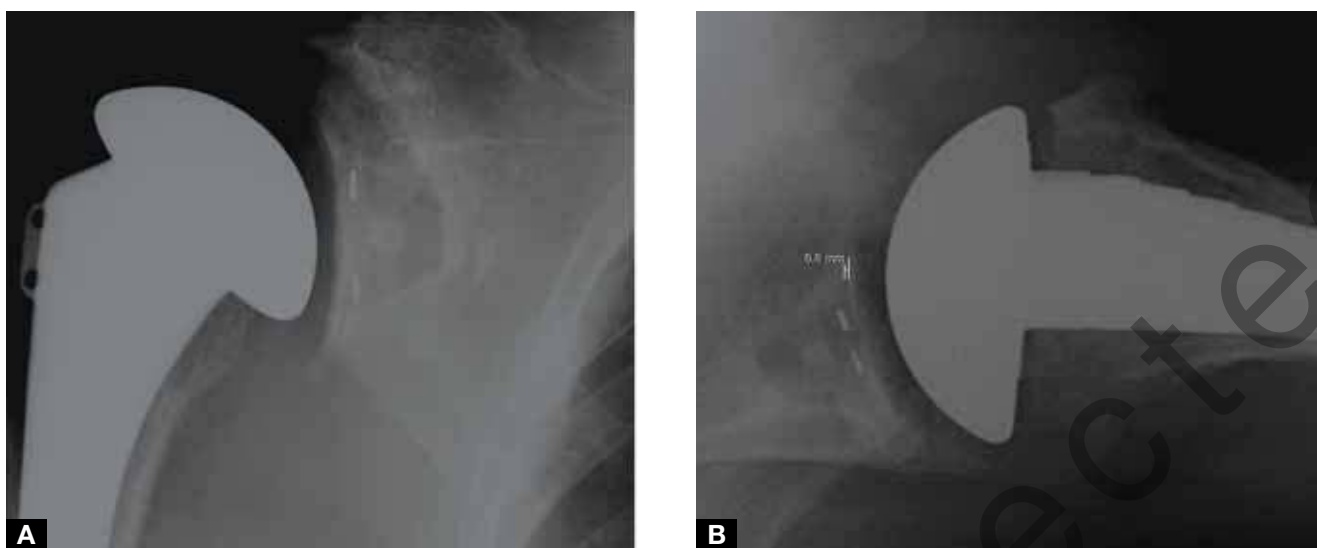


Figure. Representative radiographs with evidence of radiolucent lines in (A) zones 1 and 5 (anteroposterior view) and (B) zone 1 (line width, 0.8 mm; axillary lateral view).

MATERIALS AND METHODS

Between January 2006 and August 2008, an institutional database was retrospectively reviewed to identify patients who had undergone TSA by a single orthopedic surgeon. Included in the study were osteoarthritis patients who had undergone primary TSA with modern cement techniques and an all-polyethylene keeled-back glenoid component. Excluded were patients who had undergone shoulder hemiarthroplasty, revision shoulder arthroplasty, and reverse shoulder arthroplasty. An all-polyethylene keeled-back glenoid component was used for all patients (Aequalis, Tornier, Edina, Minn).

One hundred ten patients met the study criteria. Mean age was 64.0 years (SD, 10.6 years; range, 27-91 years). There were 57 women (51.8%) and 53 men (48.2%). The right shoulder was involved in 58 cases (52.7%) and the left shoulder in 52 cases (47.3%). Postoperative radiographs were obtained a mean of 15.8 days (SD, 12.4 days; range, 7-45 days) after TSA.

The surgical technique for glenoid preparation was consistently performed to maximize the fixation of the keeled-back glenoid component. Once the glenoid was adequately exposed, the labrum and excessive soft tissue surrounding the glenoid rim was removed. The biceps tendon was routinely released from its insertion on the superior glenoid. A large curette was used to remove any remaining soft tissue on the face of the glenoid, including cartilage and capsulolabral tissue, which may affect glenoid component implantation. The glenoid center line was determined by marking the superior-to-inferior glenoid center axis (superior, glenoid tubercle; inferior, triceps tendon) and anterior-to-posterior glenoid center axis.¹⁴ The intersection of the lines marked the location of the center hole. The glenoid guide with a single center hole was placed in the central axis of the glenoid.

At this point, glenoid version was assessed with pre-

operative imaging, including axillary lateral (AX) radiograph and computed tomography (CT) or magnetic resonance imaging. When significant glenoid retroversion was noted, it was corrected, either by using a burr to remove anterior glenoid bone or by changing the angle of the guide to increase anteversion with the goal of asymmetric reaming. The center hole was then created with the centering drill. In most cases, the center hole was contained entirely within the glenoid vault, and this was confirmed by probing the depth of the hole with a small elevator. When there was glenoid erosion with medialization, however, penetration of the cortex of the scapula was possible, in which case the exit site was along the anterior cortex of the scapular neck medial to the glenoid face (an anatomical study showed that this corresponds to the anatomical glenoid center line¹⁴).

Glenoid reaming began with the small reamer and gradually increased to the appropriate size corresponding to the desired radius of curvature of the glenoid component—this is slightly larger than the radius of curvature of the humeral head, which is selected based on the patient's normal humeral anatomy. Reaming was performed to correct any abnormality in version and to create a congruent, stable subcortical surface that matches the back of the glenoid implant. The second glenoid keel guide was positioned within the center hole and was aligned in the appropriate superior-inferior axis. Superior and inferior holes were then drilled. Next, the guide was removed, and a small rongeur was used to remove the bone bridge between the holes to create a connection between the three holes. The glenoid punch was advanced until flush with the bone surface. The glenoid punch matched the geometry of the glenoid component, providing impaction of the surrounding bone while creating a conforming slot for the keel. Pulsatile lavage was used to remove bone and soft-tissue debris. Hemostasis was improved by using an epinephrine-soaked sponge that was

Table I. Torchia Classification for Glenoid Loosening

Not loose	No radiolucent lines, or lines limited to flange; no change in position
Minimal risk of loosening	Incomplete line <2 mm, involving <1/3 of keel
Possibly loose	Incomplete line <2 mm, involving >1/3 of keel
Probably loose	Complete line <1.5 mm or incomplete line \geq 2 mm in diameter, involving >1/3 of keel
Definitely loose	Complete line >1.5 mm in diameter or shift in position

Adapted from Torchia ME, Cofield RH, Settergren CR. Total shoulder arthroplasty with the Neer prosthesis: long-term results. *J Shoulder Elbow Surg.* 1997;6(6):495-505. Copyright, Elsevier. With permission.

Table II. Franklin Classification for Glenoid Lucency

Grade 0	None
Grade 1	<1 mm, incomplete
Grade 2	1 mm, complete
Grade 3	1.5 mm, incomplete
Grade 4	1.5 mm, complete
Grade 5	>2 mm, complete

Adapted from Franklin JL, Barrett WP, Jackins SE, Matsen FA 3rd. Glenoid loosening in total shoulder arthroplasty. Association with rotator cuff deficiency. *J Arthroplasty.* 1988;3(1):39-46. Copyright, Elsevier. With permission.

packed into the glenoid vault. Once the cement was ready to be inserted, the gauze was removed. The cement was injected into the slot for the keel and pressurized by impacting with the glenoid keel punch. This step was repeated 1 to 2 times to compress the cement into the cancellous glenoid bone. Cement was not injected until it could be palpated without sticking to the surgeon's glove. A small amount of cement was also placed on the glenoid keel, and any fenestrations in the keel were filled with cement. The glenoid keel was then impacted into the glenoid vault and held firmly in place until the cement cured.

For interobserver and intraobserver reliability, 2 independent blinded observers (Dr. Nho, Ms. Frank) analyzed the plain radiographs. As part of routine postoperative management, anteroposterior (AP), scapular lateral, and AX plain radiographs were taken at the first postoperative office visit. All radiographs were analyzed on the Picture Archiving and Communication System (PACS) workstation and scored (according to the criteria to be described). The extent and amount of radiolucency on the AP view were measured with digital calipers according to the system described by Molé and colleagues.¹⁵ The same method was adapted to the AX radiographs, with radiolucencies measured in 3 zones corresponding to the anterior rim (zone 1), around the fixation keel (zone 2), and the posterior rim (zone 3) of the glenoid. Glenoid loosening (according to Torchia and colleagues⁷) and lucency (according to Franklin and colleagues¹⁶) were classified for each glenoid based on the AP and AX views (Tables I, II). Interobserver κ was 0.7686 (95% confidence interval, 0.5911-0.9461).

RESULTS

On 93 (84.5%) of the 110 radiographs, there was no evidence of RLLs; on the other 17 radiographs (15.5%), there was evidence of RLLs. None of the radiographs

showed radiolucency completely around the keeled-back glenoid component. The RLLs were identified on the AX view (15 cases), on the AP view (1), or on both views (1) (Figure 1). On the AX view, 5 cases had RLLs in zone 1, 8 had RLLs in zone 3, and 2 had RLLs in both zones; mean RLL width was 0.84 mm (SD, 0.29 mm) in zone 1 and 0.90 mm (SD, 0.16 mm) in zone 3. On the AP view, 1 RLL (mean width, 0.55; SD, 0.35 mm) was found in zone 1, and 1 RLL (mean width, 0.55; SD, 0.07 mm) was found in zone 5. No radiographs had evidence of RLLs around the keel on the AP view (zones 2-4) or the AX view (zone 2).

Torchia scores⁷ indicated "minimal risk of loosening" for the 15 radiographs with an RLL on the AX view (mean score, 0.14; SD, 0.34) and the 2 radiographs with an RLL on the AP view (mean score, 0.02; SD, 0.13).

According to the Franklin classification, 11 of the 15 RLLs on the AX view (mean score, 0.21; SD, 0.62) were grade 1 (<1 mm, incomplete), and 4 were grade 3 (1.5 mm, incomplete); in addition, the 2 RLLs on the AP view (mean score, 0.02; SD, 0.13) were grade 1. In total, there were 13 grade 1 cases and 4 grade 3 cases.

DISCUSSION

In this study, at early postoperative follow-up, the incidence of RLLs in keeled-back glenoid components used with modern glenoid preparation and cement techniques was 15.5%. All radiographs were obtained within the first 6 weeks of implantation. Overall, the results demonstrate that modern glenoid bone preparation and cement techniques provide improved glenoid fixation compared with earlier techniques—decreasing the rate of early RLLs to 15.5%—and that the shape of the glenoid design (peg vs keel) is not as important as the bone compaction and cement technique.

None of the radiographs demonstrated complete RLLs around the glenoid component. When incomplete

RLLs were detected, the majority of the cases were visible on the AX view and not the AP view. Torchia scores indicated that all cases with early RLLs had a “minimal risk of loosening,” which is the lowest possible grade aside from that given to cases without RLLs.

In the literature, there has been much debate about the significance of RLLs after TSA, and RLL rates based on initial postoperative radiographs ranged from 28.4% to more than 90%.¹⁻⁶ Many of these early studies on RLLs after TSA were based on first-generation glenoid preparation and cement techniques. In 2002, Lazarus and colleagues¹¹ reported an alarming 94% of cases with evidence of RLLs on initial postoperative radiographs from 17 different shoulder surgeons. Given the large number of surgeons, details of the glenoid preparation and cement technique were omitted. Although the authors reported that the radiolucency and cementing scores were significantly better for the pegged-back glenoids than for the keeled-back glenoids, their results are difficult to interpret in the absence of the details regarding the glenoid preparation and cementing techniques. Compared with the others, the shoulder surgeon with the most experience had statistically significantly better cementing and component seating data, emphasizing the importance of surgical technique. Modern cement pressurization techniques modeled after total hip arthroplasty have also reduced the incidence of RLLs after glenoid implantation. Norris and Lachiewicz¹⁷ reported that, with use of modern cement technique, only 2 of 38 shoulders had RLLs around more than 50% of the interface between the glenoid bone and cement, and the series had a 5-year survivorship of 97%. Klepps and colleagues¹³ found a lower RLL rate for glenoid components inserted with pressurized cement versus manually packed cement, and the manually packed cement group had an increased incidence of RLL in each zone as well as a higher incidence of lines larger than 1 mm ($P < .05$).

Glenoid bone preparation has also substantially evolved with modern glenoid implant systems. Initially, the glenoid bone was reshaped to approximate the dimensions of the keel glenoid component by reaming the surface, then preparing a slot for the keel with a hand-held burr. Furthermore, many surgeons would then use a curette to remove cancellous bone in the glenoid vault. Current modern technique includes machining the glenoid keel slot with a guide, followed by compacting the glenoid cancellous bone with a punch. While the hand-held technique resulted in an RLL rate of 38%, the more precise bone preparation and compaction of the cancellous bone reduced the incidence of RLL to 11%.¹² The modern glenoid bone preparation for the keel component has several advantages, including a more stable base; geometric dimensions identical to those of the keel of the glenoid component, allowing for press-fit fixation; and less cement required (less cement decreases risk for thermal necrosis).¹⁸ In the surgical technique used in our study, the same keel punch

that was used to compact the cancellous glenoid bone was subsequently used to “pressurize” the cement. On plain radiographs, the cement mantle extends 3 to 5 mm or more beyond the boundary of the keel and therefore interdigitates with the glenoid cancellous bone. Other methods to improve the cement technique and reduce radiolucent lines have focused on techniques to improve hemostasis prior to inserting the cement. Edwards and colleagues¹⁹ compared 3 techniques for preparing the glenoid implant surface for cement application after the bone was prepared: 1) thrombin-soaked gel foam; 2) compressed gas lavage; and 3) saline solution lavage with sponge drying. The investigators found no significant differences among these techniques and recommended saline solution lavage with sponge drying as their preference because of the high costs associated with the other techniques.

Other factors may contribute to the presence of radiolucent lines, including the glenoid component shape and articular conformity. Szabo and colleagues¹² found no evidence of RLLs on immediate postoperative radiographs in 26% of flat-back glenoid components versus 65% of convex-back glenoid components ($P = .006$); however, convex-back glenoids have been favored owing to their ability to resist the shear forces that are present with normal shoulder movement.^{20,21} Glenohumeral prosthetic mismatch between the radius of curvature of the humeral head component and the radius of curvature of the glenoid component has also been reported to influence RLLs, with a radial mismatch of ≤ 5.5 mm found to be significantly associated with RLL scores.²² However, the ability of the glenoid component to resist shear forces and the noncongruent relationship with the humeral head radius of curvature should not be associated with increased incidence of RLL on early postoperative radiographs.

In the literature, the effect of using pegged-back versus keeled-back glenoid components has been controversial. Some studies have found no difference in glenoid lucency between the 2 designs,^{15,23-26} whereas others have reported a lower RLL rate for pegged-back glenoids.^{11,27-29} Gartsman and colleagues⁶ conducted a prospective, randomized study to compare the components, as used by a single surgeon, and found that glenoid lucency was 39% (9/23) in keeled-back glenoids versus 5% (1/20) in pegged-back glenoids ($P = .026$). While the same skilled shoulder surgeon implanted the glenoid, the method used to prepare the bone varied between the peg and keel components. For the peg components, the glenoid was machined using precise drill guides; for the keel components, a less precise guide was used to create a trough, and the bone was not compacted. Klepps and colleagues¹³ also found narrower RLLs and fewer RLLs larger than 1 mm with pegged-back versus keeled-back glenoids ($P < .05$), and they reported that bone compaction was used for both types of components. These two studies by Gartsman and colleagues⁶ and Klepps and colleagues¹³ suggest that a more precise preparation of the bone to match the

geometry of the glenoid component may improve the surgeon's ability to reduce radiolucent lines between the cement and glenoid bone interface.

Our study has limitations. The design is a case series without a comparison group (historical controls were used for comparison). In addition, measurements were based on routine AP and AX radiographs obtained at initial follow-up. We agree that fluoroscopy and CT can be used for more accurate assessment of RLLs, but plain radiographs represent a measurement technique that can be reproduced in the office setting. Radiographs were used at a single time point, but longer term studies would provide information about the rate of RLL progression.

Our study has several strengths. We evaluated 110 consecutive radiographs, which is more than other clinical studies. All surgeries were performed by a single shoulder surgeon working in a high-volume shoulder arthroplasty practice. Radiographic evaluation was performed by 2 independent, blinded reviewers, and interobserver reliability was high.

In this study, the incidence of early RLLs in keeled-back glenoids was 15.5%, a rate significantly lower than previously reported, and similar to the rates recently reported for pegged-back glenoids.^{6,30} Development of RLLs is a multifactorial problem, but advances in surgical technique have improved initial cement fixation of glenoid components regardless of the keel or peg geometry of the glenoid component. Glenoid bone preparation includes accurate determination of the glenoid center line, machining the glenoid to match the geometry of the prosthetic component, and compaction of the cancellous bone of the glenoid vault. Cement pressurization includes the use of an impactor with similar geometry to the prepared bone and manual pressure on the implanted glenoid component until the cement is cured, which allows for interdigitation of the cement within the cancellous bone-keel interface. Based on our results, we recommend meticulous glenoid bone preparation and pressurization of the cement to minimize the incidence of radiolucent lines when implanting an all-polyethylene keeled glenoid component.

AUTHORS' DISCLOSURE STATEMENT

Dr. Romeo notes that he has a patent pending on a peg glenoid. He also notes that he has received research and institutional support, miscellaneous funding, and royalties from Arthrex, Inc. (Naples, Fla) and is a consultant to Arthrex. The other authors report no actual or potential conflict of interest in relation to this article.

REFERENCES

1. Neer CS 2nd, Watson KC, Stanton FJ. Recent experience in total shoulder replacement. *J Bone Joint Surg Am.* 1982;64(3):319-337.
2. Cofield RH. Total shoulder arthroplasty with the Neer prosthesis. *J Bone Joint Surg Am.* 1984;66(6):899-906.
3. Barrett WP, Franklin JL, Jackins SE, Wyss CR, Matsen FA 3rd. Total shoulder arthroplasty. *J Bone Joint Surg Am.* 1987;69(6):865-872.
4. Hawkins RJ, Bell RH, Jallay B. Total shoulder arthroplasty. *Clin Orthop.* 1989;(242):188-194.
5. Brems J. The glenoid component in total shoulder arthroplasty. *J Shoulder Elbow Surg.* 1993;2(1):47-54.
6. Gartsman GM, Russell JA, Gaenslen E. Modular shoulder arthroplasty. *J Shoulder Elbow Surg.* 1997;6(4):333-339.
7. Torchia ME, Cofield RH, Settergren CR. Total shoulder arthroplasty with the Neer prosthesis: long-term results. *J Shoulder Elbow Surg.* 1997;6(6):495-505.
8. Mileti J, Boardman ND 3rd, Sperling JW, et al. Radiographic analysis of polyethylene glenoid components using modern cementing techniques. *J Shoulder Elbow Surg.* 2004;13(5):492-498.
9. Bade HA 3rd, Warren RF, Ranawat CS, Englis AE. Long-term results of Neer total shoulder replacement. In: Bateman JE, Welsh RP, eds. *Surgery of the Shoulder.* St. Louis, MO: Decker & Mosby; 1984:294.
10. Brenner BC, Ferlic DC, Clayton ML, Dennis DA. Survivorship of unconstrained total shoulder arthroplasty. *J Bone Joint Surg Am.* 1989;71(9):1289-1296.
11. Lazarus MD, Jensen KL, Southworth C, Matsen FA 3rd. The radiographic evaluation of keeled and pegged glenoid component insertion. *J Bone Joint Surg Am.* 2002;84(7):1174-1182.
12. Szabo I, Buscayret F, Edwards TB, et al. Radiographic comparison of two glenoid preparation techniques in total shoulder arthroplasty. *Clin Orthop.* 2005;(431):104-110.
13. Klepps S, Chiang AS, Miller S, Jiang CY, Hazrati Y, Flatow EL. Incidence of early radiolucent glenoid lines in patients having total shoulder replacements. *Clin Orthop.* 2005;(435):118-125.
14. Bicos J, Mazzocco A, Romeo AA. The glenoid center line. *Orthopedics.* 2005;28(6):581-585.
15. Molé D, Roche O, Riand N, Leveigne C, Walch G. Cemented glenoid components: results in osteoarthritis and rheumatoid arthritis. In: Walch G, Boileau P, eds. *Shoulder Arthroplasty.* Berlin, Germany: Springer-Verlag; 1999:163-171.
16. Franklin JL, Barrett WP, Jackins SE, Matsen FA 3rd. Glenoid loosening in total shoulder arthroplasty. Association with rotator cuff deficiency. *J Arthroplasty.* 1988;3(1):39-46.
17. Norris BL, Lachiewicz PF. Modern cement technique and the survivorship of total shoulder arthroplasty. *Clin Orthop.* 1996;(328):76-85.
18. Kelleher IM, Cofield RH, Becker DA, Beabout JW. Fluoroscopically positioned radiographs of total shoulder arthroplasty. *J Shoulder Elbow Surg.* 1992;1:306-311.
19. Edwards TB, Sabonghy EP, Elkousy H, et al. Glenoid component insertion in total shoulder arthroplasty: comparison of three techniques for drying the glenoid before cementation. *J Shoulder Elbow Surg.* 2007;16(3 suppl):S107-S110.
20. Anglin C, Wyss UP, Pichora DR. Mechanical testing of shoulder prostheses and recommendations for glenoid design. *J Shoulder Elbow Surg.* 2000;9(4):323-331.
21. Lacaze F, Kempf JF, Bonnomet F, Boutemy P, Colin F. Primary fixation of glenoid implants: an in vitro study. In: Walch G, Boileau P, eds. *Shoulder Arthroplasty.* Berlin, Germany: Springer-Verlag; 1999:141-146.
22. Walch G, Edwards TB, Boulahia A, Boileau P, Molé D, Adeleine P. The influence of glenohumeral prosthetic mismatch on glenoid radiolucent lines: results of a multicenter study. *J Bone Joint Surg Am.* 2002;84(12):2186-2191.
23. Aliabadi P, Weissman BN, Thornhill T, Nikpoor N, Sosman JL. Evaluation of a nonconstrained total shoulder prosthesis. *AJR Am J Roentgenol.* 1988;151(6):1169-1172.
24. Amstutz HC, Thomas BJ, Kabo JM, Jinnah RH, Dorey FJ. The Dana total shoulder arthroplasty. *J Bone Joint Surg Am.* 1988;70(8):1174-1182.
25. Carke IC, Sew Hoy AL, Gruen TA, Amstutz HC. Clinical and radiographic assessment of a non-constrained total shoulder. *Int Orthop.* 1981;5(1):1-8.
26. Wallace AL, Phillips RL, MacDougal GA, Walsh WR, Sonnabend DH. Resurfacing of the glenoid in total shoulder arthroplasty. A comparison, at a mean of five years, of prostheses inserted with and without cement. *J Bone Joint Surg Am.* 1999;81(4):510-518.
27. Lacroix D, Prendergast PJ. Stress analysis of glenoid component designs for shoulder arthroplasty. *Proc Inst Mech Eng H.* 1997;211(6):467-474.
28. Trail IA, Nuttall D. The results of shoulder arthroplasty in patients with rheumatoid arthritis. *J Bone Joint Surg Br.* 2002;84(8):1121-1125.
29. Wirth MA, Rockwood CA Jr. Complications of total shoulder-replacement arthroplasty. *J Bone Joint Surg Am.* 1996;78(4):603-616.
30. Barwood S, Setter KJ, Blaine TA, Bigliani LU. The incidence of early radiolucencies about a pegged glenoid component using cement pressurization. *J Shoulder Elbow Surg.* 2008;17(5):703-708.