

Humeral Avulsion of the Glenohumeral Ligament: Injury Pattern and Arthroscopic Repair Techniques

A. Dushi Parameswaran, MD; LCDR Matthew T. Provencher, MD, MC, USN; Bernard R. Bach Jr, MD; Nikhil Verma, MD; Anthony A. Romeo, MD

The arthroscopic treatment of a humeral avulsion of the glenohumeral ligaments lesion allows for a safe, reproducible, and effective way to reestablish the inferior glenohumeral ligament and capsular complex to the humerus.

The pathology of shoulder instability includes injury to both labrum and capsule. Labral injury can occur via separation of the labrum from the glenoid rim or direct bony injury to the anteroinferior glenoid (Bankart lesion).^{1,2} In most cases, capsular injury occurs as plastic deformation of the capsule or capsule stretching. However, in a small number of cases, capsular rupture either midsubstance or directly off the humeral attachment may occur.^{3,4} This type of cap-

sular detachment is known as a humeral avulsion of the glenohumeral ligaments. Bach et al⁵ first described a humeral avulsion of the glenohumeral ligaments lesion of the lateral capsule that was treated with open repair resulting in satisfactory outcomes. Although infrequently encountered, making the diagnosis of a humeral avulsion of the glenohumeral ligaments lesion and subsequent treatment are important to obtain a stable shoulder joint.

Drs Parameswaran, Bach, Verma, and Romeo are from the Department of Orthopedic Surgery, Rush University Medical Center, Chicago, Illinois; and Dr Provencher is from the Department of Orthopedic Surgery, Naval Medical Center San Diego, California.

Drs Parameswaran, Provencher, and Bach have no relevant financial relationships to disclose. Dr Verma is a consultant for Smith & Nephew. Dr Romeo is a consultant for Arthrex.

The views expressed in this article are those of the author (Provencher) and do not reflect the official policy or position of the Department of the Navy, Department of Defense, or United States Government.

Correspondence should be addressed to: Matthew T. Provencher, MD, Department of Orthopedic Surgery, 34800 Bob Wilson Dr, Ste 112, San Diego, CA 92134-1112.

Overall, the incidence of a humeral avulsion of the glenohumeral ligaments lesion in shoulder instability is a relatively uncommon event, but may approach up to 10% of instability injury patterns.⁶ Wolf et al,⁶ in a review of 64 shoulders with the diagnosis of glenohumeral instability, found a humeral avulsion of the glenohumeral ligaments lesion in 6 patients (9.3%). Bokor et al⁷ reviewed 547 shoulders with instability, and the cause of instability was considered to be avulsion of the lateral capsule, including the inferior glenohumeral ligament from the neck of the humerus, in 41 patients (7.5%). In 6 of 33 patients (18.2%) who underwent revision procedures for instability, a diagnosis of a humeral avulsion of the glenohumeral ligaments lesion was made, highlighting the need for identification and treatment of these lesions at the time of the index procedure.

Reports of humeral avulsion of the glenohumeral ligaments injuries in combination with a Bankart lesion⁸⁻¹⁰ have emphasized the importance of

a complete evaluation of the shoulder joint even in the presence of labral detachment.¹¹ Although 94% of humeral avulsion of the glenohumeral ligaments lesions have been diagnosed after violent trauma,^{4,12} a case report exists of a humeral avulsion of the glenohumeral ligaments lesion resulting from repetitive microtrauma associated with overhand throwing.¹³

BIOMECHANICAL CONSIDERATIONS

The humeral avulsion of the glenohumeral ligaments lesion is a recognized cause of glenohumeral instability. Nicola¹⁴ was the first to report that the inferior glenohumeral ligament complex could fail at the humeral insertion site in 4 of 5 acute cases of dislocations and in 6 of 25 recurrent dislocators. Nicola¹⁴ evaluated the likely mechanism of this pathology and found it to be in 105° of hyperabduction and external rotation.

Bigliani et al¹⁵ evaluated the inferior glenohumeral ligament complex in a cadaveric model

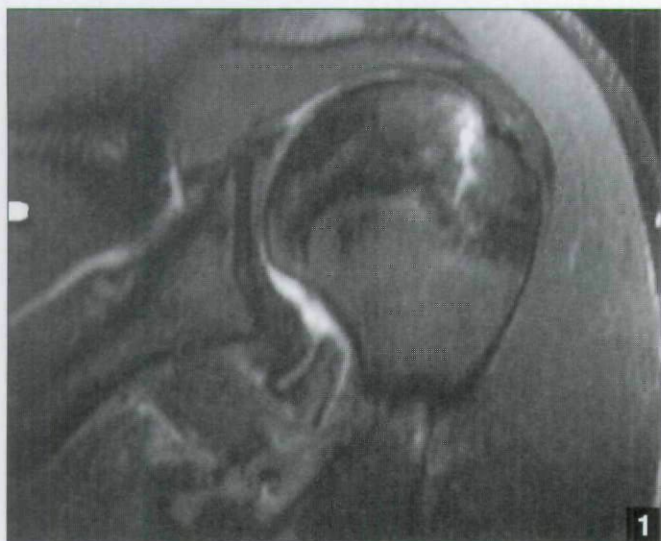

Figure 1: Coronal MRI of left shoulder showing lateral avulsion of inferior glenohumeral ligament complex.

and found that in loading the inferior glenohumeral ligament complex to failure, 25% of specimens resulted in humeral avulsion of the glenohumeral ligaments-type lesions.

Gagey et al¹⁶ experimentally dislocated cadaveric shoulders and found capsular failure at the humeral side in 63%. It is unclear why failure occurs at the humeral capsular insertion

more commonly in the laboratory setting than in standard clinical practice. The authors hypothesize that this may be related to a protective role of the subscapularis muscle, which cannot be duplicated in vitro.

Although lateral thinning of the capsuloligamentous structures from the glenoid to the humerus has been described, this finding is likely insufficient to result in clinical shoulder instability.¹⁷ Pouliart and Gagey¹⁸ performed a cadaveric study simulating the humeral avulsion of the glenohumeral ligaments lesion and showed that extensive capsuloligamentous lesions on the humeral side were required before dislocation can occur. The role of the superior glenohumeral ligament and the surrounding musculature on

the humeral side were cited as possible explanations for this discrepancy.

PATIENT EVALUATION AND RADIOGRAPHIC FINDINGS

Patient evaluation includes standard history and physical examination consistent with instability. Most patients will present with shoulder instability including either dislocation or subluxation. In most described cases of humeral avulsion of the glenohumeral ligaments lesion, the instability is related to an initial traumatic event. Physical examination consists of standard testing for shoulder range of motion, strength testing, and specific stability testing including anterior apprehension test, posterior jerk test, and inferior sulcus testing in both neutral and external rotation. There is no specific clinical test, however, that may clinically differentiate a humeral avulsion of the glenohumeral ligaments lesion from a more standard Bankart lesion.

Plain radiographs are rarely helpful in the diagnosis of a humeral avulsion of the glenohumeral ligaments lesion, although scalloping of the medial aspect of the humeral neck on the anteroposterior view has been reported as a specific finding.⁷ However, standard shoulder radiographs including an axillary lateral should be used to obtain information regarding glenoid and humeral bone loss, to assess for alterations in version, and to ensure that the glenohumeral joint is reduced. A magnetic resonance imaging (MRI) study is

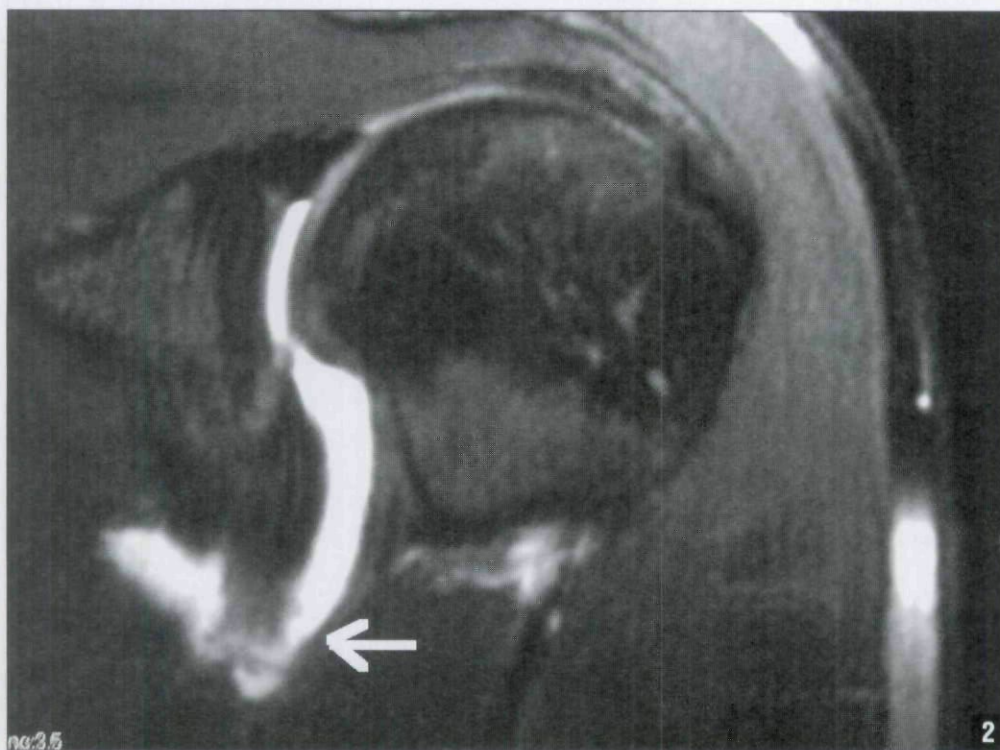


Figure 2: Coronal MR arthrogram of left shoulder revealing avulsion of inferior glenohumeral ligament complex off of the humeral head. The arrow indicates the detached ligament from the humerus.

recommended to assess the inferior glenohumeral ligament complex, the labrum, and the rotator cuff preoperatively. In a humeral avulsion of the glenohumeral ligaments lesion, MRI demonstrates irregularity of the humeral capsular attachment on both the axial and coronal oblique images (Figure 1). Additional specificity is afforded with the use of an MR arthrogram, which demonstrates extravasation of contrast material through the region of the capsular avulsion from the humeral neck with an expanded axillary pouch on the coronal images (Figure 2).¹⁹ The axillary pouch on the sagittal oblique images is converted from a fluid-distended U-shaped structure to a J-shaped structure as the inferior glenohumeral ligament is displaced inferiorly.¹⁹ Similar findings may be noted in acute settings with standard MRI where the pathologic fluid within the joint will act as contrast material.

Although MRI and arthrogram are good at determining capsular injury, the diagnosis of a humeral avulsion of the glenohumeral ligaments lesion is missed in up to 50% of cases based on imaging studies alone.²⁰ Furthermore, 68% of patients with a humeral avulsion of the glenohumeral ligaments lesion have associated shoulder injuries such as Hill-Sachs lesions, labral injuries, osteochondral injuries, and rotator cuff tears.²⁰ Therefore, a high index of suspicion must be maintained at the time of diagnostic arthroscopy to evaluate the entire inferior glenohu-

meral ligament complex and confirm normal attachment to the humerus laterally.

SURGICAL DECISION MAKING AND EVALUATION

The diagnosis of a humeral avulsion of the glenohumeral ligaments lesion as a cause for anterior shoulder instability can be difficult in an open anterior approach to the unstable shoulder. In defining the plane between the subscapularis tendon and the capsule, the inadvertent entry into the shoulder joint may disguise an actual humeral avulsion of the glenohumeral ligaments lesion. During the surgical approach, inadvertently leaving the deeper portion of the subscapularis over the capsule may mask the presence of a humeral avulsion of the glenohumeral ligaments lesion.⁶ Diagnostic arthroscopy allows for assessment of the glenohumeral complex at both the glenoid and humeral insertions. The humeral avulsion of the glenohumeral ligaments lesion is readily visualized from the posterior portal with the 30° arthroscope. Specifically, the humeral avulsion of the glenohumeral ligaments is generally seen in the inferior half of the shoulder, and is best seen in the axillary recess with the arthroscope from the posterior portal. The glenohumeral ligament complex can be seen to be avulsed from the humeral head exposing the subscapularis muscle fibers, which are confluent with the intra-articular portion of the subscapularis tendon.²¹ The capsule will appear thin and attenuated and will consist of thin strands of

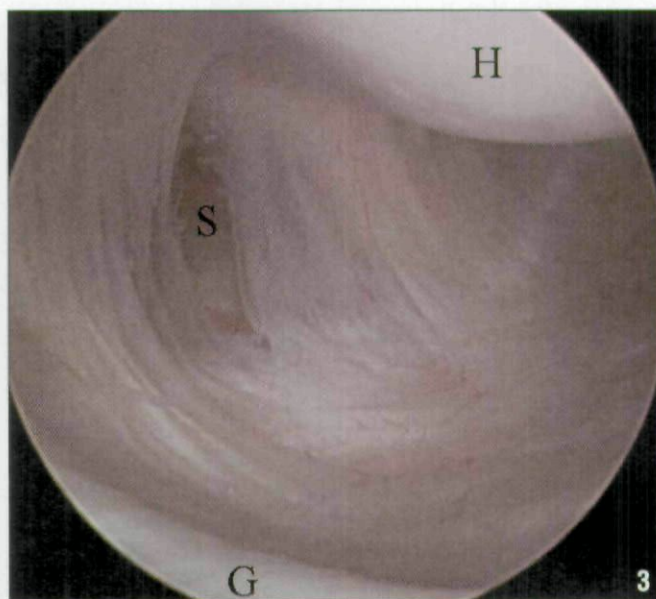


Figure 3: Arthroscopic view of the left shoulder from posterior portal with 30° scope. In external rotation, the attenuated capsule and capsular defect can be appreciated. The subscapularis muscle can be seen through the capsular defect. Abbreviations: G, glenoid; H, humeral head; S, subscapularis muscle.

capsular fibers detached from the lateral aspect of the humeral head. The axillary pouch should be well visualized in all cases and the attachment of the capsule to the humeral head fully documented. Internal and external rotation while looking at the capsular insertion on the humeral head may assist in diagnosis (Figure 3).

Humeral avulsion of the glenohumeral ligaments have been successfully repaired using both open and arthroscopic techniques.^{5-10,13} Arciero and Mazzocca²² described a mini-open technique in 8 patients in which the superior 50% of the subscapularis tendon is spared and the humeral avulsion of the glenohumeral ligaments lesion is anatomically repaired with suture anchors. An L-shaped incision is made in the lower half of the subscapularis tendon starting 1.5 cm medial to the lesser tuber-

osity. The humeral avulsion of the glenohumeral ligaments lesion is found by retracting the subscapularis tendon and muscle fibers superiorly. The inferior half of the subscapularis tendon is then repaired anatomically. By sparing the superior tendinous portion of the subscapularis tendon, Arciero and Mazzocca²² felt that strength was preserved and no recurrences of instability were seen. Others have described open approaches to repairing humeral avulsion of the glenohumeral ligaments lesions with traditional subscapularis detachment using suture anchors or sutures through drill holes to secure the avulsed edge of the lesion to the medial humeral neck.⁵⁻⁷

Several small series of all-arthroscopic repairs of humeral avulsion of the glenohumeral ligaments lesions have recently been described.^{21,23,24}

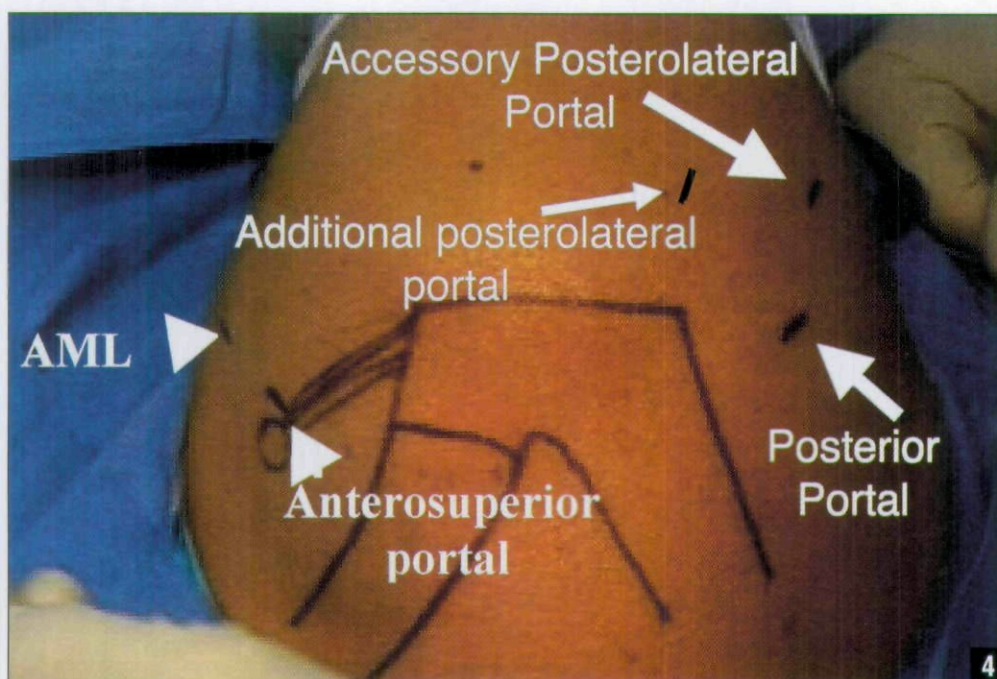


Figure 4: External view of the right shoulder illustrates the portals used in the arthroscopic HAGL repair. Abbreviation: AML, anterior midlateral portal.



Figure 5: Arthroscopic view of left shoulder from posterior portal with 70° scope. Free edge of avulsed glenohumeral ligament complex can be seen in this anterior HAGL lesion. Subscapularis muscle is seen superior and anterior to free edge of ligaments. Abbreviations: G, glenoid; H, humeral head; L, glenohumeral ligament complex; S, subscapularis muscle.

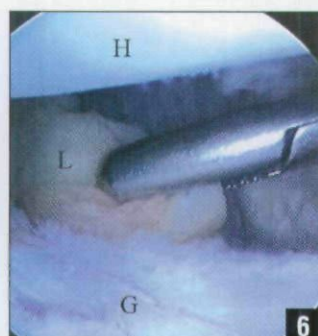


Figure 6: In this arthroscopic view of left shoulder from posterior portal with 70° scope, the grasper has been placed through the AML portal to reduce the capsular tissue to the humeral neck. Abbreviations: AML, anterior midlateral; G, glenoid; H, humeral head; L, glenohumeral ligament complex.

Wolf et al⁶ treated 4 humeral avulsion of the glenohumeral ligaments lesions with an arthroscopic plication of the inferior capsule and were able to tie it over the deltopectoral fascia in these patients. Huberty and Burkhart²⁵ reviewed a series of 6 patients over 4 years

who underwent all-arthroscopic repairs with an average follow-up of 31.8 months with good results. The advantages of arthroscopic treatment of a humeral avulsion of the glenohumeral ligaments lesion include easier identification of the lesion, minimal soft tissue trauma with specific regard

to the subscapularis, maximal surgical visualization, less postoperative pain, and accelerated and less-restrictive rehabilitation.

The following describes an all-arthroscopic technique with anatomic repair of the inferior capsuloligamentous complex to the humeral capsular insertion site with suture anchors.

SURGICAL TECHNIQUE

Our preference for instability procedures is to place the patient in the lateral decubitus position, but a beach-chair position may also be used. A formal examination under anesthesia is performed prior to prepping and draping. The operative arm is placed in 5 to 10 pounds of traction in 50° of abduction and 15° of forward flexion. A diagnostic arthroscopy is performed from the posterior portal, and an anterior portal is established in the

superior aspect of the rotator interval with a clear 5.25-mm cannula. The arthroscope is switched anteriorly, and the diagnostic arthroscopy is completed. With the arthroscope in the anterosuperior portal, an accessory posterolateral portal is made at the 7-o'clock position and cannula introduced over a smooth metal rod.²⁶ The arthroscope is switched back to the posterior portal, and a mid-to-low glenoid portal is established directly above the subscapularis tendon. The proper position for this portal is determined using an 18-gauge spinal needle. This portal is necessary for the proper angle of approach to the humeral bone bed as well as the anterior glenoid if necessary (Figure 4).²³

Once the portals are established, the humeral avulsion of the glenohumeral ligaments pathology is further clarified. The anterior glenohumeral ligaments are inspected from their glenoid/labral origin to their attachment on the humeral neck. In a humeral avulsion of the glenohumeral ligaments lesion, all or part of the middle and inferior glenohumeral ligament complexes are avulsed from their humeral insertion. The humeral insertion is best visualized with a 70° scope in the posterior portal or with a 30° scope placed in the anterosuperior portal (Figure 5). This portal is located just off the anterolateral corner of the acromion and enters the joint in the superior aspect of the rotator interval. A probe placed through the anterior midlateral portal is used to assess the

competency of the ligaments (Figure 4).

In long-standing recurrent instability, particular attention is paid to areas on the glenoid and humeral head for possible bone deficiency. If a large, engaging Hill-Sachs lesion or significant glenoid bone defect exists, the treatment plan is changed to that of an open Latarjet or alternative procedure to address the area of bone deficiency. If combined anterior humeral avulsion of the glenohumeral ligament-sand Bankart lesions are discovered, the humeral avulsion of the glenohumeral ligaments lesion should be reduced to the humeral neck with a grasper to adequately assess the tension of the capsule prior to performing the capsulolabral tensioning and repair. On a right shoulder, this would correspond to a position from approximately 8 to 6 o'clock on the humeral neck.²²

The capsular tissue avulsed off the humeral head is identified and reduced to the humeral neck with an arthroscopic grasper (Figure 6). If a labral tear is identified, the humeral avulsion of the glenohumeral ligaments lesion is repaired first and then the labral tear is addressed. This avoids over-tightening of the capsule medially, which may prevent or impair lateral repair. In order to prepare the bony bed, the original humeral insertion site of the inferior glenohumeral ligament complex is gently debrided using a burr on reverse from the anterior mid-glenoid portal to complete a light decortication and obtain

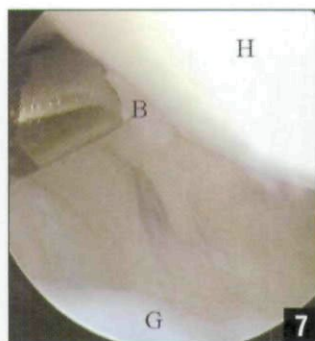


Figure 7: Arthroscopic view of right shoulder from posterior portal with 70° scope. The guide is passed after the spinal needle in order to enter the joint at the correct trajectory. Abbreviations: B, bone bed for repair; G, glenoid; H, humeral head.

a bleeding surface.²⁴ The labral (Bankart) repair is completed in standard fashion using glenoid suture anchors if a concomitant labral tear exists. Care must be taken not to overtension the capsulolabral repair so there is sufficient tissue left to anchor the capsule to the humeral neck avulsion site.

An 18-gauge needle is used under direct visualization to establish the correct path for suture anchor placement onto the medial humeral neck. The approximate placement of this path is between the standard posterior portal and the accessory posterolateral portal (7 o'clock) (Figure 4). This is obtained in a percutaneous fashion with the anchor inserting device and drill.

Once the appropriate path is established, a 3.0-mm bio-absorbable suture anchor is placed (Figure 7). One of the suture limbs is retrieved with a crochet hook out the anterosuperior portal. The remaining suture limb is left posteriorly outside the skin. A straight suture repair device

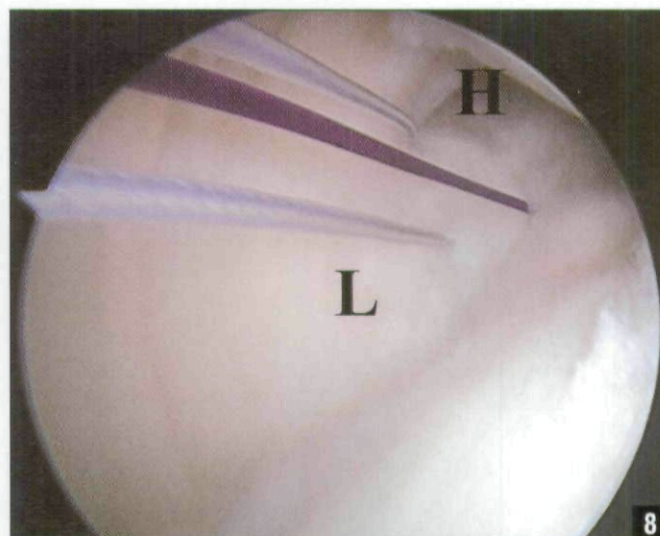


Figure 8: Arthroscopic view of left shoulder from posterior portal using 70° scope. When the sutures were brought up through the anterior portal, the glenohumeral ligament complex was anatomically reduced onto the anterior aspect of the humeral head. Abbreviations: H, humeral head; L, glenohumeral ligament complex.

is advanced through the 8.25-mm cannula in the 7-o'clock portal and passed through the inferior/lateral capsule just inside of the avulsion borders. A #1 monofilament suture is advanced into the joint through the suture repair device and retrieved through the anterosuperior portal. The monofilament is tied to the previously passed suture limb and shuttled back through the 7-o'clock portal through the capsuloligamentous complex. This can be repeated, and a mattress suture is then tied through the 7-o'clock portal with a knot pusher.

As the repair continues anteriorly, an accessory low anterior portal is required for correct anchor placement. This portal is created in a trans-subscapularis fashion, staying lateral to the humerus to minimize risk of axillary nerve injury. This portal can be used to place an anchor percutaneous-

ly, or a small 5-mm cannula can be used. It is important to use the rotation of the humerus to help control access to all areas of the humeral capsular avulsion site.

Once the anchor is in place, sutures are passed through the torn capsule in a similar fashion as described above using a corkscrew suture-passing device. The sutures are shuttled and brought out the anterior midlateral portal. In general, sutures are passed in a mattress fashion allowing the knot to be placed outside the capsule (Figure 8).

This repair can also be performed using a 3.5-mm or 4.5-mm pushlock (Arthrex Inc, Naples, Florida) to perform the fixation of the humeral avulsion of the glenohumeral ligaments lesion to the humeral head. This knotless and somewhat blind technique can be accomplished by visualizing the glenohumeral reduc-

tion arthroscopically. After the repair of the humeral avulsion of the glenohumeral ligaments lesion, examination under anesthesia is performed to verify firm anterior and antero-inferior glenohumeral stability.

POSTOPERATIVE MANAGEMENT

The arm is placed into a sling for approximately 4 weeks. During this time the patient is instructed to perform supine well-arm forward elevation to 90°, passive external rotation with arm at side to 30°, grip strength, and hand, wrist, and elbow range of motion exercises. Deltoid and rotator cuff isometrics are begun. From 4 to 8 weeks postoperatively, active and active-assisted forward elevation to 140° and external rotation with arm at side to 40° is begun, deltoid/rotator cuff isometrics are progressed, and scapular-stabilizing exercises are begun. Full, painless range of motion in all directions, gentle stretching at end range of motion, and progressive light resistance training is permitted 8 weeks postoperatively. Deltoid and rotator cuff exercises are progressed to isotonic. External rotation in 45° of abduction is started at 10 to 12 weeks postoperatively. A strengthening program is initiated after 3 months or when the patient has pain-free symmetric active range of motion, and this program is progressed as tolerated. After completing an isokinetic and functional test assessment, the patient may resume sporting activities.

DISCUSSION

Bokor et al⁷ reported on 41 humeral avulsion of the glenohumeral ligaments lesions and found the lesions to occur in a slightly older patient population, with the first-time dislocation being violent in nature. Also of importance in the article was the appearance of the humeral avulsion of the glenohumeral ligaments lesion arthroscopically. Not only can it expose the fibers of the subscapularis as proposed by Wolf et al,⁶ but the avulsion forms a "wave" by the reflection of the inferior capsule onto the humeral neck. Other authors have described a Bankart and a humeral avulsion of the glenohumeral ligaments combination lesion as a floating anterior band.^{9,10} Schippinger et al⁸ described the development of a humeral avulsion of the glenohumeral ligaments lesion occurring after successful arthroscopic Bankart repair and subsequent treatment of the humeral avulsion of the glenohumeral ligaments lesion. Chhabra et al²⁷ described a traumatic reverse humeral avulsion of the glenohumeral ligaments lesion in a patient with posterior instability involving the posterior band of the inferior glenohumeral ligament complex that was successfully repaired arthroscopically.

Operative treatment of the humeral avulsion of the glenohumeral ligaments lesion was first described by Bach et al,⁵ who reported 2 cases of disruption of the lateral capsule treated with subsequent open repair. Both patients had good

results after open repair of the lateral capsule avulsion injury back to the medial humeral neck. In reviewing a series of 547 shoulders, Bokor et al⁷ found 41 humeral avulsion of the glenohumeral ligaments lesions that were repaired using an open technique with either suture anchors or drill holes. Arciero and Mazzocca²² described a mini-open repair technique in 8 patients that spared the superior 50% of the subscapularis tendon and reported no recurrences of instability and a return to preoperative activity level in all patients.

Wolf et al⁶ were able to address 4 humeral avulsion of the glenohumeral ligaments lesions arthroscopically in 6 patients by tying sutures over the top of the subscapularis. Two patients in the report underwent open repair with sutures through drill holes. Richards and Burkhart²³ described 2 cases in which a humeral avulsion of the glenohumeral ligaments lesion was repaired arthroscopically with suture anchors, but no follow-up data was reported. Kon et al²⁴ were able to perform an all-arthroscopic repair of 3 humeral avulsion of the glenohumeral ligaments lesions with no recurrences and a return to preinjury activity level after 12 to 24 months of follow-up. Huberty and Burkhart²⁵ reported on 6 humeral avulsion of the glenohumeral ligaments lesions treated with an arthroscopic repair. At an average of 31.8 months of follow-up, no patients had sustained recurrent dislocations or subluxations,

and all patients were satisfied with the results of their operations.

KEY TECHNICAL POINTS

There are a number of key points in performing arthroscopic humeral avulsion of the glenohumeral ligaments repairs with suture anchor fixation. A thorough arthroscopic examination must be performed. It is important to assess the anterior labrum for a Bankart lesion or an anterior labroligamentous periosteal sleeve avulsion lesion. The middle and inferior glenohumeral ligament complexes must be examined for evidence of concomitant capsular redundancy. The glenohumeral ligaments need to be assessed at their humeral attachment. To check the humeral bony insertion of the middle and inferior glenohumeral ligament complexes, a 70° arthroscope may be required. The expanded field of view obtainable by the 70° arthroscope will assist in both the diagnosis of the injury and its repair.²³

The ability to establish a 7-o'clock portal is a key component of this case, and for all of our instability cases. Davidson and Rivenburgh²⁶ critically evaluated this portal in a cadaver study. The distance from the portal to the axillary nerve and the suprascapular nerve was 39 ± 4 mm and 29 ± 3 mm, respectively. The position of the arm had no effect on the distance from each nerve. Eakin et al²⁸ showed in an anatomic study that the mean distance to the axillary nerve in inferior and posteroinferior

suture positions was 14.4 mm and 24.1 mm, respectively. Difelice et al²⁹ evaluated this accessory posterior portal in a cadaveric study and found the distance from the portal to the axillary nerve and the suprascapular nerve was 34 ± 5 mm and 29 ± 3 mm, respectively. The position of the arm had no effect on the distance from each nerve.

Another key component of an all-arthroscopic repair is obtaining the correct angle of approach for placement of suture anchors into the humerus. This oblique angle has been referred to as "the killer angle" by Huberty and Burkhart.²⁵ This angle can only be achieved by using a 5-o'clock portal and placing the arm in abduction and external rotation. The arm has to be held in this position for preparation of the bone bed and placement of anchors. Finally, after passing the suture, the ligaments must be visually confirmed to be reduced back to the proximal humerus (Figure 8). They must be maintained in this position as the arthroscopic knots are tied.²³

CONCLUSION

A humeral avulsion of the glenohumeral ligaments injury of the shoulder is a relatively rare condition that is associated with instability conditions. Arthroscopy has allowed for improvement in recognition of humeral avulsion of the glenohumeral ligaments injuries, and both open and arthroscopic techniques have yielded excel-

lent results. The arthroscopic treatment of a humeral avulsion of the glenohumeral ligaments lesion, although technically demanding, allows for a safe, reproducible, and effective way to reestablish the inferior glenohumeral ligament and capsular complex to the humerus. To fully evaluate the efficacy of this procedure, a series of patients with long-term follow-up will be required. ■

REFERENCES

- Bankart ASB. Recurrent or habitual dislocation of the shoulder-joint. *British Medical Journal*. 1923; 2:1132-1133.
- Bankart ASB. Pathology and treatment of recurrent dislocation of shoulder-joint. *Br J Surg*. 1938; 26:23-29.
- Rowe CR, Patel D, Southmayd WW. The Bankart procedure: a long-term end-result study. *J Bone Joint Surg Am*. 1978; 60(1):1-16.
- Rowe CR, Zarins B, Ciuillo JV. Recurrent anterior dislocation of the shoulder after surgical repair. Apparent causes of failure and treatment. *J Bone Joint Surg Am*. 1984; 66(2):159-168.
- Bach BR, Warren RF, Fronek J. Disruption of the lateral capsule of the shoulder. *J Bone Joint Surg Br*. 1988; 70(2):274-276.
- Wolf EM, Cheng JC, Dickson K. Humeral avulsion of the glenohumeral ligaments as a cause of anterior shoulder instability. *Arthroscopy*. 1995; 11(5):600-607.
- Bokor DJ, Conboy VB, Olson C. Anterior instability of the glenohumeral joint with humeral avulsion of the glenohumeral ligament. A review of 41 cases. *J Bone Joint Surg Br*. 1999; 81(1):93-96.
- Schippinger G, Vasiliu PS, Fankhauser F, Clement HG. HAGL lesion occurring after successful arthroscopic Bankart repair. *Arthroscopy*. 2001; 17(2):206-208.
- Field LD, Bokor DJ, Savoie FH III. Humeral and glenoid detachment of the anterior inferior glenohumeral ligament: a cause of anterior shoulder instability. *J Shoulder Elbow Surg*. 1997; 6(1):6-10.
- Warner JJ, Beim GM. Combined Bankart and HAGL lesion associated with anterior shoulder instability. *Arthroscopy*. 1997; 13(6):749-752.
- Pouliart N, Gagey O. Reconciling arthroscopic and anatomic morphology of the humeral insertion of the inferior glenohumeral ligament. *Arthroscopy*. 2005; 21(8):979-984.
- Coates MH, Breidahl W. Humeral avulsion of the anterior band of the inferior glenohumeral ligament with associated subscapularis bony avulsion in skeletally immature patients. *Skeletal Radiol*. 2001; 30(12):661-666.
- Gehrmann RM, DeLuca PF, Bartolozzi AR. Humeral avulsion of the glenohumeral ligament caused by microtrauma to the anterior capsule in an overhead throwing athlete: a case report. *Am J Sports Med*. 2003; 31(4):617-619.
- Nicola T. Anterior dislocation of the shoulder: the role of the articular capsule. *J Bone Joint Surg Am*. 1942; 25:614-616.
- Bigliani LU, Pollock RG, Soslowsky LJ, et al. Tensile properties of the inferior glenohumeral ligament. *J Orthop Res*. 1992; 10(2):187-197.
- Gagey O, Gagey N, Boisrenoult P, Hue E, Mazas F. Experimental study of dislocations of the scapulohumeral joint [in French]. *Rev Chir Orthop Reparatrice Appar Mot*. 1993; 79(1):13-21.
- Ciccone WJ II, Hunt TJ, Lieber R, et al. Multiquadrant digital analysis of shoulder capsular thickness. *Arthroscopy*. 2000; 16(5):457-461.
- Pouliart N, Gagey O. Simulated humeral avulsion of the glenohumeral ligaments: a new instability model. *J Shoulder Elbow Surg*. 2006; 15(6):728-735.
- Stoller DW, Wolf EM. The shoulder. In: Stoller DW, ed. *Magnetic Resonance Imaging in Orthopaedics and Sports Medicine*. 2nd ed. Philadelphia, PA: JB Lippincott; 1997:597-748.
- Bui-Mansfield LT, Taylor DC, Uhorchak JM, Tenuta JJ. Humeral avulsions of the glenohumeral ligament: imaging features and a review of the literature. *AJR Am J Roentgenol*. 2002; 179(3):649-655.
- Spang JT, Karas SG. The HAGL lesion: an arthroscopic technique for repair of humeral avulsion of the glenohumeral ligaments. *Arthroscopy*. 2005; 21(4):498-502.
- Arciero RA, Mazzocca AD. Mini-open repair technique of HAGL (humeral avulsion of the glenohumeral ligament) lesion. *Arthroscopy*. 2005; 21(9):1152.
- Richards DP, Burkhart SS. Arthroscopic humeral avulsion of the glenohumeral ligaments (HAGL) repair. *Arthroscopy*. 2004; 20(suppl 2):134-141.
- Kon Y, Shiozaki H, Sugaya H. Arthroscopic repair of a humeral avulsion of the glenohumeral ligament lesion. *Arthroscopy*. 2005; 21(5):632.
- Huberty DP, Burkhart SS. Arthroscopic repair of anterior humeral avulsion of the glenohumeral ligaments. *Techniques in Shoulder & Elbow Surgery*. 2006; 7(4):186-190.
- Davidson PA, Rivenburgh DW. The 7-o'clock posteroinferior portal for shoulder arthroscopy. *Am J Sports Med*. 2002; 30(5):693-696.
- Chhabra A, Diduch DR, Anderson M. Arthroscopic repair of a posterior humeral avulsion of the inferior glenohumeral ligament (HAGL) lesion. *Arthroscopy*. 2004; 20(suppl 2):73-76.
- Eakin C, Dvirnak P, Miller CM, Hawkins RJ. The relationship of the axillary nerve to arthroscopically placed capsulolabral sutures. An anatomic study. *Am J Sports Med*. 1998; 26(4):505-509.
- Difelice GS, Williams RJ III, Cohen MS, Warren RF. The accessory posterior portal for shoulder arthroscopy: Description of technique and cadaveric study. *Arthroscopy*. 2001; 17(8):888-891.

Copyright of Orthopedics is the property of SLACK Incorporated and its content may not be copied or emailed to multiple sites or posted to a listserv without the copyright holder's express written permission. However, users may print, download, or email articles for individual use.