



The high failure rate of biologic resurfacing of the glenoid in young patients with glenohumeral arthritis

Eric J. Strauss, MD^{a,*}, Nikhil N. Verma, MD^b, Michael J. Salata, MD^c,
Kevin C. McGill, BA, MPH^a, Christopher Klifto, MD^a, Gregory P. Nicholson, MD^a,
Brian J. Cole, MD^a, Anthony A. Romeo, MD^a

^aNew York University Hospital for Joint Diseases, New York, NY, USA

^bMidwest Orthopaedics at Rush University Medical Center, Chicago, IL, USA

^cUniversity Hospital, Case Medical Center, Cleveland, OH, USA

Background: The current study evaluated the outcomes of biologic resurfacing of the glenoid using a lateral meniscus allograft or human acellular dermal tissue matrix at intermediate-term follow-up.

Methods: Forty-five patients (mean age, 42.2 years) underwent biologic resurfacing of the glenoid, and 41 were available for follow-up at a mean of 2.8 years. Lateral meniscal allograft resurfacing was used in 31 patients and human acellular dermal tissue matrix interposition in 10.

Postoperative range of motion and clinical outcomes were assessed at the final follow-up.

Results: The overall clinical failure rate was 51.2%. The lateral meniscal allograft cohort had a failure rate of 45.2%, with a mean time to failure of 3.4 years. Human acellular dermal tissue matrix interposition had a failure rate of 70.0%, with a mean time to failure of 2.2 years.

Overall, significant improvements were seen compared with baseline with respect to the visual analog pain score (3.0 vs 6.3), American Shoulder and Elbow Surgeons score (62.0 vs 36.8), and Simple Shoulder Test score (7.0 vs 4.0). Significant improvements were seen for forward elevation (106° to 138°) and external rotation (31° to 51°).

Conclusion: Despite significant improvements compared with baseline values, biologic resurfacing of the glenoid resulted in a high rate of clinical failure at intermediate follow-up. Our results suggest that biologic resurfacing of the glenoid may have a minimal and as yet undefined role in the management of glenohumeral arthritis in the young active patient over more traditional methods of hemiarthroplasty or total shoulder arthroplasty.

Level of evidence: Level IV, Case Series, Treatment Study.

© 2014 Journal of Shoulder and Elbow Surgery Board of Trustees.

Keywords: Glenohumeral arthritis; biologic resurfacing; lateral meniscal allograft; Graftjacket

This retrospective review was approved the Rush University Medical Center Investigational Review Board (#S10-00424).

*Reprint requests: Eric J. Strauss, MD, Assistant Professor, Division of Sports Medicine Associate Residency Program, Director Department of Orthopaedic Surgery, NYU Hospital For Joint Diseases, 301 East 17th Street, Suite 1616, New York, NY 10003 646-501-7208.

E-mail address: eric.strauss@nyumc.org (E.J. Strauss).

Although total shoulder arthroplasty is becoming more common and has been reported as a reliable treatment for pain secondary to glenohumeral degenerative disease, results in younger patients have not been as favorable and concerns remain regarding early failure of the glenoid component.²¹ Humeral head replacement alone has been reported to

provide short-term pain relief and improved function, but studies with longer follow-up have demonstrated progressive joint space narrowing, glenoid erosion, and diminishing outcomes over time.^{12,15,17,19} For these reasons, alternative treatment methods have been investigated for young patients with symptomatic glenohumeral arthritis.

First proposed by Burkhead and Hutton in 1988,⁴ biologic resurfacing of the glenoid, combined with hemiarthroplasty, has been used in the treatment of glenohumeral arthritis in young patients, with variable results. In their initial series, interposition of soft tissue between the humeral head implant and the native glenoid provided pain relief and improvement in shoulder range of motion at 2 years of follow-up.

As experience with biologic glenoid resurfacing has increased, other interposition options have been used, including Achilles tendon allografts and, more recently, lateral meniscal allografts and processed tissue grafts such as human acellular dermal tissue matrix (Graftjacket regenerative tissue matrix; Wright Medical Technology, Arlington, TN, USA).^{1-6,13,16} Durability of biologic glenoid resurfacing was reported by Krishnan et al⁹ in their 2- to 15-year follow-up of 36 patients. Other studies, however, have reported contrasting results, with a rapid deterioration in postoperative functional outcome, return of pain, and a high rate of conversion to total shoulder arthroplasty.⁶

A short-term follow-up evaluation of 30 patients treated with lateral meniscal allograft resurfacing of the glenoid combined with hemiarthroplasty was published in 2007 from our institution.¹³ At a mean follow-up of 18 months, significant improvements were noted in American Shoulder and Elbow Surgeons (ASES) scores, Simple Shoulder Test (SST) scores, visual analog scale (VAS) pain scores, and shoulder range of motion parameters. Complications requiring revision surgery occurred in 5 patients (17%) within the first postoperative year; however, despite this incidence, 94% of study patients reported satisfaction with their clinical outcome and would have the procedure again if necessary. The current investigation re-evaluated these patients at intermediate-term follow-up, reporting their current clinical status and the incidence of failure of biologic resurfacing. The analysis also included a group of patients treated with human acellular dermal tissue matrix as their soft tissue interposition with a similar duration of follow-up. We hypothesized that the clinical outcomes seen in our short-term evaluation would diminish with longer-term follow-up, highlighted by a high incidence of revision surgery in patients treated with lateral meniscal allograft as well as those treated with human acellular dermal tissue matrix resurfacing of the glenoid.

Materials and methods

Between November 2001 and December 2008, 45 patients undergoing humeral head hemiarthroplasty or humeral head resurfacing (HemiCAP; Arthrosurface, Franklin, MA, USA) combined with biologic resurfacing of the glenoid for treatment of

Table I Preoperative etiologies

Diagnoses	Patients (No.)
Primary glenohumeral osteoarthritis	29
Post-traumatic arthrosis	7
Capsulorrhaphy arthropathy	7
Chondrolysis	1
Avascular necrosis of the humeral head	1

symptomatic degenerative joint disease of the glenohumeral joint were identified from our institutional database. All patients underwent the informed consent process. Four fellowship-trained orthopedic surgeons (B.C., G.N., A.R., N.V.) in shoulder surgery or sports medicine performed all surgical procedures.

Biologic resurfacing of the glenoid, combined with hemiarthroplasty or humeral head resurfacing, was indicated in these patients secondary to their relatively young age, symptomatic bipolar disease, and anticipation of return to overhead activities. The most common etiology treated was primary glenohumeral osteoarthritis in 29 patients (Table I). Patients in this cohort had failed nonoperative management before consideration for operative intervention. Of the 45 patients identified, 32 (71.1%) had undergone previous operative procedures on the affected shoulder, with a mean of 1.7 prior procedures performed per patient.

All study patients completed a preoperative assessment that included demographic and social history, detailed medical and surgical history, an ASES score, SST score, VAS pain score, and an evaluation of shoulder range of motion. For the VAS pain score, clearly defined anchors for the scale were used, including “no shoulder pain or discomfort with any and all activity” on one end and “constant, disabling pain” at the other end.

Operative technique: lateral meniscal allograft or human acellular dermal tissue matrix resurfacing

With the patient in the beach-chair position under a combination of regional interscalene anesthesia and general anesthesia, a deltopectoral approach was used. Biceps tenodesis was performed in all patients. Preparation of the humeral head was routinely performed first, providing adequate access to the glenoid. The glenoid labrum was left in situ to serve as an anchor for fixation of the lateral meniscal allograft or the human acellular dermal tissue matrix. Any remaining articular cartilage on the glenoid surface was removed with a curette. Concentric reaming was performed to create a concentric surface with punctate bleeding to allow for adhesion and healing of the interposed tissue to the native glenoid. Once reaming was complete, nonabsorbable sutures were placed through the labrum, allowing for 6 to 8 points of circumferential fixation to the glenoid. When necessary for supplemental graft fixation, suture anchors or transosseous sutures, or both, were inserted into the glenoid rim.

For lateral meniscal allograft resurfacing, a male lateral meniscus from a donor younger than 30 years was used to maximize glenoid surface coverage. The sutures from the labrum were then passed through the lateral meniscal allograft, orienting the graft so that the anterior and posterior horns faced anteriorly and the thickest portion of the graft covered the posterior portion of the glenoid. The horns were sutured together to provide stability during peripheral fixation. Each circumferential suture

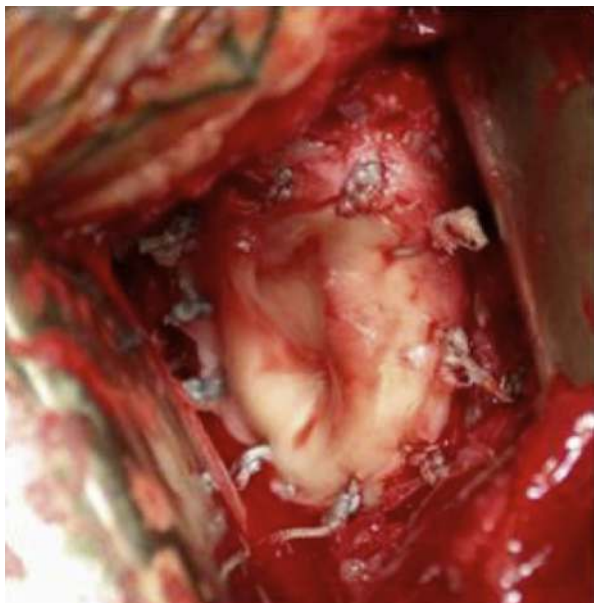

Figure 1 Biologic resurfacing using a lateral meniscal allograft in a 30-year-old right hand-dominant man with a diagnosis of primary glenohumeral arthritis.

was then tied, with suturing of the 2 horns of the meniscal allograft performed last to allow for stability and sizing adjustment as needed (Fig. 1). Once the lateral meniscal allograft was placed, the humerus was carefully dislocated anteriorly and the hemiarthroplasty (38 patients) or the HemiCAP humeral head resurfacing implant (7 patients) was performed. The shoulder was then reduced, and the subscapularis was anatomically repaired.

When human acellular dermal tissue matrix resurfacing was performed, preparation and implantation of the humeral head hemiarthroplasty or resurfacing was completed before approaching the glenoid. Once the hemiarthroplasty or HemiCAP was implanted, the shoulder was reduced, allowing for an evaluation of the implant's conformity with the patient's native articular surface. Retractors were then inserted, allowing the humeral head implant to be displaced posteriorly and providing a straight on approach to the glenoid. After preparation of the glenoid, the thickest available human acellular dermal tissue matrix (0.8 mm thick) was cut to the appropriate size and shape and secured to the glenoid by individually passing the sutures from the labrum through the edges of the material. This sequential suture passage and tying allowed for tensioning of the human acellular dermal tissue matrix over the glenoid surface. The shoulder was then reduced, allowing for assessment of glenohumeral range of motion and stability, and the subscapularis was anatomically repaired.

Postoperative care

Postoperative management and rehabilitation was the same for patients treated with both types of biologic glenoid resurfacing; however, the postoperative protocols did vary between the operating surgeons. One of the senior authors (G.N.) immobilized the operative shoulder in a sling, with a derotation wedge attached, for 2 weeks. Pendulum exercises were started at 2 weeks, and active-assisted range of motion and isometrics were begun at 4 weeks. The other senior authors (B.C., A.R., and N.V.) immobilized the

operative shoulder for 6 weeks, allowing pendulum exercises and passive shoulder range of motion in the immediate postoperative period. At 6 weeks postoperatively, patients started active-assisted range of motion and isometric exercises. At 8 weeks, all patients were performing active range of motion and resistive strengthening exercises.

Follow-up evaluation

Patients were invited for a postoperative evaluation, and each patient was assessed by an independent observer blinded to their preoperative clinical status and the operative procedure. Each patient completed an outcome survey, allowing for calculation of a postoperative ASES score, SST score, and VAS pain score. Similar to the preoperative assessment, clearly defined anchors for the VAS pain scale were used, including "no shoulder pain or discomfort with any and all activity" on one end and "constant, disabling pain" at the other extreme.

Patients returning to the office for follow-up evaluation underwent a physical examination, including an assessment of glenohumeral range of motion and radiographic imaging. Forward elevation in the scapular plane and external rotation with the arm at the side were measured using a goniometer. The extent of remaining glenohumeral joint space was measured radiographically using true anteroposterior and axillary views with a 4-mm marker affixed to the skin on the lateral deltoid at the level of the glenohumeral joint. With the marker serving as a known size reference, digital measurements in millimeters were recorded for the remaining joint space on both views. Patients who were unable to return to the office for follow-up were contacted by telephone and interviewed using the outcome survey. When possible, copies of their most recent x-ray images were obtained and assessed.

In our evaluation of the outcomes after biologic resurfacing of the glenoid, failure of the procedure was defined as (1) conversion to a total shoulder arthroplasty or reverse total shoulder arthroplasty, (2) recommendation of conversion to a total shoulder arthroplasty or reverse total shoulder arthroplasty by the treating surgeon, (3) revision surgery for graft removal, or (4) patient-reported disabling pain (VAS ≥ 8) or loss of function, or (5) postoperative ASES score of less than 50 points, or both.

Data analysis

Descriptive analysis of collected data was performed using statistical software. Means and standard deviations were calculated for each study variable. Paired *t* tests were used to compare preoperative and follow-up measures, including range of motion, ASES scores, SST scores, and VAS scores. Our data were used to generate Kaplan-Meier survival curves to demonstrate the cumulative probability of failure after biologic resurfacing of the glenoid over time. For our statistical analysis, a *P* value of $< .05$ was set as the level of significance.

Results

Between November 2001 and December 2008, 45 patients underwent hemiarthroplasty (38 patients) or humeral head resurfacing (7 patients) combined with biologic resurfacing of the glenoid for treatment of symptomatic glenohumeral

arthritis. At a mean follow-up of 2.8 years (range, 0.7-8.2 years), outcome data were available for 41 patients (91.1%). Of these, 33 patients (73%) completed a follow-up survey and underwent a physical examination, and 8 (18%) were contacted by telephone for the follow-up evaluation. Two of the remaining 4 patients had moved out of state, and 2 were unwilling to return for a follow-up evaluation. There were 30 men and 11 women, with a mean age of 42.2 years (range, 18.1-60.2 years). The dominant extremity was involved in 24 patients (58.5%).

Resurfacing of the glenoid was performed using a lateral meniscal allograft in 31 patients and a human acellular dermal tissue matrix in 10. At the time of surgery, 9 patients (22%) underwent additional procedures, including capsulorrhaphy (4 patients), removal of hardware (3 patients), bone grafting of the glenoid (1 patient), and a Latarjet procedure (1 patient).

At this intermediate follow-up assessment, the overall clinical failure rate was 51.2% (21 of 41 patients). Patients receiving a lateral meniscal allograft interposition had a failure rate of 45.2%, with a mean time to failure of 3.4 years. Those treated with a human acellular dermal tissue matrix interposition had a failure rate of 70.0%, with a mean time to failure of 2.2 years (Fig. 2). There were 8 patients who required conversion to total shoulder arthroplasty or reverse total shoulder arthroplasty, 5 had been recommended for conversion, 5 had an ASES score of less than 50, 2 reported disabling pain and loss of function, and 1 required graft removal secondary to infection. Of the 8 conversions to arthroplasty, 7 patients underwent total shoulder arthroplasty, and 1 underwent a reverse total shoulder arthroplasty.

In the overall patient cohort at the time of most recent follow-up, the mean ASES score significantly improved from the preoperative baseline (62.0 vs 36.8; $P < .05$). The SST score significantly improved from 4.0 to 7.0 ($P < .05$), and the mean VAS pain score significantly decreased from 6.3 preoperatively to 3.0 ($P < .05$; Fig. 3). Glenohumeral forward flexion and external rotation improved from 106° and 31° to 138° and 51°, respectively ($P < .05$ for both comparisons; Fig. 3).

Follow-up radiographs at the time of final follow-up were available for 35 of the 41 patients (85.4%) in the study cohort. Glenohumeral joint space on the anteroposterior and axillary radiographs measured means of 0.54 and 0.35 mm, respectively, which were significant declines compared with the initial follow-up x-ray images that demonstrated means of 1.3 and 0.8 mm, respectively ($P < .05$ for both comparisons; Fig. 4).

Among the 21 patients classified as failures of biologic resurfacing, the mean ASES score significantly improved from baseline (40.4 vs 24.3; $P < .05$). An improvement in mean SST score was also seen, with an increase from 1.8 to 3.9 ($P < .05$). The mean VAS pain score significantly decreased from 7.3 preoperatively to 5.1 postoperatively ($P < .05$; Fig. 5). Mean glenohumeral forward flexion

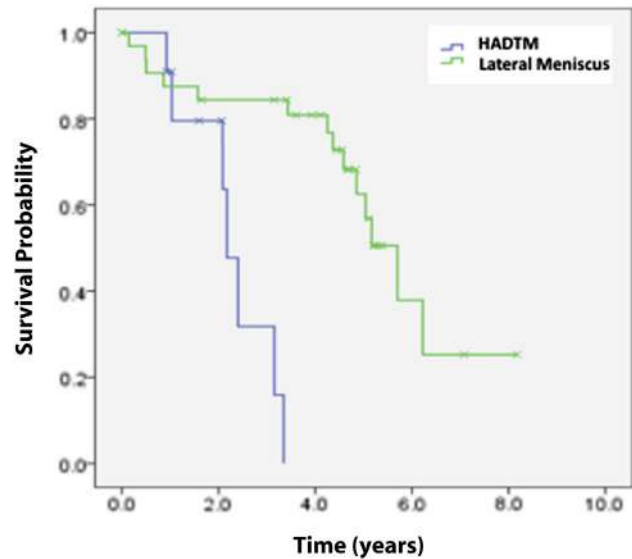


Figure 2 Generated survival curves demonstrate rapid drop-off in survival of repair between 2 and 5 years after biologic resurfacing of the glenoid. HADTM, human acellular dermal tissue matrix.

increased from 107° to 122° ($P = .30$) and external rotation from 30° to 41° ($P = .07$; Fig. 5).

In the 20 patients who did not meet criteria for failure after biologic resurfacing of the glenoid, the mean ASES scores increased from 46.1 to 84.9 ($P < .05$), and mean SST scores increased from 5.6 to 10.4 ($P < .05$). There was also an improvement in the mean VAS pain score from a preoperative value of 5.6 to 0.8 postoperatively ($P < .05$; Fig. 4). In those patients whose resurfacing survived to the most recent follow-up, mean glenohumeral forward flexion increased from 106° to 154° and external rotation from 31° to 61° ($P < .05$ for both comparisons; Fig. 6).

Evaluation and comparison of outcomes between patients who had undergone prior surgical procedures and those in whom biologic resurfacing was used as a primary treatment method showed that among patients with no prior surgery, the mean ASES score improved from 24.7 to 48.1 ($P = .07$), the mean SST score improved from 1.3 to 4.7 ($P = .11$), and the mean VAS pain score improved from 6.7 to 4.3 ($P = .09$). In patients with prior surgery, the mean ASES score improved from 40.1 to 69.9 ($P < .05$), the mean SST score improved from 4.7 to 8.3 ($P < .05$), and the mean VAS pain score improved from 6.2 to 2.2 ($P < .05$). Comparison of the 2 groups demonstrated that the patients with no prior surgical history started off with worse symptoms and function than those who had undergone prior procedures on the affected shoulder. The differences in the preoperative ASES score and VAS pain score did not reach significance ($P = .06$ and $P = .57$, respectively), but the patients in whom biologic resurfacing was used as a primary treatment had significantly worse SST scores ($P < .05$). Significant differences were noted in the postoperative ASES, SST, and VAS pain scores between

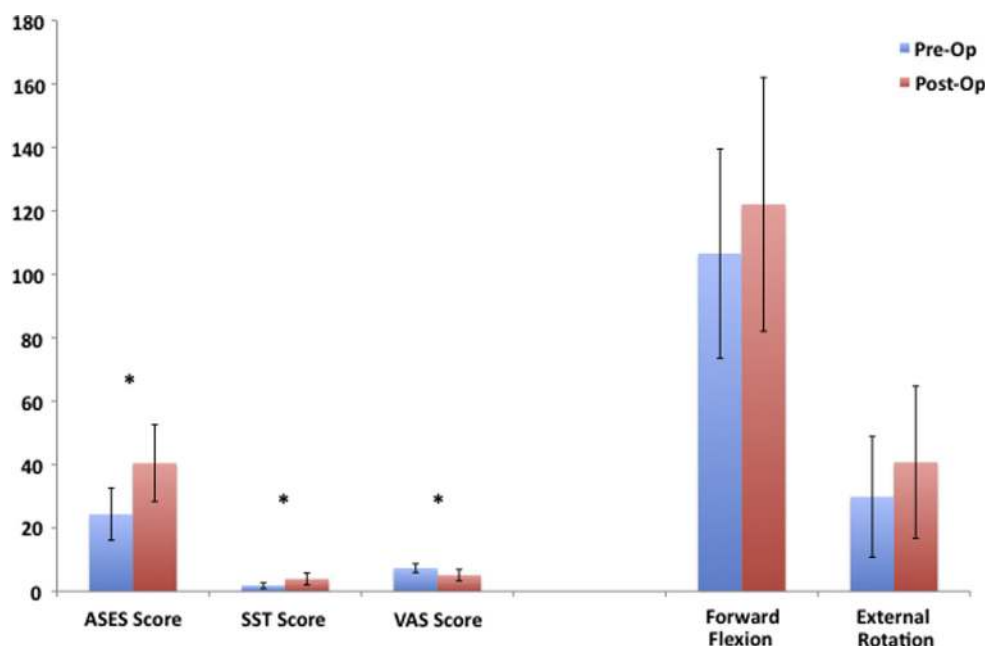


Figure 3 Small but significant improvements in clinical outcome scores and active glenohumeral range of motion parameters were seen after biologic resurfacing of the glenoid in the overall patient cohort. The *error bars* show the standard deviation. * $P < .05$. ASES, American Shoulder and Elbow Surgeons; SST, Simple Shoulder Test; VAS, visual analog scale.

the 2 patient groups ($P < .05$ for all 3 comparisons). Although significant differences were noted in forward flexion and external rotation for patients in the prior surgery group between baseline and final follow-up ($P < .05$ for both comparisons), nonsignificant improvements were seen with respect to these parameters in the patients without prior surgery ($P = .39$ and $P = .11$, respectively). No significant difference was found in comparing these parameters between the 2 groups (Fig. 7, A and B).

An additional subset analysis demonstrated significant improvements compared with baseline in the lateral meniscal allograft treatment group, but no significant difference in outcomes between those treated with lateral meniscal allograft resurfacing and those treated with human acellular dermal tissue interposition (Fig. 8, A and B).

Reoperation was required for 4 postoperative complications (9.8%). Two patients developed significant loss of active shoulder range of motion requiring arthroscopic capsular release. One displacement of the lateral meniscal allograft resurfacing occurred after a minor traumatic event. Secondary to the development of significant pain and limited shoulder function, the allograft was removed and the patient converted to total shoulder arthroplasty. One deep infection developed, requiring irrigation, debridement, and removal of the lateral meniscal allograft.

Discussion

Data from this intermediate-term follow-up of our cohort treated with biologic resurfacing of the glenoid combined

with hemiarthroplasty or humeral head resurfacing demonstrated an unacceptable failure rate of 51.2% at a mean of 2.8 years of follow-up. Patients treated with lateral meniscal allograft resurfacing or placement of a human acellular dermal tissue matrix over the glenoid that failed had persistent pain and poor function postoperatively, leading to a conversion to a total shoulder arthroplasty or reverse total shoulder arthroplasty, recommendation for conversion, or poor outcome scores on follow-up evaluation. Patients with human acellular dermal tissue matrix resurfacing patients fared worse than those treated with lateral meniscal allograft interposition, with a failure rate of 70% compared with 45.2%. Patients in whom biologic resurfacing of the glenoid was used as a primary treatment method had lower preoperative baseline scores but had worse clinical outcomes than those who had undergone prior surgical procedures on their affected shoulder. Interestingly, despite the high rates of clinical failure, outcome scores after biologic resurfacing of the glenoid showed significant improvements in mean shoulder range of motion, VAS pain score, ASES score, and SST score compared with baseline preoperative values. However, it is important to note that although improvement was seen compared with baseline clinical values, the overall outcome scores from each outcome assessment system were fair at best, indicating persistent symptoms and limited shoulder function.

The appropriate management of young, active patients with symptomatic glenohumeral arthritis continues to be debated in the orthopedic surgery literature. For appropriately selected patients, total shoulder arthroplasty decreases pain and improves shoulder function.^{8,14} In a recent

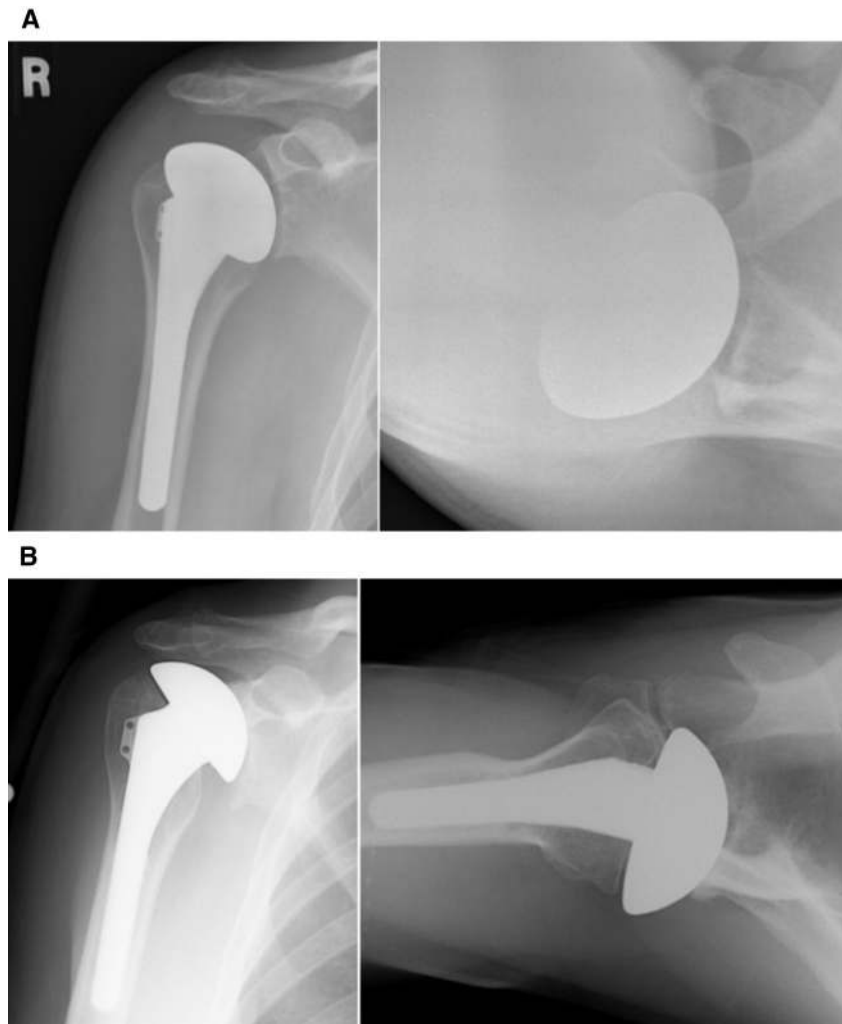


Figure 4 (A) Preoperative and (B) postoperative anteroposterior (*left*) and axillary (*right*) radiographs demonstrate a reduction in glenohumeral joint space 3 years after biologic resurfacing of the glenoid using a lateral meniscal allograft coupled with a hemiarthroplasty.

meta-analysis comparing total shoulder arthroplasty with humeral head replacement for treatment of primary glenohumeral osteoarthritis, Radnay et al¹⁸ reported that total shoulder arthroplasty resulted in significantly better pain relief, postoperative range of motion, and patient satisfaction, with a lower revision rate compared with hemiarthroplasty. However, the longevity of a total shoulder arthroplasty in younger, active patients has been questioned secondary to increased rates of glenoid component failure reported in a number of clinical studies.²³⁻²⁵ In an effort to avoid the likely need for revision surgery secondary to failure of the glenoid component and poorer outcomes in this patient population, alternative treatment methods to total shoulder arthroplasty have been investigated.

Humeral head hemiarthroplasty alone has been reported to provide short-term pain relief and improved function, but studies with longer follow-up have demonstrated progressive joint space narrowing, glenoid erosion, and diminishing outcomes.^{12,15,17,19} In a retrospective review of 78 hemiarthroplasties performed in patients aged younger

than 50 years, Sperling et al²² reported that at 15 years of follow-up, the procedure had unsatisfactory results in 45% of their patients. Radiographic analysis demonstrated significant glenoid erosions in 68% of patients after hemiarthroplasty. Survival estimates performed on data from this cohort found that 92% of the hemiarthroplasties survived to 5 years, 83% to 10 years, and 73% to 15 years. The authors concluded from their findings that care should be exercised when hemiarthroplasty is offered to patients who are 50 years old or younger.

To improve the results seen after hemiarthroplasty, biologic resurfacing of the glenoid through soft tissue interposition was revisited in 1988 by Burkhead and Hutton.⁴ During a 3-year period, 14 patients were treated with humeral head hemiarthroplasty coupled with biologic resurfacing of the glenoid using autogenous fascia lata or anterior shoulder capsule. Among the 6 patients with a minimum of 2 years of follow-up, the authors reported a reduction in pain in all patients, coupled with improvements in glenohumeral range of motion. Longer-term follow-up was reported by

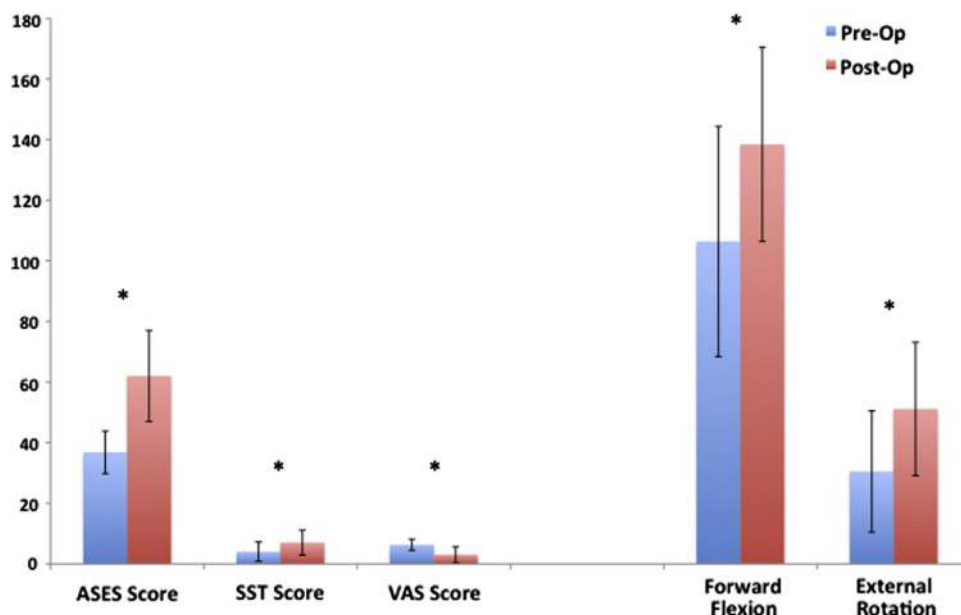


Figure 5 Marginal but significant improvements in clinical outcome scores were seen among the 21 clinical failures after biologic resurfacing of the glenoid. No significant change in active glenohumeral range of motion parameters was noted. The *error bars* show the standard deviation. * $P < .05$. ASES, American Shoulder and Elbow Surgeons; SST, Simple Shoulder Test; VAS, visual analog scale.

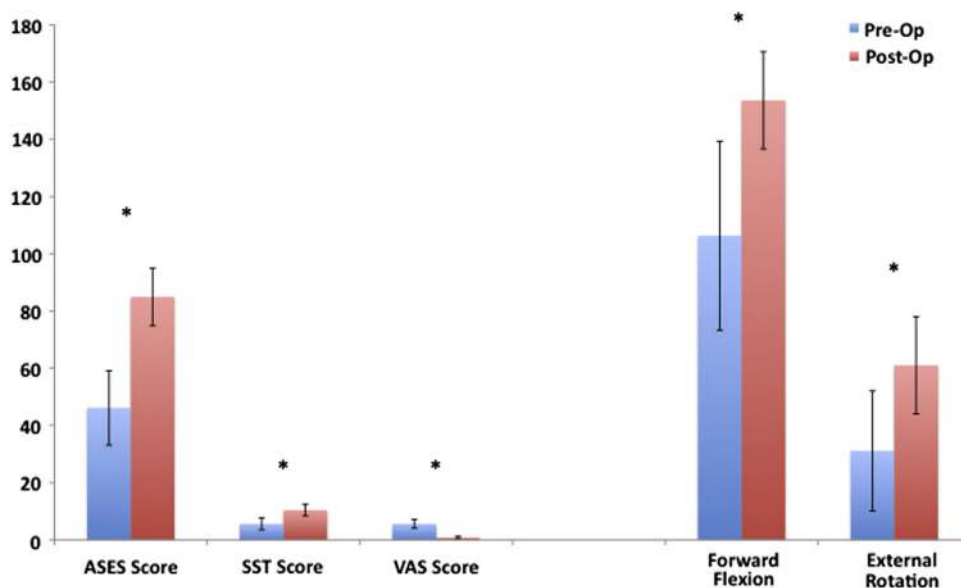


Figure 6 More substantial improvements in clinical outcomes and glenohumeral range of motion were seen among the 20 patients who did not meet criteria for failure after biologic resurfacing of the glenoid. The *error bars* show the standard deviation. * $P < .05$. ASES, American Shoulder and Elbow Surgeons; SST, Simple Shoulder Test; VAS, visual analog scale.

Krishnan et al¹⁰ in their retrospective evaluation of 36 shoulders in 34 patients treated during a 15-year period. At a mean follow-up of 7 years, the authors reported an improvement in the ASES score from 39 preoperatively to 91 at the most recent evaluation. According to the Neer criteria, good to excellent results were seen in 86% of their patients. Radiographic evaluation of this cohort demonstrated a mean 7.2 mm of glenoid erosion over the postoperative observation period, which appeared to stabilize at 5 years. Significantly

worse outcomes after biologic resurfacing were reported by Elhassan et al⁶ in their retrospective review of 13 patients aged younger than 50 years treated with hemiarthroplasty combined with soft tissue interposition with Achilles tendon allograft, autogenous fascia lata, or anterior shoulder capsule. Of these 13 patients, 10 required conversion to total shoulder arthroplasty at a mean of 14 months postprocedure (range, 6-34 months). Combined with 2 patients who developed postoperative infections, the authors reported

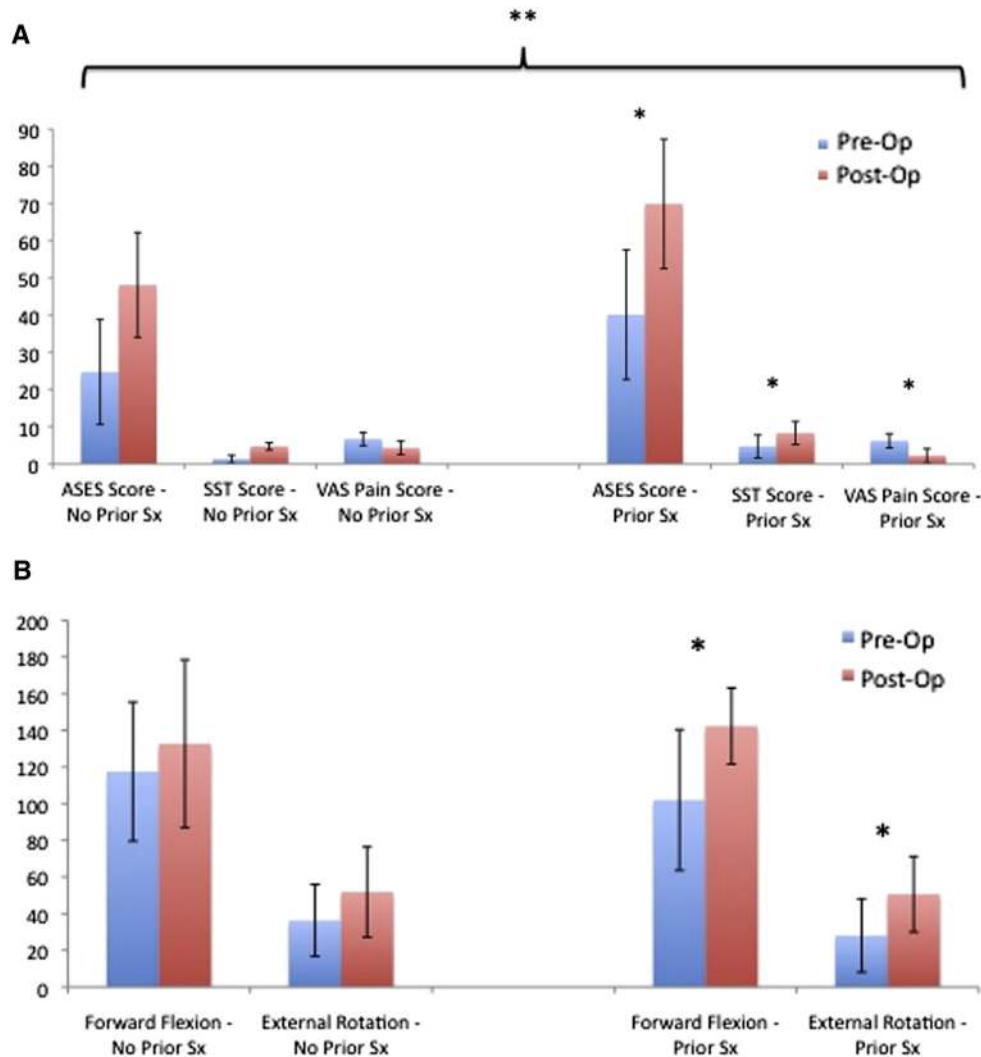


Figure 7 (A) Patients who had undergone prior surgery on the affected shoulder had significantly better outcome scores than those in whom biologic resurfacing was used as a primary treatment method. Of note, patients with no prior surgery had significantly lower preoperative baseline scores. The *error bars* show the standard deviation. ASES, American Shoulder and Elbow Surgeons; SST, Simple Shoulder Test; VAS, visual analog scale. * $P < .05$. ** Significant difference between postoperative scores in patients who had prior surgery compared with those who had no prior surgery. (B) No significant difference was seen with respect to post-operative range of motion parameters between patients with and without prior surgery on the affected shoulder, while those who had undergone prior surgery had significant improvements in their forward flexion and external rotation compared to their pre-operative baseline. The *error bars* show the standard deviation. * $P < .05$.

a 92.3% failure rate. The authors concluded from their findings that soft tissue resurfacing of the glenoid combined with humeral head arthroplasty is unreliable as a treatment for glenohumeral arthritis in young, active patients. More recently, Lee et al¹¹ reported their experience with biologic resurfacing of the glenoid using lateral meniscal allograft interposition. Among their 19 treated patients monitored for a mean of 4.25 years, poor clinical outcomes and a complication rate of 32%, all requiring revision surgery, led the authors to conclude that glenoid resurfacing using a meniscal allograft produced inconsistent results with a high incidence of complications.

The use of human acellular dermal tissue matrix as an interposition resurfacing of the glenoid was reported in a clinical series of 6 patients with a mean age of 47 years by

Huijsmans et al.⁷ At 6 months of follow-up, the authors reported preliminary improvement, with overall good results. Savoie et al²⁰ recently reported outcomes after arthroscopic glenoid resurfacing using the Restore biologic patch (DePuy Orthopaedics, Warsaw, IN, USA) in 23 consecutive patients with a mean age of 32 years (range, 15-58 years) treated for severe glenohumeral arthritis. At 3 to 6 years of follow-up, 75% of patients remained satisfied with their operative results. Significant improvements were reported with respect to ASES score, University of California, Los Angeles Shoulder Rating Scale score, Rowe score, and Constant-Murley score. Five patients required conversion to arthroplasty during the follow-up period; however, 4 of the 5 reported that they would undergo the arthroscopic resurfacing again if necessary.

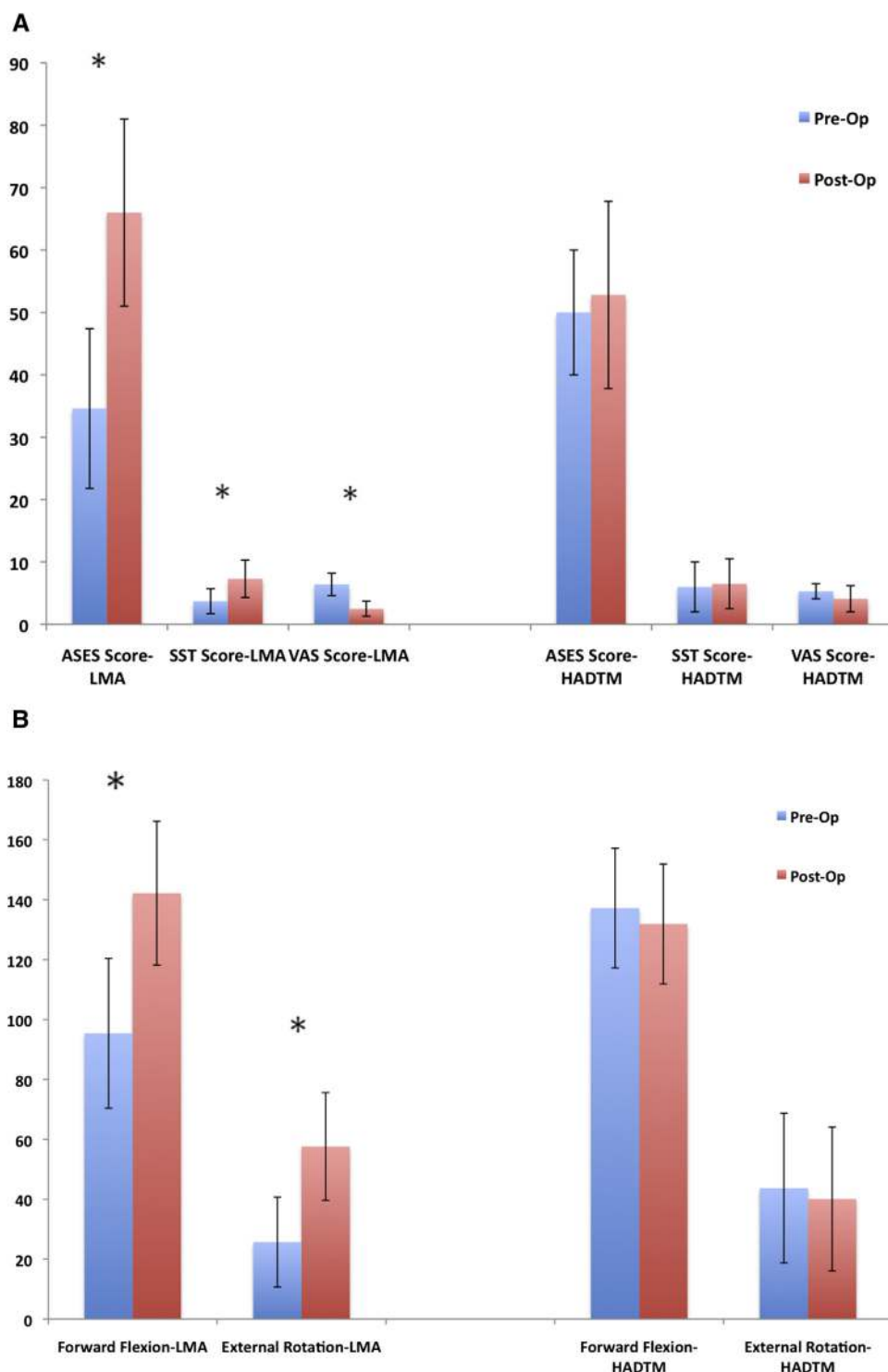


Figure 8 (A) Subset analysis demonstrated no significant difference in clinical outcome in patients after lateral meniscal allograft (*LMA*) resurfacing compared with those treated with human acellular dermal tissue matrix (*HADTM*). The *error bars* show the standard deviation. **P* < .05. *ASES*, American Shoulder and Elbow Surgeons; *SST*, Simple Shoulder Test; *VAS*, visual analog scale. (B) No significant difference was noted between active glenohumeral range of motion between patients treated with lateral meniscal allograft (*LMA*) resurfacing compared with those treated with human acellular dermal tissue matrix (*HADTM*). The *error bars* show the standard deviation. **P* < .05.

Although our results appear to be better than those reported by Elhassan et al,⁶ they are worse than the outcomes published by other authors. We believe that

a clinical failure rate of greater than 50% due to persistent pain and functional limitation after biologic resurfacing is unacceptable in this young, active patient population. The

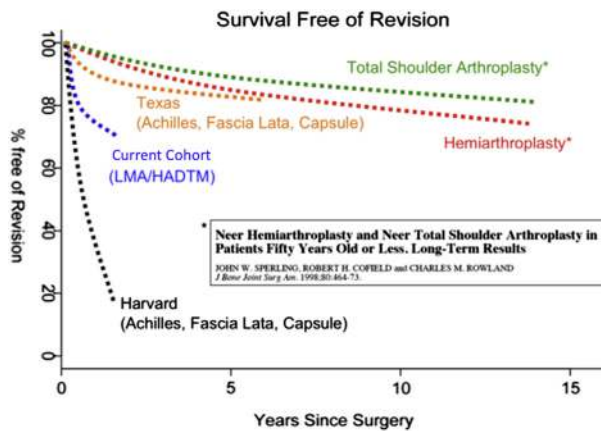


Figure 9 Variable outcomes of biologic resurfacing of the glenoid reported in the orthopedic surgery literature compared with the long-term outcomes of hemiarthroplasty and total shoulder arthroplasty reported by Sperling et al²² in their cohort of patients younger than 50 with symptomatic glenohumeral arthritis. *HADTM*, human acellular dermal tissue matrix; *LMA*, lateral meniscal allograft.

patients in our study whose biologic resurfacing survived to this follow-up time point appeared to be functioning well, but the overall outcome of soft tissue interposition in our patient population was much less promising. Although the worries over glenoid erosion with hemiarthroplasty and glenoid component loosening with total shoulder arthroplasty over time have been legitimized in recent follow-up studies, these potential complications seem to occur over the long-term, providing the patient with years of symptom-free improved function (Fig. 9).

Our investigation evaluated patients treated with lateral meniscal allograft implantation and interposition of human acellular dermal tissue matrix as biologic resurfacing methods for the glenoid. Taken together, our series is the largest group of biologic resurfacings reported in the orthopedic surgery literature. We believe that including the 10 patients with human acellular dermal tissue matrix resurfacing strengthens rather than detracts from our findings. Young patients with symptomatic glenohumeral arthritis continue to be an incredibly difficult patient population to effectively manage. The concept of resurfacing the native glenoid with a biologic interposition to improve symptoms while delaying the need for glenoid prosthetic replacement seems attractive. By including the outcomes of 2 different resurfacing techniques used in these complex patients, we believe that we tested the concept of biologic resurfacing as a whole, demonstrating an unacceptable failure rate at midterm follow-up. Analysis of our results showed no difference in outcomes between the patients treated with lateral meniscal allograft resurfacing and those treated with human acellular dermal tissue matrix.

The limitations of the current study include its retrospective nature and the relatively small number of patients included in our analysis. Because this was an observational

study evaluating intermediate-term follow-up subsequent to biologic resurfacing of the glenoid, we had no control group with which to compare outcomes to. The follow-up outcome assessment for 8 patients (18%) was by telephone interview, which may have introduced bias to our postoperative outcome evaluation. In addition, a nonuniform postoperative rehabilitation protocol was used, which may have affected our results. However, we compared the results between patients treated with each rehabilitation protocol and found no difference in any of the postoperative outcome parameters studied. Finally, 9 patients (22%) in our cohort underwent additional procedures at the time of biologic resurfacing that may have had an affect on their postoperative outcomes.

Conclusions

The management of young, active patients with symptomatic glenohumeral arthritis continues to be debated in the orthopedic surgery literature. Alternative treatments to total shoulder arthroplasty have been investigated in this patient population in an effort to improve postoperative outcomes and avoid the likely need for revision surgery secondary to failure of the glenoid component over time. Biologic resurfacing of the glenoid in combination with humeral head hemiarthroplasty has been described with varying results. In our intermediate-term evaluation of patients treated with glenoid resurfacing using lateral meniscal allograft or human acellular dermal tissue matrices, we found a clinical failure rate greater than 50% at a mean of 2.8 years of follow-up. On the basis of these poor clinical outcomes, we believe that biologic resurfacing of the glenoid may have a minimal and as yet undefined role in the management of glenohumeral arthritis in the young, active patient over more traditional methods of hemiarthroplasty or total shoulder arthroplasty.

Disclaimer

The authors, their immediate families, and any research foundations with which they are affiliated have not received any financial payments or other benefits from any commercial entity related to the subject of this article.

References

1. Ball C, Yamaguchi K. Meniscal allograft interposition arthroplasty for the arthritic shoulder. Description of a new surgical technique. *Tech Shoulder Elbow Surg* 2001;2:247-54.

2. Baumgarten KM, Lashgari CJ, Yamaguchi K. Glenoid resurfacing in shoulder arthroplasty: indications and contraindications. *Instr Course Lect* 2004;53:3-11.
3. Brislin KJ, Field LD, Ramsey JR. Surgical treatment for glenohumeral arthritis in the young patient. *Tech Shoulder Elbow Surg* 2004;5:165-9, <http://dx.doi.org/10.1097/01.bte.0000135965.23606.f0>
4. Burkhead WZ, Hutton KS. Biologic resurfacing of the glenoid with hemiarthroplasty of the shoulder. *J Shoulder Elbow Surg* 1995;4:263-70.
5. Burkhead WZ, Krishnan SG, Lin KC. Biologic resurfacing of the arthritic glenohumeral joint: historical review and current applications. *J Shoulder Elbow Surg* 2007;16(5 Suppl):S248-53, <http://dx.doi.org/10.1016/j.jse.2007.03.006>
6. Elhassan B, Ozbaydar M, Diller D, Higgins LD, Warner JJ. Soft-tissue resurfacing of the glenoid in the treatment of glenohumeral arthritis in active patients less than fifty years old. *J Bone Joint Surg Am* 2009;91:419-24, <http://dx.doi.org/10.2106/JBJS.H.00318>
7. Huijsmans P, van Rooyen K, du Toit DF, de Beer JF. The treatment of glenohumeral OA in the young and active patient with the Graft Jacket: preliminary results. *J Bone Joint Surg Br* 2004;87(Suppl III):275.
8. Iannotti JP, Norris TR. Influence of preoperative factors on outcome of shoulder arthroplasty for glenohumeral osteoarthritis. *J Bone Joint Surg Am* 2003;85:251-8.
9. Krishnan SG, Nowinski RJ, Harrison D, Burkhead WZ. Humeral hemiarthroplasty with biologic resurfacing of the glenoid for glenohumeral arthritis. Two to fifteen-year outcomes. *J Bone Joint Surg Am* 2007;89:727-34, <http://dx.doi.org/10.2106/JBJS.E.01291>
10. Krishnan SG, Reineck JR, Nowinski RJ, Harrison D, Burkhead WZ. Humeral hemiarthroplasty with biologic resurfacing of the glenoid for glenohumeral arthritis. Surgical technique. *J Bone Joint Surg Am* 2008;90(Suppl 2 Pt 1):9-19, <http://dx.doi.org/10.2106/JBJS.G.01220>
11. Lee BK, Vaishnav S, Hatch R, Itamura JM. Biologic resurfacing of the glenoid with meniscal allograft: long-term results with minimum 2-year follow-up. *J Shoulder Elbow Surg* 2013;22:253-60, <http://dx.doi.org/10.1016/j.jse.2012.04.019>
12. Levine WN, Djurasovic M, Glasson JM, Pollock RG, Flatow EL, Bigliani LU. Hemiarthroplasty for glenohumeral osteoarthritis: results correlated to degree of glenoid wear. *J Shoulder Elbow Surg* 1997;6:449-54.
13. Nicholson GP, Goldstein JL, Romeo AA, Cole BJ, Hayen JK, Twigg SL, et al. Lateral meniscus allograft biologic glenoid arthroplasty in total shoulder arthroplasty for young shoulders with degenerative joint disease. *J Shoulder Elbow Surg* 2007;16(5 Suppl):S261-6, <http://dx.doi.org/10.1016/j.jse.2007.03.003>
14. Norris TR, Iannotti JP. Functional outcome after shoulder arthroplasty for primary osteoarthritis: a multicenter study. *J Shoulder Elbow Surg* 2002;11:130-5, <http://dx.doi.org/10.1067/mse.2002.121146>
15. Parsons IM, Millett PJ, Warner JJ. Glenoid wear after shoulder hemiarthroplasty: quantitative radiographic analysis. *Clin Orthop Relat Res* 2004;421:120-5, <http://dx.doi.org/10.1097/01.blo.0000119249.61696.f1>
16. Pearl ML, Romeo AA, Wirth MA, Yamaguchi K, Nicholson GP, Creighton RA. Decision making in contemporary shoulder arthroplasty. *Instr Course Lect* 2005;54:69-85.
17. Pfahler M, Jena F, Neyton L, Sirveaux F, Mole D. Hemiarthroplasty versus total shoulder prosthesis: results of cemented glenoid components. *J Shoulder Elbow Surg* 2006;15:154-63, <http://dx.doi.org/10.1016/j.jse.2005.07.007>
18. Radnay CS, Setter KJ, Chambers L, Levine WN, Bigliani LU, Ahmad CS. Total shoulder replacement compared with humeral head replacement for the treatment of primary glenohumeral osteoarthritis: a systematic review. *J Shoulder Elbow Surg* 2007;16:396-402, <http://dx.doi.org/10.1016/j.jse.2006.10.017>
19. Rispoli DM, Sperling JW, Athwal GS, Schleck CD, Cofield RH. Humeral head replacement for the treatment of osteoarthritis. *J Bone Joint Surg Am* 2006;88:2637-44, <http://dx.doi.org/10.2106/JBJS.E.01383>
20. Savoie FH, Brislin KJ, Argo D. Arthroscopic glenoid resurfacing as a surgical treatment for glenohumeral arthritis in the young patient: midterm results. *Arthroscopy* 2009;25:864-71, <http://dx.doi.org/10.1016/j.arthro.2009.02.018>
21. Sperling JW, Antuna SA, Sanchez-Sotelo J, Schleck C, Cofield RH. Shoulder arthroplasty for arthritis after instability surgery. *J Bone Joint Surg Am* 2002;84:1775-81.
22. Sperling JW, Cofield RH, Rowland CM. Neer hemiarthroplasty and Neer total shoulder arthroplasty in patients fifty years old or less. Long-term results. *J Bone Joint Surg Am* 1998;80:464-73.
23. Torchia ME, Cofield RH, Settergren CR. Total shoulder arthroplasty with the Neer prosthesis: long-term results. *J Shoulder Elbow Surg* 1997;6:495-505.
24. Wirth MA, Rockwood CA. Complications of shoulder arthroplasty. *Clin Orthop Relat Res* 1994;307:47-69.
25. Wirth MA, Rockwood CA. Complications of total shoulder replacement arthroplasty. *J Bone Joint Surg Am* 1996;78:603-16.