

Current Concepts

Complications Associated With Anterior Shoulder Instability Repair

Richard W. Kang, M.D., M.S., Rachel M. Frank, B.A., B.S., Shane J. Nho, M.D., M.S.,
Neil S. Ghodadra, M.D., Nikhil N. Verma, M.D., Anthony A. Romeo, M.D.,
and LCDR Matthew T. Provencher, M.D., MC, USA

Abstract: Anterior shoulder instability is a common orthopaedic problem, and the surgical treatment, both open and arthroscopic, has been shown to effectively restore stability and prevent recurrence. However, despite success with these surgical techniques, there are several clinically relevant complications associated with both open and arthroscopic techniques for anterior shoulder stabilization. These complications can be subdivided into preoperative, intraoperative, and postoperative and include entities such as nerve injury, chondrolysis, incomplete treatment of associated lesions, and subscapularis dysfunction. When they occur, complications may significantly impact patient outcomes and function. Therefore, surgeon awareness and identification of the factors associated with these complications may help prevent occurrence. Although failure of instability repair can be classified as a complication of surgery, it requires an entirely separate discussion and is therefore not addressed in this article. Because most of the previously published studies on anterior shoulder instability have emphasized surgical technique and clinical outcomes, the purpose of this article is to define the complications associated with anterior instability repair and provide recommendations on techniques that may be used to help avoid them. **Key Words:** Instability—Anterior shoulder—Complications—Repair—Arthroscopic stabilization.

Anterior shoulder instability involves a range of disorders and can be classified by magnitude (subluxation, dislocation), time course (acute, recurrent, chronic), and etiology (traumatic, atraumatic).¹ The most common cause of anterior shoulder instability is a traumatic injury creating an initial dislocation, often associ-

ated with a Bankart lesion, in which the anteroinferior glenoid labrum and inferior glenohumeral ligament are detached from the glenoid.^{2,3} Historically, anterior glenohumeral instability has been addressed with open and arthroscopic techniques, both of which have led to promising results. However, in some cases complications lead to unsatisfactory patient outcomes. For discussion purposes, the complications associated with anterior shoulder instability repair can be divided into preoperative, intraoperative, and postoperative groups.

From the Section of Sports Medicine, Department of Orthopaedic Surgery, Rush University Medical Center, Rush Medical College of Rush University (R.W.K., R.M.F., S.J.N., N.S.G., N.N.V., A.A.R.), Chicago, Illinois; and Department of Orthopaedic Surgery, Division of Sports Surgery, Naval Medical Center San Diego (M.T.P.), San Diego, California, U.S.A.

The authors report no conflict of interest.

Address correspondence and reprint requests to Shane J. Nho, M.D., M.S., Rush University Medical Center, 1725 W Harrison St, Suite 1063, Chicago, IL 60611, U.S.A. E-mail: snho@hotmail.com

© 2009 by the Arthroscopy Association of North America

0749-8063/09/2508-0936\$36.00/0

doi:10.1016/j.arthro.2009.03.009

PREOPERATIVE COMPLICATIONS

Prevention of complications in the preoperative setting begins with appropriate diagnosis and determination of clear surgical indications. Thus a thorough history and complete physical examination are essential to preventing complications. Several key issues in

the patient history are important, including the mechanism of injury, previous surgical and/or nonsurgical treatment of the shoulder, and activity level of the patient. Specific questions to be asked include whether the injury was traumatic, whether there was dislocation/subluxation and whether a reduction was required, whether this was the first injury to this shoulder, how the arm was positioned at the time of injury, and the number of dislocation events and the activities that caused them, as well as details about the reduction. Although these questions seem standard for any initial patient interview for a shoulder injury, the answers to these questions may rule out a patient for surgery or otherwise assist the surgeon in avoiding intraoperative and postoperative complications.

The physical examination is equally as important as the history and may help define the direction and magnitude of instability, as well as coexisting conditions. The structure, function, neurologic status, and strength of the injured shoulder should be compared with the contralateral shoulder. Loss of motion should alert the surgeon to additional pathology or additional diagnoses. Specifically, if significant stiffness is noted, range of motion must be optimized before any operative stabilization procedure to avoid progressive loss of motion. Shoulder stability testing should also be addressed. Special attention should be given to the various glenohumeral ligaments, because the type of laxity might change the surgical plan. Specifically, asymmetric loss of external rotation at the side may be indicative of overconstraint of the subscapularis, the rotator interval, or the superior capsule (superior and middle glenohumeral ligaments) and may herald a potential technical issue in that the primary instability pathology (inferior glenohumeral ligament) was not addressed. Asymmetric loss of external rotation in abduction may identify nonanatomic overconstraint of the inferior ligaments.

Next, strength in all planes should be evaluated. Weakness in 1 or more planes should alert the surgeon to the presence of concomitant pathology such as rotator cuff tear or suprascapular nerve palsy. The physician should always pay specific attention to subscapularis function by use of the belly-press test and liftoff maneuver. Subscapularis rupture may occur after traumatic shoulder instability and should be recognized preoperatively. In patients who have undergone previous open surgery, failure of subscapularis repair or subscapularis dysfunction may be present and should be noted and documented preoperatively.

Preoperative imaging is also a major component to selecting proper patients for anterior shoulder insta-

bility repair and for avoiding potential surgical and postsurgical complications. Bone loss of the glenoid and humeral head has been shown to be an important predictor of clinical failure after anterior shoulder stabilization surgery.^{2,4,5} Preoperative radiographs include the anteroposterior, scapular-Y, and axillary views. In addition, a Stryker notch view is helpful for evaluating Hill-Sachs lesions, whereas the West Point view may be used to determine glenoid bone loss. Computed tomography is an extremely useful way to determine the extent of any bone loss in the humeral head and/or glenoid component, especially with advanced software that allows for 3-dimensional imaging of surface lesions (Fig 1). Various studies have reported that glenoid and/or humeral head bone loss is the most common reason for failure of arthroscopic stabilization procedures.^{2,5,6} Several published clinical studies have shown increased recurrence rates of glenohumeral instability after surgical repair when preoperative glenoid bone loss ranged from 20% to 30%,⁵⁻⁷ and in 2000 Burkhart and De Beer⁶ reported a 67% recurrence rate when the patient had significant bone loss. In patients with a large amount of glenoid bone loss (generally >25%), an open bony augmentation procedure provides predictable restoration of stability. Thus computed tomography imaging (especially 3-dimensional reconstruction) is extremely helpful in identifying patients who require bony reconstruction in lieu of arthroscopic soft-tissue repair.

Magnetic resonance imaging is the modality of choice to evaluate the soft-tissue structures surrounding the shoulder, including the glenoid labrum and

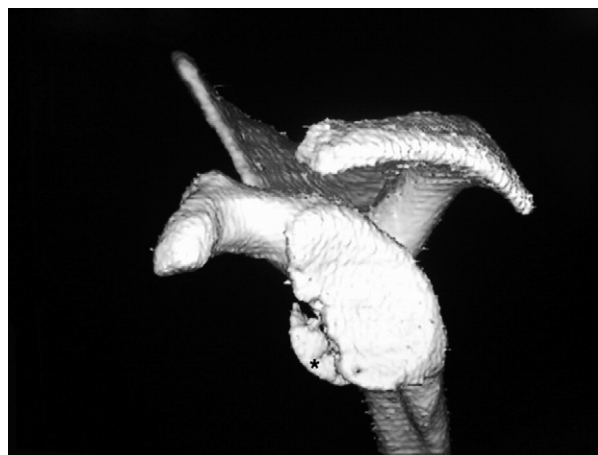


FIGURE 1. Three-dimensional computed tomography image depicting glenoid component. The asterisk denotes an anterior-inferior glenoid rim fragment.

glenohumeral ligament complex. Magnetic resonance arthrography has been shown to be helpful in improving visualization of glenohumeral pathology. In contrast, in a patient with an acute episode of instability, the hemarthrosis typically eliminates the need for arthrography and plain magnetic resonance imaging is just as effective. Failure to identify and address humeral-sided avulsion (humeral avulsion of anterior glenohumeral ligament) may lead to an increased rate of recurrence. Preoperative identification of subscapularis or superior rotator cuff tear allows for appropriate preoperative consultation and surgical planning.

A misdiagnosis of the type of instability leads to the incorrect surgical procedure, which may lead to altered range of motion and recurrent instability symptoms, as well as degenerative arthritis. In 1985 Hawkins and Hawkins⁸ reported recurrent symptoms resulting from misdiagnosis of anterior shoulder instability in 11 of 31 total shoulders with recurrent symptoms. Furthermore, McAuliffe et al.⁹ noted in 1988 that misdiagnosis of anterior shoulder instability was found to be the cause of failed surgery in 11 of 36 patients. Finally, in 1992 Burkhead and Ritchie¹⁰ reported that 5 of 23 failed cases of shoulder instability repair were because of an incorrect diagnosis. Finally, there is a subset of patients who will voluntarily dislocate their shoulder either because of psychiatric issues or for secondary gain. These types of patients do not fare well with operative measures. An appropriate history and examination allow identification of these patients who should be directed toward nonoperative measures.¹¹ In addition, posterior instability is often mistaken for anterior instability, and prior open and anterior repairs have not helped the patients' main direction of instability (Table 1).¹²

INTRAOPERATIVE COMPLICATIONS

Although intraoperative complications are uncommon, they do occur and the results can be devastating (Table 2). First and foremost, once the patient is asleep and before any incisions are made, both shoulders should undergo a thorough examination under anesthesia. Such an examination permits assessment of the glenohumeral joint and any associated laxity without patient guarding, and it is a simple and efficient mechanism to confirm the preoperative diagnosis.¹³ The examination typically consists of ranging both shoulders through forward flexion as well as internal and external rotation at 90° and with the arm at the side. Each shoulder is also evaluated for the presence of the sulcus sign, which can indicate excessive laxity of the rotator interval or inferior capsule. Finally, both shoulders are tested for anterior and posterior translation and are graded accordingly. Shoulders in which the humeral head is translated to the glenoid rim, over the rim with spontaneous reduction, or over the rim and remaining locked are referred to as grade I, II, and III, respectively (Fig 2).

Even if an open stabilization is planned, it may be prudent to perform an arthroscopic evaluation to allow a complete diagnostic assessment of the glenohumeral joint to identify all concomitant pathology and to enable the surgeon to create an appropriate plan for repair.¹⁴⁻¹⁶ When these lesions are not adequately addressed surgically, higher recurrence rates have been reported.^{1,17-21} It is also vital to recognize any capsular pathology, because failure to do so has been shown to be the most common cause of a failed arthroscopic stabilization.²²⁻²⁴ Finally, one of the easiest ways to avoid intraoperative complications is for the surgeon

TABLE 1. Complications Encountered From Preoperative Workup

Complication	Pearls: How to Avoid
Misdiagnosis	Thorough history and full shoulder examination
Failure to maximize ROM	Aggressive physical therapy, with focus on the following: Shoulder stabilization exercises, Shoulder strength, Shoulder ROM
Inadequate imaging	West Point axillary view (glenoid bone loss), Stryker Notch view (Hill-Sachs lesion), 3D CT scan (bone loss), MRI/MRA (concomitant pathology)
Inadequate history	Determine cause (e.g., voluntary, traumatic, or recurrent) and timing (e.g., midseason). Determine whether patient had previous surgery
Inadequate physical examination	MDI v anterior instability v posterior instability
Asymmetric loss of ER at side	Possible overconstraint of subscapularis or rotator interval
Asymmetric loss of ER at abduction	Possible overconstraint of IGHL
Weakness in scapular plane	Alert to concomitant pathology including rotator cuff tear and suprascapular nerve palsy

Abbreviations: ROM, range of motion; 3D CT, 3-dimensional computed tomography; MRI, magnetic resonance imaging; MRA, magnetic resonance arthrography; MDI, multidirectional instability; ER, external rotation; IGHL, inferior glenohumeral ligament.

TABLE 2. *Intraoperative Complications With Instability Repair*

Complication	Pearls: How to Avoid
Misdiagnosis	Full shoulder examination under anesthesia. Place patient in lateral decubitus position for optimal visualization and access to glenoid labrum
Nerve damage	Axillary nerve: Located 1-1.5 cm below inferior GH capsule. Musculocutaneous nerve: located 5-8 cm inferior to coracoid. Careful placement of head to avoid excessive cervical F/E. Avoid excessive humeral distraction
Inadequate capsulorrhaphy tension	Examine shoulder ROM after repair
Inadequate restoration of glenoid concavity	Incorporate bony Bankart into repair. If >25%, consider bone augmentation with Latarjet v iliac crest graft. Avoid excessive anterior-inferior capsular tightening in overhead throwers
Chondrolysis	Avoid thermal capsulorrhaphy and intra-articular pain pump
Hardware failure	Do not use bioabsorbable tacks. Place anchors below articular margin with firm purchase in subchondral bone. Place 3 anchors below 3-o'clock position. Use >3 anchors with first anchor at 5:30-o'clock position and 45° to articular surface

Abbreviations: GH, glenohumeral; ROM, range of motion; F/E, flexion/extension.

to become more familiar with normal anatomy as well as pathologic anatomy so as to be better equipped to handle challenges in the operating room.²⁵

Intraoperative complications can be categorized into problems associated with nerve damage, capsulorrhaphy technique, glenoid concavity, anterior capsular deficiency, hardware failure, chondrolysis, and anesthesia. The nerves most commonly damaged during both open and arthroscopic anterior shoulder stabilization procedures are the axillary and musculocu-

taneous nerves, because of their proximity to the glenohumeral joint (Fig 3). The axillary nerve is located 1 to 1.5 cm below the inferior glenohumeral capsule, with the sensory branch lying closest to the glenoid rim.²⁶ Anatomic studies have shown that the musculocutaneous nerve may penetrate the coracobrachialis muscle belly with a minimum distance of 5 cm inferior to the coracoid process.²⁷ During surgery, both of these nerves can be damaged with retractors and other surgical equipment.²⁸ One study reported an

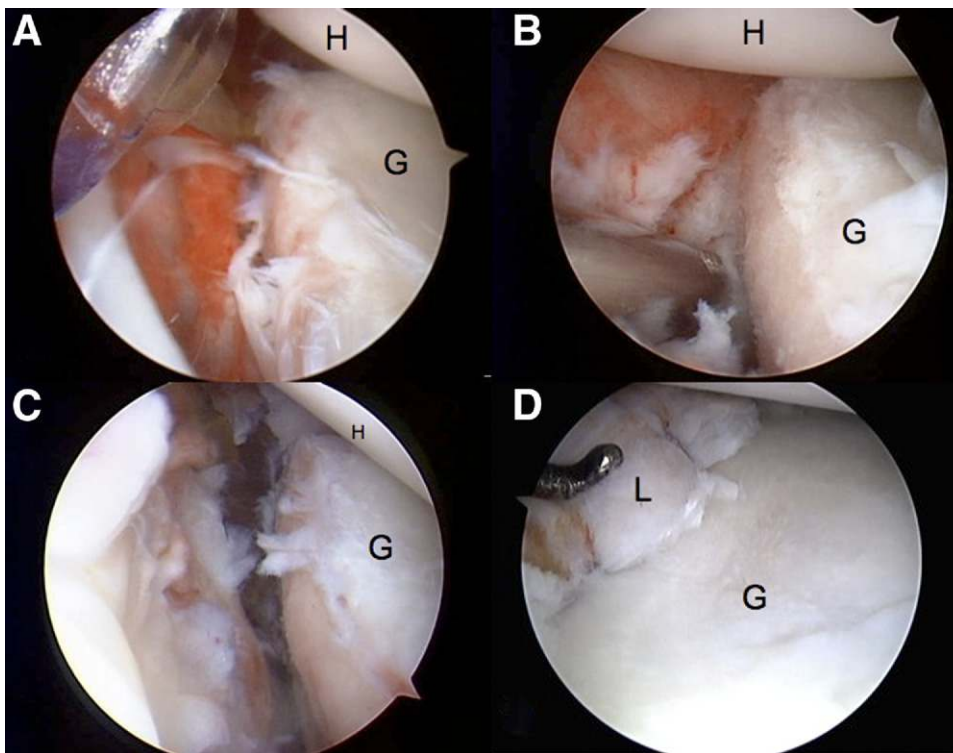


FIGURE 2. Arthroscopic images (anterior portal) of right shoulder with patient in lateral decubitus position showing capsulolabral and glenoid preparation. (H, humeral head; G, glenoid, L, labrum.) (A) Elevator device. The arthroscope should be left in the anterosuperior portal to enable adequate viewing. (B) Shaver on forward, bur on reverse, to prepare glenoid. The surgeon should be sure to preserve bone. (C) The subscapularis fibers should be visualized after appropriate glenoid preparation and capsulolabral mobilization. (D) Final appearance of arthroscopic Bankart repair.

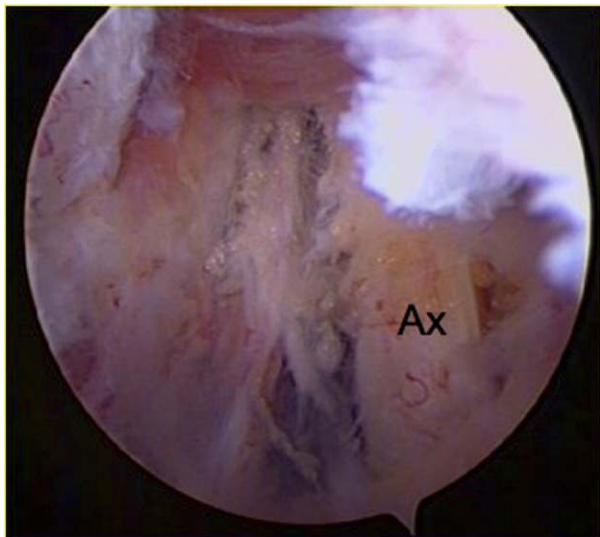


FIGURE 3. Arthroscopic view (anterior portal) of axillary nerve (Ax) in right shoulder with patient in lateral decubitus position.

8.2% incidence of neurologic disturbance in 282 patients after open reconstruction for anterior shoulder instability, including both sensory and sensorimotor neuropathies.²⁹ Arthroscopically, nerve complications can occur as a result of inappropriately placed portals, improper positioning of the patient, and/or strain placed on the brachial plexus because of traction. To avoid this potential complication, the surgeon should take care when placing the arthroscopy portals particularly in the inferior positions (5- and 7-o'clock portals).¹³ In addition, it is important to ensure that all bony prominences and nerve compression sites are well padded during positioning. Additional causes of neurologic injury include patient positioning, humeral traction, and complications related to anesthesia. With the patient in either the lateral or beach-chair position, care must be taken to appropriately position the neck to avoid excessive cervical flexion or extension. In the lateral position an adequate axillary roll must be used to protect the opposite-side neurologic structures. In addition, careful positioning and padding of the lower extremities will reduce the risk of pressure-induced neurapraxia. In both positions excessive humeral distraction may cause traction injury to the brachial plexus and should be avoided. Use of regional anesthesia may be associated with a low risk of neurologic injury. Although interscalene block has been reported as safe, the risk of hematoma and nerve damage remains.^{18,30} Specifically, ipsilateral Horner syndrome, ipsilateral vocal cord paralysis, pneumothorax, and

laryngeal and phrenic nerve palsies have been reported as neurologic injuries after the application of an interscalene block.³¹⁻³³ In addition, complications such as compression of the brachial plexus due to a pseudoaneurysm of the axillary artery have also been reported.^{34,35}

One of the more frustrating intraoperative complications associated with anterior glenohumeral instability repair involves hardware failure. As with any surgery, hardware placed near a movable joint always has the potential to loosen and possibly migrate within the joint space. The glenohumeral joint is no exception, and it may even be at greater risk because of the wide range of motion that the joint is placed through on a regular basis. In the shoulder fast-absorbing biologic materials in the form of labral tacks have been associated with recurrent effusions, synovitis, stiffness, and pain. In 2003 Freehill et al.³⁶ reported on 10 of 52 patients (19%) in whom pain and/or stiffness developed after stabilization surgery by use of poly-L-lactic acid implants, each of whom had arthroscopic signs of glenohumeral synovitis 8 months after surgery. Similarly, Sassmannshausen et al.³⁷ reported on 6 patients who had pain and/or mechanical symptoms after stabilization surgery with bioabsorbable tacks.

Implant or component failure or loosening after surgery can cause disruption to both the glenoid and humeral articular surfaces, increasing the likelihood of cartilage damage and the development of degenerative arthritis. Several clinical studies have shown the devastating complications associated with failed placement of screws, sutures, and anchors. In 1984 Zuckerman and Matsen³⁸ described complications in 35 patients, among a cohort of 37, who had undergone surgery for anterior glenohumeral instability. Of these patients, 34 underwent additional procedures for hardware removal, and of these, 41% had signs of significant injury to the glenoid or humeral articular surface due to hardware. Both bioabsorbable and metallic suture anchors have also been reported to cause complications related to proud anchor placement or loosening. Because anchors must be placed on the glenoid articular surface to allow appropriate capsulolabral reconstruction, extreme care must be taken to ensure that the anchors are placed below the articular margin with firm purchase in the subchondral bone. It is critical to know the functional depth of glenoid implants to avoid proud anchor placement and substantially reduce the risk of hardware-related chondral injury.

Severe glenohumeral chondrolysis is a rare but serious complication that has been associated with an-

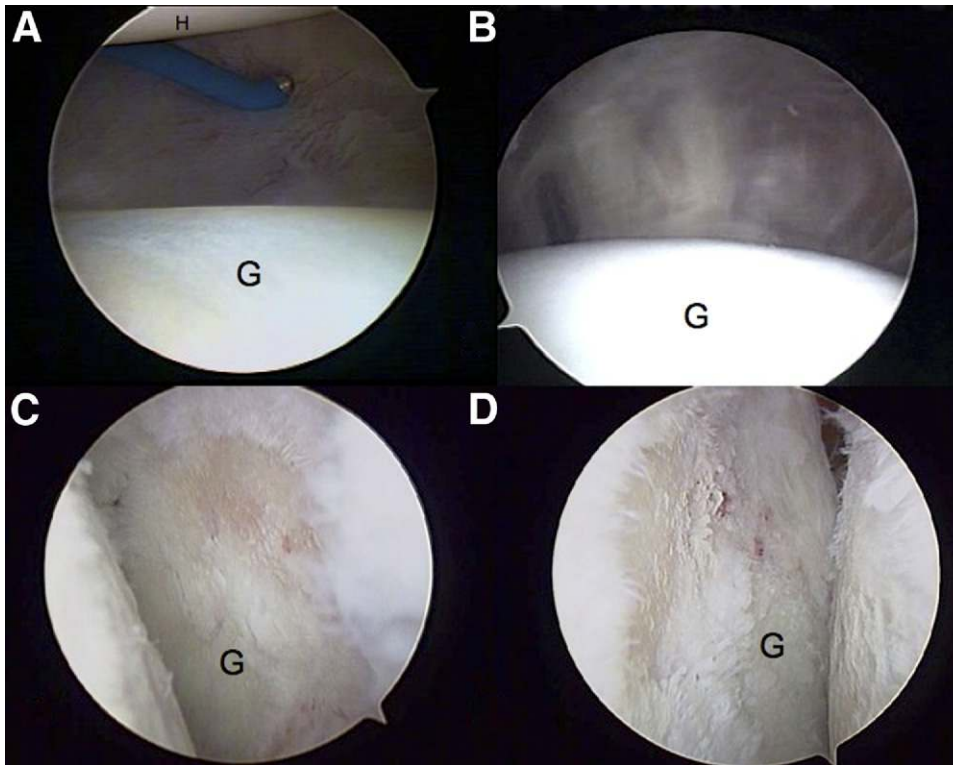


FIGURE 4. Arthroscopic images (of right shoulder) depicting various complications associated with thermal capsulorrhaphy. (H, humeral head; G, glenoid). (A, B) Lateral decubitus position; necrosis of capsule after treatment with radiofrequency energy device. (C, D) Beach-chair position; glenohumeral chondrolysis.

terior shoulder instability repair. Although the exact cause of chondrolysis after labral repair has not been determined, evidence suggests an association with thermal capsulorrhaphy or the use of an intra-articular pain pump after surgery (Fig 4).³⁹⁻⁴¹ Specifically, Hansen et al.⁴⁰ reported on the use of intra-articular bupivacaine and epinephrine pain pumps and found that glenohumeral chondrolysis developed in 12 of 19 patients (63%). This rapid progression of cartilage loss on the glenoid and/or humeral head surface is devastating for the patient, and very few treatment options exist once the diagnosis has been made (Fig 5). In addition, because these patients are often young and active individuals, arthroplasty options may be limited and require multiple subsequent revision procedures.⁴² Although, to date, no single etiology has been identified as the cause of chondrolysis associated with anterior shoulder instability repair, because of the devastating nature of this complication, we recommend avoidance of thermal capsulorrhaphy and the implantation of intra-articular pain pumps until more definitive data are available.

Another detrimental intraoperative complication is inadequate anchor positioning, which most commonly occurs because anchors are placed too superiorly on the glenoid (Fig 6). The goal of shoulder instability

repair should be a minimum of 3 anchors below 3 o'clock (the equator). Both practice and surgical expertise are required not only to correctly place anchors on the glenoid in the position of the anterior instability pathology but also to safely place them to avoid axillary nerve damage by anchor insertion instruments.

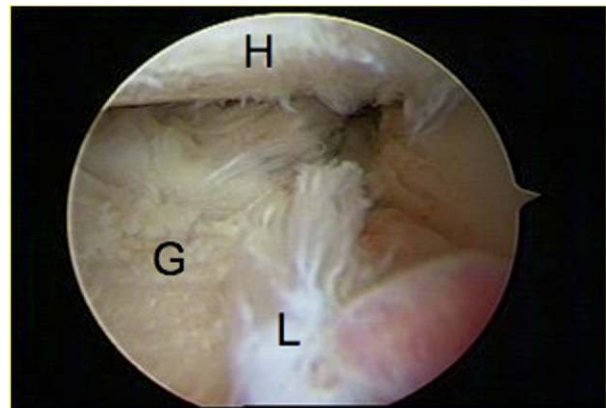


FIGURE 5. Arthroscopic image (left shoulder) in lateral decubitus position, seen through anterior portal, depicting glenohumeral chondrolysis associated with intra-articular pumps. (H, humeral head; G, glenoid; L, labrum.)

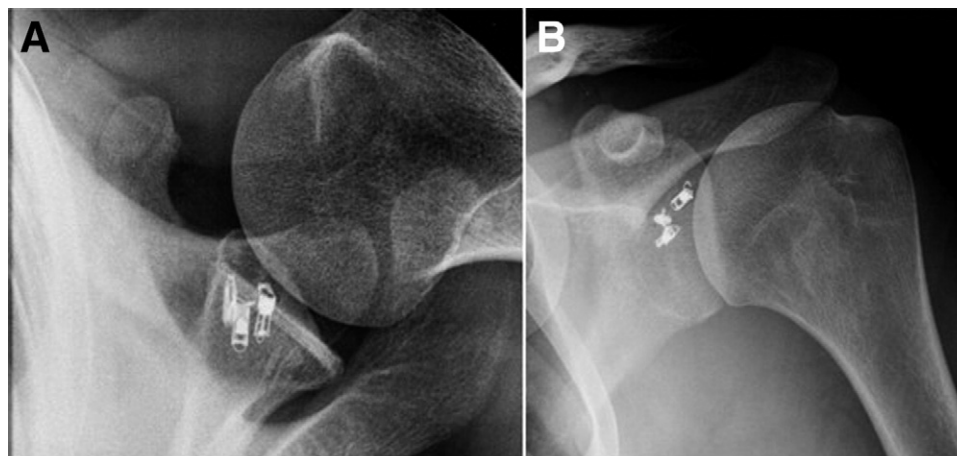


FIGURE 6. Radiographs of left arm, depicting superior placement of 3 suture anchors. (A, axillary view; B, anterior-posterior view.)

Typically, the first anchor is placed at between the 5- and 6-o'clock positions, at 2 mm onto the articular rim, at an angle of 45° relative to the surface of the glenoid. To secure the repair, 3 anchors should be placed inferior to the 3-o'clock position.^{43,44} Failures of arthroscopic instability repair have been associated with fewer than 4 well-positioned anchors.⁵

Poor tensioning of the capsule and associated structures and capsular overtightening are both potential intraoperative complications during anterior shoulder instability repair. Inadequate tensioning of the glenohumeral ligaments and/or capsule can lead to postoperative laxity, leaving patients less satisfied. Several techniques, including capsulolabral suture repair and thermal capsulorrhaphy, have been effective in addressing capsular laxity.⁴³ Similarly, if the repair construct is overtightened during surgery, a nonanatomic

repair may result, leaving patients with stiffness and potential loss of external rotation leading to postoperative arthritis.

Another problem that is potentially avoidable is the failure to adequately recognize and address concomitant pathology (Table 3). It is crucial to address any additional tears, including those that extend posteriorly, rotator cuff tears, and SLAP lesions, at the time of instability repair. This is especially true with regard to concurrent glenoid bone loss, which—as already mentioned—is a major reported cause of instability repair failure. Arthroscopically, if the patient is noted to have glenoid bone loss and has an associated osseous Bankart lesion, it is helpful to incorporate the Bankart fragment into the repair.^{45,46} If there is no bony fragment and there is less than 20% to 25% glenoid bone loss, a soft-tissue procedure may still be

TABLE 3. Common Pathologic Findings With Anterior Instability Repair

Complication	Pearls: How to Treat
Rotator cuff tear	Identify partial tears and look for common tear patterns: Crescent, U-shaped, L-shaped. Note: Intact cuff confers stability
AC joint pain	Distal clavicle excision <i>v</i> preoperative AC joint injection
Extensive labral tear	Visualize entire glenoid labrum
SLAP	Address at time of surgery. Look for concomitant biceps pathology
ALPSA lesion	Tear of anterior band of IGHL. Labrum and scapula periosteal sleeve detached medially and inferiorly on glenoid neck
HAGL lesion	Visualize from posterior portal with 30° arthroscope in axillary pouch in ER and IR. Repair both in inferior-to-superior and medial-to-lateral directions
Bankart lesion	Dissect labrum medially until muscle fibers of subscapularis are visible: <15% bone loss: labral and capsular repair 15%-25% bone loss: incorporate bony fragment into repair >25% bone loss: glenoid bone reconstruction
Hill-Sachs lesion	If engaging, consider remplissage or bone augmentation

Abbreviations: AC, acromioclavicular; ALPSA, anterior labrum periosteal sleeve avulsion; IGHL, inferior glenohumeral ligament; HAGL, humeral avulsion of anterior glenohumeral ligament; ER, external rotation; IR, internal rotation.

TABLE 4. *Postoperative Complications*

Complication	Pearls: How to Avoid
Stiffness	Attain optimal preoperative ROM. Achieve adequate intraoperative capsular tension
Subscapularis dysfunction	Look for tenderness to palpation at lesser tuberosity. Pain and decreased strength with IR and belly press; increased ER at side
Pain	Acute: physical therapy, NSAIDs, cortisone injection. Chronic: consider revision
Infection	Look for <i>P. acnes</i>
Chondrolysis	Possible association with intra-articular pain pumps and improper anchor placement

Abbreviations: ROM, range of motion; IR, internal rotation; ER, external rotation; NSAIDs, nonsteroidal anti-inflammatory drugs.

adequate, although failure rates are slightly higher than in patients without bone loss.^{46,47}

POSTOPERATIVE COMPLICATIONS

Several complications can occur after surgical anterior shoulder stabilization, including stiffness, loss of motion, loss of strength and function, and pain (Table 4). Stiffness and adhesive capsulitis are rare complications that are nevertheless extremely troublesome for patients. If a shoulder is identified to have loss of motion preoperatively, range of motion must be restored before any stabilization procedure is undertaken. In our experience most patients in whom stiffness develops after an initial instability event do not require further stabilization surgery once motion has been restored.

Decreased range of motion is a common complication that can follow stabilization surgery. In general, after anterior stabilization, range-of-motion loss occurs primarily in the plane of external rotation because of selective tightening of the anterior capsule. Several authors have noted significant loss of external rotation after anterior shoulder instability repair,⁴⁸⁻⁵⁰ and in 2001 Karlsson et al.⁴⁸ found that external rotation was significantly greater with arthroscopic repair (90°) as compared with open repair (80°). Although a small loss of external rotation is well tolerated in most patients, excessive anterior-superior capsular (and rotator interval) tightness, manifested by significant loss of external rotation at the side, can lead to posterior shearing of the humeral head on the glenoid surface and potentially accelerate articular degeneration. This situation is most commonly encountered in historical procedures that selectively tightened the anterior capsule and subscapularis (Magnuson-Stack, Putti-Platt). In this situation a revision procedure should be performed to lengthen the anterior soft tissues and thereby obviate further joint damage. This can be

achieved first with a capsular release. Further lengthening can be achieved with a subscapularis release or Z-plasty as described in MacDonald et al.⁵¹ In addition, in the setting of anterior shoulder instability in the dominant extremity of an overhand thrower, care should be taken to avoid excessive anterior-inferior capsular plication because even minor losses in external rotation may result in loss of pitch velocity.

Functional and strength losses are also rare yet serious complications after anterior shoulder instability repair. Several long-term clinical follow-up studies have reported weakness in external rotation, abduction, and internal rotation several years postoperatively.^{49,52} Subscapularis dysfunction is a rather serious complication after open anterior glenohumeral stabilization surgery. Patients present with persistent pain or weakness and potentially instability as well. On examination, patients will have tenderness at the lesser tuberosity, pain and/or weakness with active internal rotation, increased passive external rotation, and difficulty with the lumbar liftoff test. In a 2005 study performed by Sachs et al.,⁵³ 23% of the 30 patients studied had an incompetent subscapularis at a mean of 4 years after open Bankart repair. Of these patients, only 57% stated that they would have the surgery again, whereas 100% of the patients with an intact subscapularis claimed that they would have the surgery again. Scheibel et al.⁵⁴ also noted the complication of subscapularis dysfunction in patients after open shoulder stabilization surgery in a 2006 study observing 25 patients and 12 control subjects over a period of 4 years. This study compared the clinical and imaging results of patients who had undergone primary surgery with those who had undergone revision surgery as well as with healthy control subjects. Overall, 53.8% of the primary surgery patients and 91.6% of the revision surgery patients had signs of subscapularis muscle insufficiency after 4 years of follow-up. Another clinical study, by Greis et al.,⁵⁵ described 4 patients who required reopera-

tion because of failure of the subscapularis tendon after a Bankart reconstruction for anterior instability.

Pain is another complication that may occur after shoulder stabilization. In a study reporting on out-

comes after Bankart repair, Gill et al.⁵⁶ reported that 29 of 60 patients had pain at a mean of 11.9 years after their operation. The etiology of pain after surgery is often multifactorial and may include loss of motion,

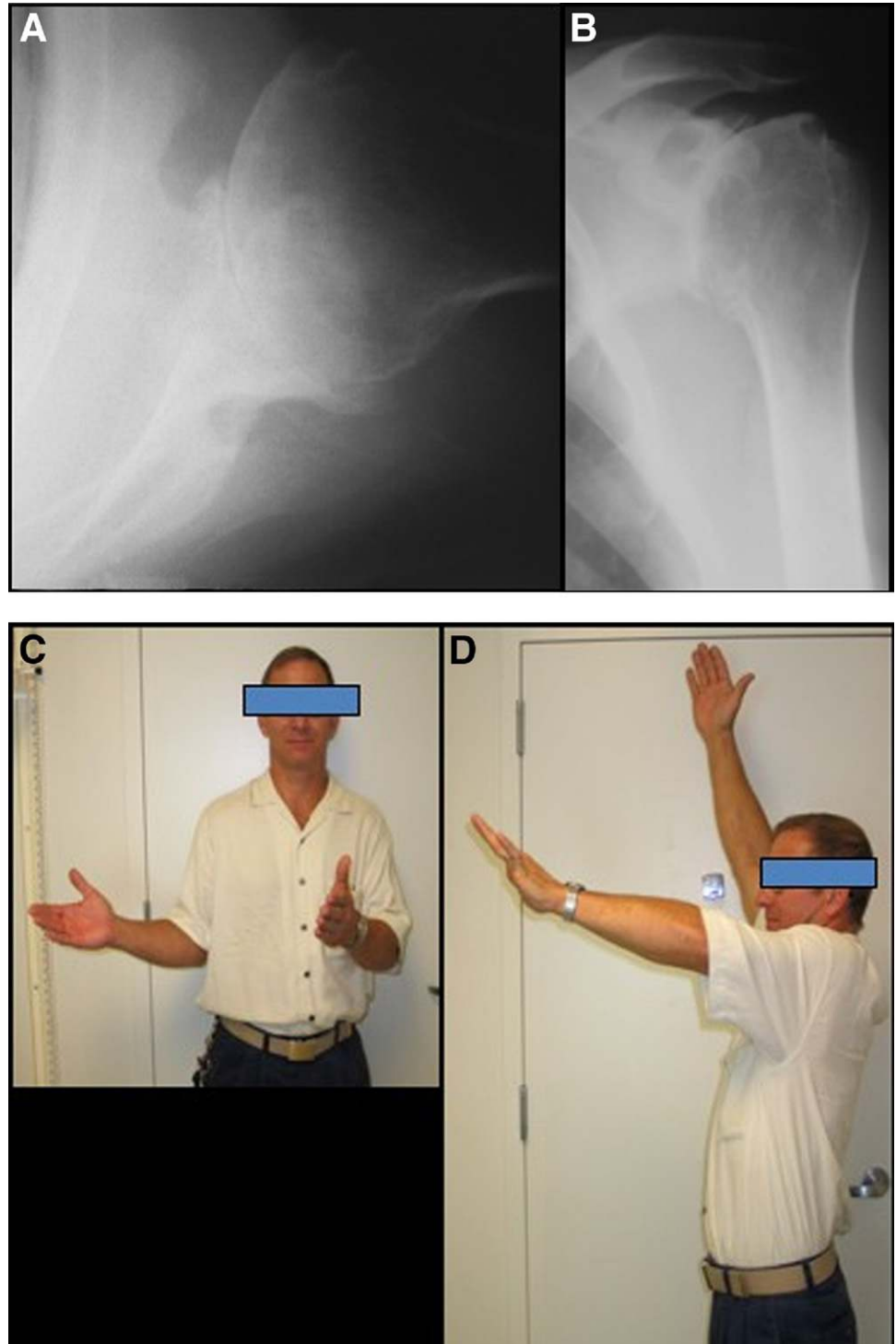


FIGURE 7. Fifty-year-old man with history of recurrent dislocations. (A, B) Plain radiographs (left shoulder) showing severe joint degeneration with glenoid retroversion. (C, D) Physical examination with forward elevation limited to 95° and no external rotation.

loss of strength, and/or loss of muscle endurance; chondral disease or injury; and biceps tendon or rotator cuff pathology.⁵⁷ In most cases initial treatment should be conservative including physical therapy for normalization of range of motion and strength, oral anti-inflammatory medications, and/or cortisone injection. Persistent pain is often a diagnostic dilemma after shoulder stabilization, particularly in cases where no further instability is present. In these situations conservative care should be exhausted, and a firm diagnosis should be established by use of examination and imaging data before any revision surgery is performed.

When considering the postoperative complication of degenerative glenohumeral arthritis, long-term clinical studies provide the most useful information (Fig 7). Several studies have reported arthritic changes in the glenohumeral joint several years after anterior instability repair; however, most of these studies reported minor degenerative changes or changes not statistically correlated with the surgery. In a 15-year follow-up study of 33 shoulders, only 3 were found to have moderate degenerative changes in the glenohumeral joint whereas 1 was found to have severe arthritic changes.⁵⁰ In a larger study observing 570 patients at a mean of 6.5 years after surgery, the incidence of glenohumeral arthritis was found to be 9.2% to 19.7% but was correlated with older age as opposed to postsurgical complications.⁵⁸ A 2006 study by Pelet et al.⁵⁹ followed 30 shoulders over a period of 29 years and found that 40% had arthritis, indicating that the Bankart procedure does not prevent the development of glenohumeral degenerative arthritis. When comparing operative and nonoperative treatment, a recent study by Hovelius et al.⁶⁰ found that approximately 50% of patients with primary anterior shoulder dislocations treated nonoperatively had no further dislocations or had become stable over the course of 25 years.

Infection can occur after any type of surgery including shoulder stabilization. Fortunately, the incidence is relatively rare after this type of shoulder surgery. Previous reports have indicated an incidence of 0% to 6% after open stabilization and 0.04% to 0.23% after arthroscopic stabilization.^{28,61} When infection occurs, it is treated following standard orthopaedic principles including thorough irrigation and debridement and intravenous antibiotics. It should be noted that most shoulder infections are due to *Propionibacter acnes*, and selective cultures should be taken, looking specifically for this organism, which can take several

days longer to grow in the laboratory and also requires selective antibiotics for successful eradication.

Finally, issues such as patient noncompliance with immobilization, rehabilitation therapy, and/or return-to-activity restrictions are also associated with postoperative complications after anterior shoulder instability surgery.⁶² These complications can be minimized, however, by proper patient selection, education, and monitoring.

CONCLUSIONS

Regardless of the mechanism of injury, anterior shoulder instability is a common and frustrating orthopaedic problem, often requiring surgical repair. Although advances have been made over the past several years in less invasive arthroscopic repair of the unstable shoulder, several complications may occur after surgery, creating difficult situations for patients as they attempt to return to athletic activity. Common issues, including nerve injury, chondrolysis, incomplete treatment of associated lesions, hardware failure, decreased strength or range of motion, persistent pain, degenerative arthritis, infection, and subscapularis dysfunction, remain problematic within the realm of shoulder stabilization surgery, and future investigation is needed to either prevent or treat such complications.

REFERENCES

1. Matsen FA III, Lippitt SB, Sidles JA, Harryman DT II. *Practical evaluation and management of the shoulder*. Philadelphia: WB Saunders; 1994.
2. Tauber M, Resch H, Forstner R, Raffl M, Schauer J. Reasons for failure after surgical repair of anterior shoulder instability. *J Shoulder Elbow Surg* 2004;13:279-285.
3. Miniaci A, Haynes DE, Williams GR Jr, Iannotti JP. Anterior and anteroinferior instability: Open and arthroscopic management. In: Iannotti JP, Williams GR Jr, eds. *Disorders of the shoulder: Diagnosis & management*. Ed 2. Philadelphia: Lippincott Williams & Wilkins; 2006:369-396.
4. Arciero RA, Spang JT. Complications in arthroscopic anterior shoulder stabilization: Pearls and pitfalls. *Instr Course Lect* 2008;57:113-124.
5. Boileau P, Villalba M, Héry JY, Balg F, Ahrens P, Neyton L. Risk factors for recurrence of shoulder instability after arthroscopic Bankart repair. *J Bone Joint Surg Am* 2006;88:1755-1763.
6. Burkhart SS, De Beer JF. Traumatic glenohumeral bone defects and their relationship to failure of arthroscopic Bankart repairs: Significance of the inverted-pear glenoid and the humeral engaging Hill-Sachs lesion. *Arthroscopy* 2000;16:677-694.
7. Kim SH, Ha KI, Cho YB, Ryu BD, Oh I. Arthroscopic anterior stabilization of the shoulder: Two to six-year follow-up. *J Bone Joint Surg Am* 2003;85:1511-1518.
8. Hawkins RH, Hawkins RJ. Failed anterior reconstruction for shoulder instability. *J Bone Joint Surg Br* 1985;67:709-714.

9. McAuliffe TB, Pangayatselvan T, Bayley I. Failed surgery for recurrent anterior dislocation of the shoulder. Causes and management. *J Bone Joint Surg Br* 1988;70:798-801.
10. Burkhead WZ Jr, Ritchie MF. Revision of failed shoulder reconstruction. *Contemp Orthop* 1992;24:126-133.
11. Rowe CR, Pierce DS, Clark JG. Voluntary dislocation of the shoulder. A preliminary report on a clinical, electromyographic, and psychiatric study of twenty-six patients. *J Bone Joint Surg Am* 1973;55:445-460.
12. Provencher MT, Bell SJ, Menzel KA, Mologne TS. Arthroscopic treatment of posterior shoulder instability: Results in 33 patients. *Am J Sports Med* 2005;33:1463-1471.
13. Carter CW, Moros C, Ahmad CS, Levine WN. Arthroscopic anterior shoulder instability repair: Techniques, pearls, pitfalls, and complications. *Instr Course Lect* 2008;57:125-132.
14. Neviasser TJ. The anterior labroligamentous periosteal sleeve avulsion lesion: A cause of anterior instability of the shoulder. *Arthroscopy* 1993;9:17-21.
15. Wolf EM, Cheng JC, Dickson K. Humeral avulsion of glenohumeral ligaments as a cause of anterior shoulder instability. *Arthroscopy* 1995;11:600-607.
16. Bach BR, Warren RF, Fronck J. Disruption of the lateral capsule of the shoulder. A cause of recurrent dislocation. *J Bone Joint Surg Br* 1988;70:274-276.
17. Matsen FA III, Thomas SC, Rockwood CA Jr. Anterior glenohumeral stability. In: Rockwood CA Jr, Matsen FA III, eds. *The shoulder*. Vol 1. Philadelphia: WB Saunders; 1990:547-551.
18. Bankart AS. The pathology and treatment of recurrent dislocation of the shoulder joint. *Brit J Surg* 1938;26:23-29.
19. Rowe CR, Patel D, Southmayd WW. The Bankart procedure: A long-term end-result study. *J Bone Joint Surg Am* 1978;60:1-16.
20. Thomas SC, Matsen FA III. An approach to the repair of avulsion of the glenohumeral ligaments in the management of traumatic anterior glenohumeral instability. *J Bone Joint Surg Am* 1989;71:506-513.
21. Lazarus MD, Harryman DT II. Complications of open anterior stabilization of the shoulder. *J Am Acad Orthop Surg* 2000;8:122-132.
22. Segmuller HE, Hayes MG, Saies AD. Arthroscopic repair of glenolabral injuries with an absorbable fixation device. *J Shoulder Elbow Surg* 1997;6:383-392.
23. Steinbeck J, Jerosch J. Arthroscopic transglenoid stabilization versus open anchor suturing in traumatic anterior instability of the shoulder. *Am J Sports Med* 1998;26:373-378.
24. Wolf EM. Arthroscopic capsulolabral repair using suture anchors. *Orthop Clin North Am* 1993;24:59-69.
25. Shaffer BS, Tibone JE. Arthroscopic shoulder instability surgery. Complications. *Clin Sports Med* 1999;18:737-767.
26. Loomer R, Graham B. Anatomy of the axillary nerve and its relation to inferior capsular shift. *Clin Orthop Relat Res* 1989:100-105.
27. Eglseder WA Jr, Goldman M. Anatomic variations of the musculocutaneous nerve in the arm. *Am J Orthop* 1997;26:777-780.
28. Mair SD, Hawkins RJ. Open shoulder instability surgery. Complications. *Clin Sports Med* 1999;18:719-736.
29. Ho E, Cofield RH, Balm MR, Hatrup SJ, Rowland CM. Neurologic complications of surgery for anterior shoulder instability. *J Shoulder Elbow Surg* 1999;8:266-270.
30. Brown AR, Weiss R, Greenberg C, Flatow EL, Bigliani LU. Interscalene block for shoulder arthroscopy: Comparison with general anesthesia. *Arthroscopy* 1993;9:295-300.
31. Borgeat A, Ekatodramis G, Kalberer F, Benz C. Acute and nonacute complications associated with interscalene block and shoulder surgery: A prospective study. *Anesthesiology* 2001;95:875-880.
32. Plit ML, Chhajed PN, Macdonald P, Cole IE, Harrison GA. Bilateral vocal cord palsy following interscalene brachial plexus nerve block. *Anaesth Intensive Care* 2002;30:499-501.
33. Kempen PM, O'Donnell J, Lawler R, Mantha V. Acute respiratory insufficiency during interscalene plexus block. *Anesth Analg* 2000;90:1415-1416.
34. Flowers GA, Meyers JF. Pseudoaneurysm after interscalene block for a rotator cuff repair. *Arthroscopy* 2004;20:67-69 (Suppl 2).
35. Ekatodramis G, Macaire P, Borgeat A. Prolonged Horner syndrome due to neck hematoma after continuous interscalene block. *Anesthesiology* 2001;95:801-803.
36. Freehill MQ, Harms DJ, Huber SM, Atlihan D, Buss DD. Poly-L-lactic acid tack synovitis after arthroscopic stabilization of the shoulder. *Am J Sports Med* 2003;31:643-647.
37. Sassmannshausen G, Sukay M, Mair SD. Broken or dislodged poly-L-lactic acid bioabsorbable tacks in patients after SLAP lesion surgery. *Arthroscopy* 2006;22:615-619.
38. Zuckerman JD, Matsen FA III. Complications about the glenohumeral joint related to the use of screws and staples. *J Bone Joint Surg Am* 1984;66:175-180.
39. Gomoll AH, Kang RW, Williams JM, Bach BR, Cole BJ. Chondrolysis after continuous intra-articular bupivacaine infusion: An experimental model investigating chondrotoxicity in the rabbit shoulder. *Arthroscopy* 2006;22:813-819.
40. Hansen BP, Beck CL, Beck EP, Townsley RW. Postarthroscopic glenohumeral chondrolysis. *Am J Sports Med* 2007;35:1628-1634.
41. Good CR, Shindle MK, Kelly BT, Wanich T, Warren RF. Glenohumeral chondrolysis after shoulder arthroscopy with thermal capsulorrhaphy. *Arthroscopy* 2007;23:797.e1-797.e5. Available online at www.arthroscopyjournal.org.
42. McNickle AG, L'heureux DR, Provencher MT, Romeo AA, Cole BJ. Post surgical glenohumeral chondrolysis in young adults. *Am J Sports Med*, in press.
43. Cole BJ, Romeo AA. Arthroscopic shoulder stabilization with suture anchors: Technique, technology, and pitfalls. *Clin Orthop Relat Res* 2001:17-30.
44. Mazzocca AD, Brown FM Jr, Carreira DS, Hayden J, Romeo AA. Arthroscopic anterior shoulder stabilization of collision and contact athletes. *Am J Sports Med* 2005;33:52-60.
45. Mologne TS, Provencher MT, Menzel KA, Vachon TA, Dewing CB. Arthroscopic stabilization in patients with an inverted pear glenoid: Results in patients with bone loss of the anterior glenoid. *Am J Sports Med* 2007;35:1276-1283.
46. Sugaya H, Moriishi J, Kanisawa I, Tsuchiya A. Arthroscopic osseous Bankart repair for chronic recurrent traumatic anterior glenohumeral instability. Surgical technique. *J Bone Joint Surg Am* 2006;88:159-169 (Suppl 1, pt 2).
47. Provencher MT, Detterline AJ, Ghodadra N, et al. Measurement of glenoid bone loss: A comparison of measurement error between 45 degrees and 0 degrees bone loss models and with different posterior arthroscopy portal locations. *Am J Sports Med* 2008;36:1132-1138.
48. Karlsson J, Magnusson L, Ejerhed L, Hultenheim I, Lundin O, Kartus J. Comparison of open and arthroscopic stabilization for recurrent shoulder dislocation in patients with a Bankart lesion. *Am J Sports Med* 2001;29:538-542.
49. Regan WD Jr, Webster-Bogaert S, Hawkins RJ, Fowler PJ. Comparative functional analysis of the Bristow, Magnuson-Stack, and Putti-Platt procedures for recurrent dislocation of the shoulder. *Am J Sports Med* 1989;17:42-48.
50. Rosenberg BN, Richmond JC, Levine WN. Long-term followup of Bankart reconstruction. Incidence of late degenerative glenohumeral arthrosis. *Am J Sports Med* 1995;23:538-544.
51. MacDonald PB, Hawkins RJ, Fowler PJ, Miniaci A. Release of the subscapularis for internal rotation contracture and pain

- after anterior repair for recurrent anterior dislocation of the shoulder. *J Bone Joint Surg Am* 1992;74:734-737.
52. Hovelius L, Akermark C, Albrektsson B, et al. Bristow-Latarjet procedure for recurrent anterior dislocation of the shoulder. A 2-5 year follow-up study on the results of 112 cases. *Acta Orthop Scand* 1983;54:284-290.
 53. Sachs RA, Williams B, Stone ML, Paxton L, Kuney M. Open Bankart repair: Correlation of results with postoperative subscapularis function. *Am J Sports Med* 2005;33:1458-1462.
 54. Scheibel M, Tsynman A, Magosch P, Schroeder RJ, Habermeyer P. Postoperative subscapularis muscle insufficiency after primary and revision open shoulder stabilization. *Am J Sports Med* 2006;34:1586-1593.
 55. Greis PE, Dean M, Hawkins RJ. Subscapularis tendon disruption after Bankart reconstruction for anterior instability. *J Shoulder Elbow Surg* 1996;5:219-222.
 56. Gill TJ, Micheli LJ, Gebhard F, Binder C. Bankart repair for anterior instability of the shoulder. Long-term outcome. *J Bone Joint Surg Am* 1997;79:850-857.
 57. Wall MS, Warren RF. Complications of shoulder instability surgery. *Clin Sports Med* 1995;14:973-1000.
 58. Buscayret F, Edwards TB, Szabo I, Adeleine P, Coudane H, Walch G. Glenohumeral arthrosis in anterior instability before and after surgical treatment: Incidence and contributing factors. *Am J Sports Med* 2004;32:1165-1172.
 59. Pelet S, Jolles BM, Farron A. Bankart repair for recurrent anterior glenohumeral instability: Results at twenty-nine years' follow-up. *J Shoulder Elbow Surg* 2006;15:203-207.
 60. Hovelius L, Olofsson A, Sandstrom B, et al. Nonoperative treatment of primary anterior shoulder dislocation in patients forty years of age and younger. a prospective twenty-five-year follow-up. *J Bone Joint Surg Am* 2008;90:945-952.
 61. McFarland EG, O'Neill OR, Hsu CY. Complications of shoulder arthroscopy. *J South Orthop Assoc* 1997;6:190-196.
 62. Green MR, Christensen KP. Arthroscopic Bankart procedure: Two- to five-year followup with clinical correlation to severity of glenoid labral lesion. *Am J Sports Med* 1995; 23:276-281.