

# A New Arthroscopic Technique to Determine Anterior-Inferior Glenoid Bone Loss: Validation of the Secant Chord Theory in a Cadaveric Model

Alvin J. Detterline, M.D., CDR Matthew T. Provencher, M.D., MC, USN,  
Neil Ghodadra, M.D., Bernard R. Bach Jr., M.D., Anthony A. Romeo, M.D.,  
and Nikhil N. Verma, M.D.

---

**Purpose:** The accuracy of a previously described method using the glenoid bare spot (GBS) as a reference point was compared with a new method using the secant chord theory (SCT), which relies on the circular geometry of the inferior glenoid to calculate bone loss. **Methods:** In 7 embalmed cadaveric shoulders a digital image of the glenoid face was used to calculate the area of the best-fit circle of the inferior glenoid. Osteotomy templates from the 3-o'clock to 6-o'clock position were created to make a simulated anterior-inferior bone defect of 12.5% and 25% of the area of the circle. Measurements were taken with an arthroscopic probe from 2 simulated posterior portal positions (9 and 10 o'clock) by use of 2 techniques—SCT and GBS—in the intact, 12.5% loss, and 25% loss states. **Results:** In the intact state, measurements showed a mean SCT loss of 4.1% and GBS loss of 4.4%. In the 12.5% loss state, mean percent bone loss with GBS was 23.1% compared with 14.8% with SCT ( $P = .0001$ ) at the 10-o'clock portal and 22.2% compared with 15.9% ( $P = .006$ ) at the 9-o'clock portal. In the 25% loss state, mean percent bone loss with GBS was 31.5% compared with 26.6% with SCT ( $P = .002$ ) at the 10-o'clock portal and 30.4% compared with 28.9% ( $P = .48$ ) at the 9-o'clock portal. **Conclusions:** The SCT is shown to be a more accurate method of determining glenoid bone loss in an arthroscopic model; however, additional mathematic calculations are necessary. As shown in the intact state, there is an inherent small error of approximately 4% when arthroscopically determining bone loss. **Clinical Relevance:** The technique may aid the clinician in quantifying glenoid bone loss and help determine when bone augmentation may be advisable. **Key Words:** Shoulder instability—Glenoid bone loss—Shoulder arthroscopy.

---

Arthroscopic treatment of anterior shoulder instability has grown in popularity in recent years, with results comparable to open stabilization.<sup>1-4</sup> How-

ever, satisfactory outcomes are dependent on appropriate patient selection. It has been well documented that patients with soft-tissue incompetence,<sup>5-7</sup> humeral head deficiencies,<sup>5,8-10</sup> or glenoid bone loss<sup>5,11-13</sup> have higher failure rates than patients without these abnormalities. Specifically, much attention has been given to glenoid bone loss as a reason for failure of arthroscopic anterior stabilization techniques. Burkhart and De Beer<sup>14</sup> emphasized this point when they showed a markedly increased failure rate (67% v 4%) in arthroscopic stabilization when significant bone loss was present on the glenoid, causing an “inverted-pear” appearance.<sup>15</sup>

Various techniques have been used to identify the presence of glenoid bone loss both preoperatively and intraoperatively. Techniques using plain radiographs such as the apical oblique<sup>16</sup> and West Point<sup>17</sup> views have been described. Sugaya et al.<sup>18</sup> have popularized the use of computed tomography (CT) reconstructions

---

From the Department of Orthopedic Surgery (A.J.D., M.T.P., N.G., B.R.B., A.A.R., N.N.V.), Division of Sports Medicine (B.R.B.), and Shoulder and Elbow Section (A.A.R.), Rush University Medical Center, Chicago, Illinois, and Department of Orthopaedic Shoulder, Knee and Sports Surgery, Naval Medical Center San Diego (M.T.P.), San Diego, California, U.S.A.

The views expressed in this article are those of the authors and do not reflect the official policy or position of the Department of the Navy, Department of Defence, or the United States government.

The authors report no conflict of interest.

Received November 20, 2008; accepted May 23, 2009.

Address correspondence and reprint requests to Alvin J. Detterline, M.D., Towson Orthopaedic Associates, Ruxton Professional Center, 8322 Bellona Ave, Ste 100, Baltimore, MD 21204-2012, U.S.A. E-mail: [adetterlinemd@gmail.com](mailto:adetterlinemd@gmail.com)

© 2009 by the Arthroscopy Association of North America

0749-8063/09/2511-8660\$36.00/0

doi:10.1016/j.arthro.2009.05.019

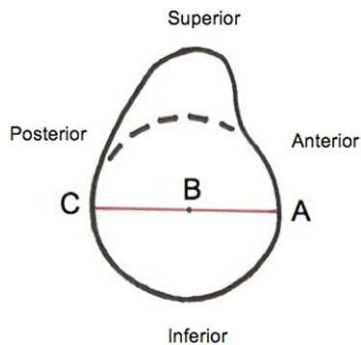


FIGURE 1. GBS method of calculating glenoid bone loss. Percent bone loss is equal to  $(BC - AB)/(BC \times 2)$ .

to calculate the area of glenoid bone loss. Burkhart et al.<sup>19</sup> have advocated an arthroscopic technique that uses the bare spot of the glenoid as a reference point. In this technique the arthroscope is placed in the anterosuperior portal, and a graduated arthroscopic probe is placed in the posterior portal. By use of the glenoid bare spot (GBS) as the center reference point (B), the distance from the bare spot to the anterior rim of the glenoid (AB) is compared with the distance from the bare spot to the posterior rim (BC) (Fig 1). In an intact glenoid this measurement should be equal. If glenoid bone loss is present, AB will be less than BC; the percent bone loss can be calculated as follows:  $(BC - AB)/(BC \times 2)$ .

Other authors have called into question the validity of using the bare spot as a central reference point.<sup>20,21</sup> Kralinger et al.<sup>20</sup> have shown that the GBS is actually not the center of the inferior portion of the glenoid, but instead, it was found to be located approximately 1.4 mm anterior to the true center of the glenoid. If the reference point for this technique is not exactly in the center of the glenoid, an incorrect assessment of glenoid bone loss will result. Furthermore, this arthroscopic technique was described with the use of 1 posterior portal. With many surgeons varying the location of the posterior arthroscopic portal, it remains unclear whether the GBS can reliably be reached with different posterior portal positions by use of the arthroscopic probe and whether the change in portal position results in a change in measured percentage loss.

Although the accuracy of the GBS has been brought into question in the literature, there have been numerous reports that show the inferior portion of the glenoid to be reliably circular.<sup>18,21,22</sup> With this information, it would seem logical that an arthroscopic technique that uses the circular geometry of the infe-

rior glenoid without using the bare spot as a reference might be an alternative way of measuring glenoid bone loss arthroscopically. To our knowledge, no technique using these principles has been described in the literature.

The purpose of this study was to validate a technique to measure the amount of anterior-inferior glenoid bone loss using the secant chord method. The hypothesis was that the secant chord theory (SCT) technique is more accurate than using the bare spot as a central reference point in measuring the amount of glenoid bone loss present by use of an arthroscopic model of anterior shoulder instability.

## METHODS

We inspected 7 embalmed cadaveric shoulders (4 right and 3 left; 4 female and 3 male; mean age, 81 years; age range, 56 to 90 years) and determined that they were free of significant articular cartilage wear and glenoid bone loss. All specimens showed no evidence of previous shoulder surgery. The scapulae were dissected free of all soft tissue. A digital image was taken of the face of the glenoid with a 30-mm sizing marker placed next to and level with the articular surface of the glenoid. The digital images of the glenoid faces were uploaded into a personal computer, and a best-fit circle of the inferior two thirds of the glenoid was determined by use of commercial software (Adobe Photoshop CS [Adobe, San Jose, CA] and Universal Desktop Ruler [AVPSoft, Moscow, Russian Federation]). The area of the best-fit circle was calculated in square millimeters after it was digitally calibrated with the sizing marker.

Glenoid osteotomy templates were created at 45° in relation to the longitudinal axis of the glenoid to make a simulated anterior-inferior glenoid bone defect of 12.5% and 25% of the area of the best-fit circle of the inferior glenoid by use of the computer software. The defect was created between the 3-o'clock and 6-o'clock positions on the glenoid face (right shoulder). To create the bone loss states, the computer-generated templates were superimposed over the glenoid specimens, and a high-speed rotary (The Black & Decker Corporation, Towson, MD) saw set to 15,000 rpm to minimize bone loss was used to create the osteotomies (Fig 2). Care was taken to ensure that the template remained in place after each osteotomy to ensure that the correct amount of bone was removed.

The scapulae were mounted in a custom apparatus that had a pivoting arm that allowed for simulation of

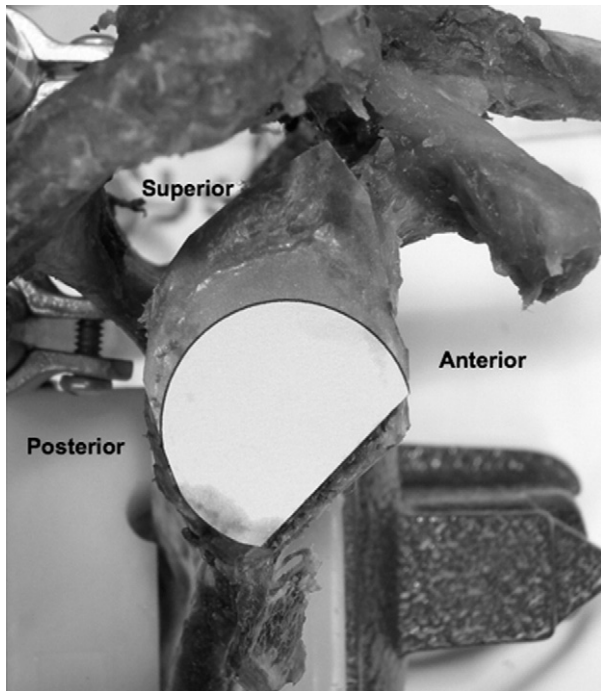


FIGURE 2. Template used to create a glenoid osteotomy with 25% area loss.

a posterior arthroscopic portal (Fig 3). The arm could be adjusted such that the “posterior portal” could be fixed at either the 10-o’clock or 9-o’clock position for a right shoulder and the 2-o’clock or 3-o’clock position for a left shoulder with the supraglenoid tubercle representing the 12-o’clock position in all specimens.




FIGURE 3. Custom glenoid apparatus simulating arthroscopic conditions with a pivoting posterior portal through which a probe is inserted.

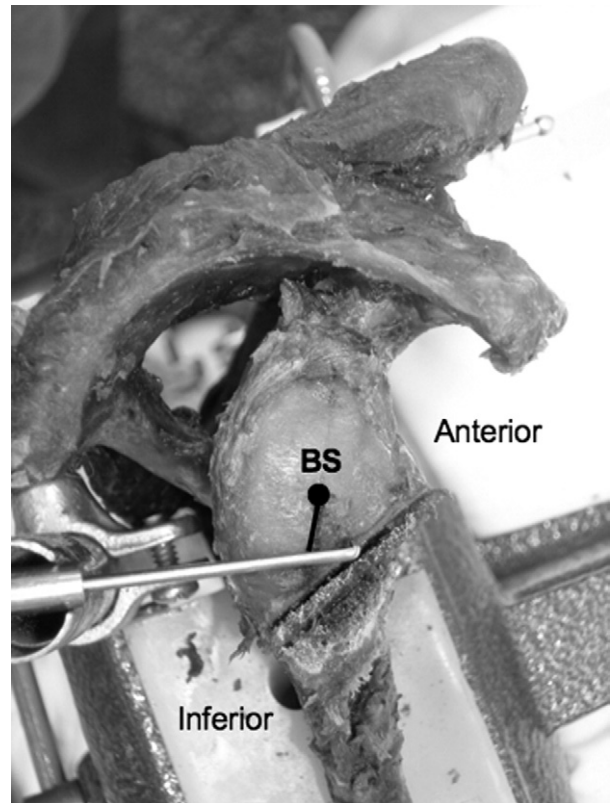


FIGURE 4. The probe is inserted through the posterior portal and advanced to the midpoint of anterior bone loss. It should be noted that the probe does not pass through the bare spot (BS) through this portal position. The bare spot is extrapolated to the probe in this instance for measurement with the GBS technique.

A depth gauge with an attached digital caliper was placed in the “posterior portal” to simulate a graduated arthroscopic probe for measurement purposes. All measurements with the digital calipers were made to the nearest 0.1 mm.

The specimens were measured by 2 independent observers from the 2 portal positions (10 o’clock and 9 o’clock) by 2 different techniques in the intact, 12.5% bone loss, and 25% bone loss states. The GBS measurement technique relied on the bare spot of the glenoid as the center reference point as popularized by Burkhart and colleagues.<sup>15,19</sup> The distance from the anterior rim to the bare spot was compared with the distance from the posterior rim to the bare spot. The difference between the 2 distances was divided by the distance from the posterior rim to the bare spot multiplied by 2 to calculate the percent bone loss. As shown in Fig 4, the arthroscopic probe represented a line connecting the posterior portal to the midpoint of the bony defect on the anterior glenoid rim. These 2

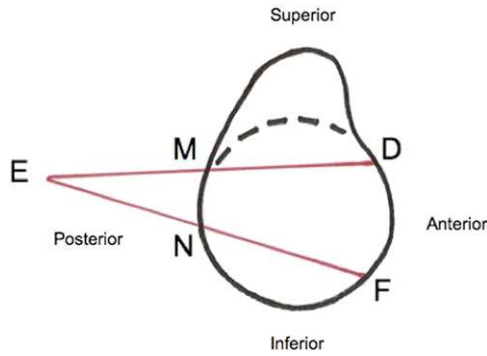


FIGURE 5. SCT method of calculating bone loss. According to the geometric theorem,  $FN = (DE \times ME/NE) - NE$ .

points defined the line; in certain instances, this line did not include the GBS. When this occurred, the bare spot position was extrapolated to the closest point on the line created by the arthroscopic probe.

A second measurement technique was then performed by use of the SCT to calculate percent bone loss. In circular geometry<sup>23,24</sup> a secant is defined as a line that intersects 2 points on a circle but extends beyond the circumference of the circle. The secant (DE) can be divided into an internal segment, or chord (DM), and an external segment (ME) (Fig 5). A mathematic theorem has been proved that when 2 secants share an endpoint outside the circle, the products of the secant length and its external segment are equal. Thus the following equation is derived (SCT):  $DE \times ME = FE \times NE$ . If  $FE = NE + FN$ , then the equation can be modified to  $DE \times ME = (NE + FN) \times NE$ . By use of basic algebra, it is possible to solve for FN. The equation then becomes  $FN = (DE \times ME/NE) - NE$ .

If anterior-inferior bone loss is present, the chord FN as shown in Fig 6 will be the only segment affected. The lengths of the segments DE, ME, and NE will remain the same. Thus, if one can measure the segments DE, ME, and NE directly, it is possible to calculate what the expected length of the segment FN should be in the intact glenoid state where the inferior portion of the glenoid represents a true circle. This calculated value for FN can then be compared with the directly measured length of the segment FN. The difference between the calculated value of FN ( $FN_{calc}$ ) and measured value of FN ( $FN_{meas}$ ) can be used to determine percent bone loss by use of the following equation: Percent bone loss =  $(FN_{calc} - FN_{meas})/FN_{calc}$ .

In this arthroscopic model (Fig 6), point E represents the posterior portal location, point D represents

a point on the anterior rim not affected by bone loss, and point  $F_{meas}$  represents a point on the anterior-inferior rim where bone loss would occur. The probe served as a line connecting points E and D, and thus point M was the point where the probe crossed the posterior rim of the glenoid. Therefore we directly measured the lengths of the segments DE and ME. The probe was then repositioned to represent a line connecting points E and  $F_{meas}$ , and point N was the point where the probe intersected the posterior rim of the glenoid. We then measured the lengths of the segments NE and  $FN_{meas}$ . With these raw data, we were able to calculate the expected value of FN ( $FN_{calc}$ ) and compare it with the actual measured value of FN ( $FN_{meas}$ ) to determine percent bone loss.

The measurements of either GBS or SCT were randomized to prevent an order effect of sequential measurements. The percent bone loss calculated by use of the 2 techniques was compared with the actual bone loss for the intact, 12.5% loss, and 25% loss states at each portal position to determine the accuracy of each method. The measurements of glenoid bone loss obtained by each technique were compared by use of Wilcoxon signed rank tests, and the differences in bone loss measurements obtained between the 2 posterior portal positions were compared by use of the Wilcoxon–Mann-Whitney test. The level of significance was set at  $P < .05$ .

## RESULTS

The results of the study are summarized in Table 1. In the intact state there was no statistical difference in calculated bone loss between techniques at either por-

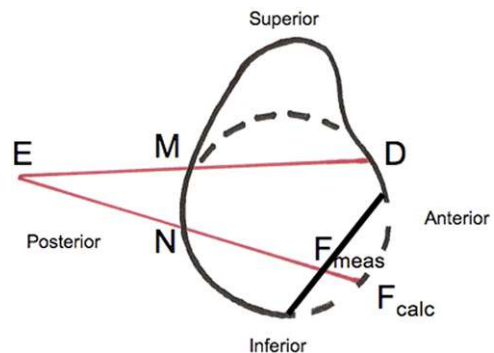


FIGURE 6. With anterior bone loss present, the measured chord FN ( $F_{meas}N$ ) will be less than the calculated value of FN ( $F_{calc}N$ ) because the inferior portion of the glenoid is no longer circular. Percent bone loss is equal to  $(FN_{calc} - FN_{meas})/FN_{calc}$ .

**TABLE 1.** Summary of Calculated Percent Bone Loss in Intact, 12.5% Loss, and 25% Loss States at 10-o'clock and 9-o'clock Portal Positions

	Intact	12.5% Loss	25% Loss
10 o'clock			
GBS	5.8% (2.1%)	23.1% (5.2%)	31.5% (3.2%)
SCT	3.0% (1.8%)	14.8% (4.1%)	26.6% (3.8%)
<i>P</i> value	.56	.0001*	.002*
9 o'clock			
GBS	3.3% (2.0%)	22.2% (5.3%)	30.4% (5.1%)
SCT	4.5% (2.1%)	15.9% (4.3%)	28.9% (4.8%)
<i>P</i> value	.42	.006*	.48

NOTE. Data are given as mean (standard deviation).

\*Denotes statistical significance.

tal position ( $P = .56$  at 10 o'clock and  $P = .42$  at 9 o'clock). In the 12.5% loss state there was a significant difference between the mean percent bone loss with the GBS technique versus the SCT technique at both portal positions (23.1% v 14.8%,  $P = .0001$ ; 22.2% v 15.9%,  $P = .006$ ). In the 25% bone loss state there was a significant difference between the GBS technique and the SCT technique at the 10-o'clock position (31.5% v 26.6%,  $P = .002$ ) but not at the 9-o'clock position (30.4% v 28.9%,  $P = .48$ ). The mean interobserver and intraobserver interclass correlation coefficients were 0.789 and 0.882, respectively.

## DISCUSSION

The principal findings of our study show that the SCT can serve as an accurate method to measure glenoid bone loss and help aid the clinician in determining when glenoid bone augmentation may be advisable because of the higher risk of recurrent instability. In this study we have developed a novel technique for measuring bone loss based on the SCT.

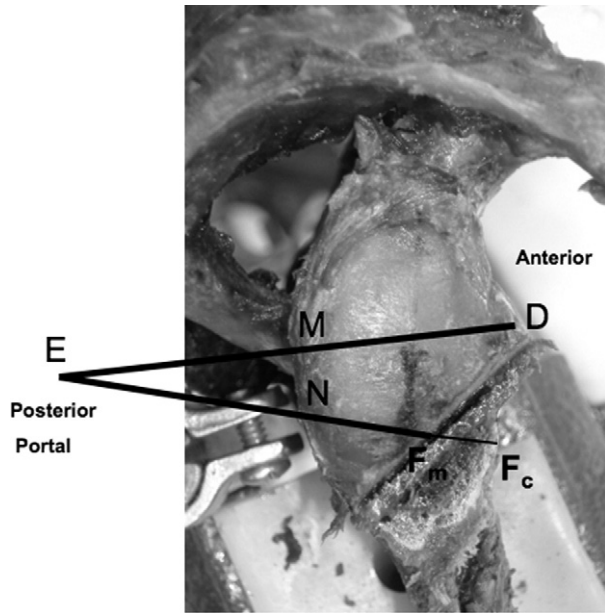
There have been several techniques described to measure the amount of glenoid bone loss present both radiographically and arthroscopically.<sup>16-19</sup> Sugaya et al.<sup>18</sup> have described the use of 3-dimensional CT imaging with humeral head subtraction to visualize the face of the glenoid and determine whether bone loss is present. They calculated bone loss by fitting the inferior portion of the glenoid to a true circle, calculating its area, and then calculating the area of the missing osseous fragment. The ratio of the area of the osseous fragment to the area of the glenoid circle determined the percent bone loss present.

In our study this technique was mimicked by taking a scaled digital photograph of the face of the glenoid,

fitting a circle to the inferior glenoid, calculating its area, and then creating osteotomies in the anterior-inferior quadrant to create 12.5% and 25% area loss states. We believe that this is an accurate method of measuring bone loss because the inferior portion of the glenoid is a true circle, as has been shown in several studies.<sup>18,21,22,25</sup> Most notably, Huysmans et al.<sup>21</sup> noted that in 39 of 40 scapulae studied, the inferior glenoid had the shape of a true circle, which they defined as missing parts comprising less than 1% of the surface of the drawn best-fit circle.

From an arthroscopic standpoint, Burkhart et al.<sup>19</sup> have popularized the use of the GBS as a central reference point to calculate percent bone loss present. However, other authors have questioned the accuracy of the bare spot as a reference point.<sup>20,21</sup> Aigner et al.<sup>26</sup> found the bare spot to be eccentric in most shoulders. Kralinger et al.<sup>20</sup> found the bare spot to be a mean 1.4 mm anterior to the true center of the inferior glenoid when critically looking at its location using 3-dimensional reconstructed CT scans of 20 embalmed cadaveric glenoids. They also commented that in many specimens, the bare spot was either not well visualized or irregular. In another cadaveric study Huysmans et al.<sup>21</sup> found the bare spot to be slightly eccentrically located in 40 shoulders; however, they concluded that because the differences were so small, the bare spot could be used as a reference point to obtain global information but not for exact measurements.

Because of the reported controversy surrounding the validity and accuracy of the GBS, we devised the SCT technique that allows for arthroscopic calculation of glenoid bone loss without the use of the bare spot. To use this technique, the surgeon places the arthroscope in the anterior portal to allow for visualization of the glenoid. A graduated arthroscopic probe is then inserted through the posterior portal. As described in the "Methods" section, the arthroscopist can measure the lengths of the segments of the secant lines that would not be affected by anterior-inferior glenoid bone loss (DE, ME, and NE in Fig 7). This will allow the surgeon to calculate the expected length of the chord of the secant that would be affected by bone loss ( $F_cN$  in Fig 7) and compare it with the actual measured length of the chord ( $F_mN$  in Fig 7) to determine percent bone loss present. Because the SCT method relies only on the circular geometry of the inferior portion of the glenoid and not the bare spot, it can be used in many different settings of bone loss regardless of shape or orientation. It should be noted that even with a completely intact glenoid, the amount of bone



**FIGURE 7.** In the arthroscopic setting point E represents the posterior portal position. Point D is a spot on the anterior glenoid rim not affected by bone loss. Points M and N are points where the probe would intersect the posterior glenoid rim. The arthroscopist can measure the segments DE, ME, and NE, which will allow for calculation of the segment  $F_cN$  by the SCT. The segment  $F_mN$  can directly be measured and compared with the value calculated for  $F_cN$  to determine the amount of bone loss present.

loss measured by either technique in this study ranged from 3.0% to 5.8%; thus there is an inherent built-in error of approximately 4% that should be kept in mind when arthroscopically determining bone loss.

The prevalence of glenoid bone loss as a result of recurrent anterior shoulder dislocations varies widely in the literature, ranging from 8% to 95%.<sup>12,25,27-33</sup> In a recent study Lo et al.<sup>15</sup> reported that a majority of patients (64%) undergoing arthroscopic shoulder stabilization for anterior instability showed some degree of bone loss. Therefore they recommended accurate quantification of glenoid bone loss in all shoulder instability patients.

Despite the known prevalence of bone loss in instability patients, the significance remains somewhat controversial. Furthermore, the maximal amount of bone loss acceptable during soft-tissue arthroscopic stabilization remains poorly defined. Itoi et al.<sup>34</sup> showed that less translational force was required to produce anterior instability with as little as 21% bone loss in a cadaveric model. Burkhart and De Beer<sup>14</sup> showed a markedly higher failure rate (67% v 4%) in patients in whom an inverted-pear glenoid was present, signifying significant glenoid bone loss. Big-

liani et al.<sup>11</sup> recommended coracoid transfer in patients who had greater than 25% bone loss because of higher failure rates. Mologne et al.<sup>35</sup> recommended incorporating the bony Bankart lesion into the arthroscopic repair when possible and showed improved results (9.5% subluxation rate and 4.8% dislocation rate), yet they cautioned that results are less predictable when attritional bone loss is present.

When comparing the 2 methods, we found that the bare spot method overestimated the amount of bone loss present, regardless of posterior portal location, in both the small (12.5%) and large (25%) area loss states but to a much more significant degree when a small bony defect was created (22% to 23% in 12.5% loss state compared with 30% to 31.5% in 25% loss state). This is likely because of a couple of factors. First, the bare spot location is slightly anterior to the true center of the glenoid. Second, and more importantly, the arthroscopic probe serves as a line connecting the posterior portal to the center of the anterior-inferior bony defect, although it does not always pass through the bare spot. This can introduce error by inaccurately extrapolating the bare spot to the line defined by the arthroscopic probe. We found this to be true regardless of whether the posterior portal was placed at the 10-o'clock or 9-o'clock position. Because the secant method does not incorporate the bare spot into its determination of bone loss and instead uses a relation of chords and secants, it avoids this potential inaccuracy.

We believe the secant method of determining glenoid bone loss has several advantages. First, it eliminates the need to use the bare spot as a reference point. If the bare spot is poorly visualized or eccentrically located, it may be difficult to use as an accurate point of reference. Second, the technique can be performed arthroscopically to help guide intraoperative treatment decisions. Finally, in our study it was found to be more accurate in predicting actual bone loss compared with the GBS method in this cadaveric model. However, the secant method does involve a much more complex mathematic calculation, which cannot be performed without the use of a calculator. With the increasing availability of technology present in the operating room, we do not believe this to be a significant hindrance to its use.

The major limitation of the secant chord method is that it requires an anterior superior reference point such that the superior chord measurement is unaffected by the bone loss present. If the anterior glenoid bone loss is extensive, the ratio of secants would no longer allow for accurate computation of bone loss

because both chords would be less than expected. This would produce a result that would underestimate the amount of bone loss present. Further clinical study will be required to determine how often this clinical scenario is present. Additional limitations include that this study was performed in a simulated arthroscopic environment, which may not mimic true intraoperative conditions. The humeral head was absent and thus did not affect visualization of the face of the glenoid, and the labrum was removed circumferentially around the glenoid so that the bony rim could easily be identified. In addition, the assimilated arthroscopic portal had a well-defined endpoint from which to measure. In the true arthroscopic setting the posterior portal location would be defined as the edge of the skin or portal, which might not be as well defined or consistent because of soft-tissue swelling and skin pliability. Furthermore, our measurements were made to the nearest 0.1 mm with a digital caliper. Certainly, there is no arthroscopic probe that would provide that amount of precision, and errors in measurement will affect the accuracy of the calculation by use of both techniques. Finally, the posterior portal location was not precisely measured to be placed at the 10-o'clock and 9-o'clock positions, which may have resulted in slight variation in portal location; but because no significant differences in measurements were noted between the 2 portal locations, this likely did not have any significant impact on the results.

## CONCLUSIONS

The SCT was shown to be a more accurate method of determining glenoid bone loss when compared with the GBS technique in this arthroscopic cadaveric model; however, additional mathematic calculations are necessary. As shown in the intact state, there is an inherent small error of approximately 4% when arthroscopically determining bone loss.

## REFERENCES

1. Bottoni CR, Smith EL, Berkowitz MJ, Towle RB, Moore JH. Arthroscopic versus open shoulder stabilization for recurrent anterior instability: A prospective randomized clinical trial. *Am J Sports Med* 2006;34:1730-1737.
2. Freedman KB, Smith AP, Romeo AA, Cole BJ, Bach BR Jr. Open Bankart repair versus arthroscopic repair with transglenoid sutures or bioabsorbable tacks for recurrent anterior instability of the shoulder: A meta-analysis. *Am J Sports Med* 2004;32:1520-1527.
3. Cole BJ, L'Insalata J, Irrgang J, Warner JJ. Comparison of arthroscopic and open anterior shoulder stabilization. A two to six-year follow-up study. *J Bone Joint Surg Am* 2000;82:1108-1114.
4. Larrain MV, Montenegro HJ, Mauas DM, Collazo CC, Pavón F. Arthroscopic management of traumatic anterior shoulder instability in collision athletes: Analysis of 204 cases with a 4- to 9-year follow-up and results with the suture anchor technique. *Arthroscopy* 2006;22:1283-1289.
5. Boileau P, Villalba M, Héry JY, Balg F, Ahrens P, Neyton L. Risk factors for recurrence of shoulder instability after arthroscopic Bankart repair. *J Bone Joint Surg Am* 2006;88:1755-1763.
6. Speer KP, Warren RF, Pagnani M, Warner JJ. An arthroscopic technique for anterior stabilization of the shoulder with a bioabsorbable tack. *J Bone Joint Surg Am* 1996;78:1801-1807.
7. Mologne TS, McBride MT, Lapoint JM. Assessment of failed arthroscopic anterior labral repairs. Findings at open surgery. *Am J Sports Med* 1997;25:813-817.
8. Calandra JJ, Baker CL, Uribe J. The incidence of Hill-Sachs lesions in initial anterior shoulder dislocations. *Arthroscopy* 1989;5:254-257.
9. Rowe CR, Zarins B, Ciullo JV. Recurrent anterior dislocation of the shoulder after surgical repair. Apparent causes of failure and treatment. *J Bone Joint Surg Am* 1984;66:159-168.
10. Hill HA, Sachs MD. The groove defect of the humeral head. A frequently unrecognized complication of dislocations of the shoulder joint. *Radiology* 1940;35:690-700.
11. Bigliani LU, Newton PM, Steinmann SP, Connor PM, McIlveen SJ. Glenoid rim lesions associated with recurrent anterior dislocation of the shoulder. *Am J Sports Med* 1998;26:41-45.
12. Rowe CR, Patel D, Southmayd WW. The Bankart procedure: A long-term end-result study. *J Bone Joint Surg Am* 1978;60:1-16.
13. Ungersböck A, Michel M, Hertel R. Factors influencing the results of a modified Bankart procedure. *J Shoulder Elbow Surg* 1995;4:365-369.
14. Burkhart SS, De Beer JF. Traumatic glenohumeral bone defects and their relationship to failure of arthroscopic Bankart repairs: Significance of the inverted-pear glenoid and the humeral engaging Hill-Sachs lesion. *Arthroscopy* 2000;16:677-694.
15. Lo IK, Parten PM, Burkhart SS. The inverted pear glenoid: An indicator of significant glenoid bone loss. *Arthroscopy* 2004;20:169-174.
16. Sloth C, Just SL. The apical oblique radiograph in examination of acute shoulder trauma. *Eur J Radiol* 1989;9:147-151.
17. Itoi E, Lee SB, Amrami KK, Wenger DE, An KN. Quantitative assessment of classic antero-inferior bony Bankart lesions by radiography and computed tomography. *Am J Sports Med* 2003;31:112-118.
18. Sugaya H, Moriishi J, Dohi M, Kon Y, Tsuchiya A. Glenoid rim morphology in recurrent anterior glenohumeral instability. *J Bone Joint Surg Am* 2003;85:878-884.
19. Burkhart SS, Debeer JF, Tehrany AM, Parten PM. Quantifying glenoid bone loss arthroscopically in shoulder instability. *Arthroscopy* 2002;18:488-491.
20. Kralinger F, Aigner F, Longato S, Rieger M, Wambacher M. Is the bare spot a consistent landmark for shoulder arthroscopy? A study of 20 embalmed glenoids with 3-dimensional computed tomographic reconstruction. *Arthroscopy* 2006;22:428-432.
21. Huysmans PE, Haen PS, Kidd M, Dhert WJ, Willems JW. The shape of the inferior part of the glenoid: A cadaveric study. *J Shoulder Elbow Surg* 2006;15:759-763.
22. De Wilde LF, Berghs BM, Audenaert E, Sys G, Van Maele GO, Barbaix E. About the variability of the shape of the glenoid cavity. *Surg Radiol Anat* 2004;26:54-59.
23. Coxeter HSM. *Introduction to geometry*. Ed 2. New York: Wiley, 1969.

24. Jurgensen RC, Donnelly AJ, Dolciani MP. *Modern geometry: Structure and method*. Boston: Houghton-Mifflin, 1963.
25. Nobuhara K. *The shoulder: Its function and clinical aspects*. Ed 3. Tokyo: Igaku-shoin, 2001 (in Japanese).
26. Aigner F, Longato S, Fritsch H, Kralinger F. Anatomical considerations regarding the "bare spot" of the glenoid cavity. *Surg Radiol Anat* 2004;26:308-311.
27. Bankart ASB. Recurrent or habitual dislocation of the shoulder with significant fracture of the glenoid. *J Bone Joint Surg Am* 1973;55:1531-1533.
28. Henry JH, Genung JA. Natural history of glenohumeral dislocation—Revisited. *Am J Sports Med* 1982;10:135-137.
29. Hovelius L. Shoulder dislocation in Swedish ice hockey players. *Am J Sports Med* 1978;6:373-377.
30. Hovelius L, Eriksson K, Fredin H, et al. Recurrences after initial dislocation of the shoulder. Results of a prospective study of treatment. *J Bone Joint Surg Am* 1983;65:343-349.
31. Kralinger FS, Golser K, Wischatta R, Wambacher M, Sperner G. Predicting recurrence after primary anterior shoulder dislocation. *Am J Sports Med* 2002;30:116-120.
32. Norlin R. Use of Mitek anchoring for Bankart repair: A comparable, randomized, prospective study with traditional bone sutures. *J Shoulder Elbow Surg* 1994;3:381-385.
33. Townley CO. The capsular mechanism in recurrent dislocation of the shoulder. *J Bone Joint Surg Am* 1950;32:370-380.
34. Itoi E, Lee SB, Berglund LJ, Berge LL, An KN. The effect of a glenoid defect on anteroinferior stability of the shoulder after Bankart repair: A cadaveric study. *J Bone Joint Surg Am* 2000;82:35-46.
35. Mologne TS, Provencher MT, Menzel KA, Vachon TA, Dewing CB. Arthroscopic stabilization in patients with an inverted pear glenoid: Results in patients with bone loss of the anterior glenoid. *Am J Sports Med* 2007;35:1276-1283.