

Systematic Review With Video Illustrations

The Arthroscopic Management of Partial-Thickness Rotator Cuff Tears: A Systematic Review of the Literature

Eric J. Strauss, M.D., Michael J. Salata, M.D., James Kercher, M.D., Joseph U. Barker, M.D., Kevin McGill, B.A., M.P.H., Bernard R. Bach Jr., M.D., Anthony A. Romeo, M.D., and Nikhil N. Verma, M.D.

Purpose: There is currently limited information available in the orthopaedic surgery literature regarding the appropriate management of symptomatic partial-thickness rotator cuff tears. **Methods:** A systematic search was performed in PubMed, EMBASE, CINAHL (Cumulative Index to Nursing and Allied Health Literature), and the Cochrane Central Register of Controlled Trials of all published literature pertaining to the arthroscopic management of partial-thickness rotator cuff tears. Inclusion criteria were all studies that reported clinical outcomes after arthroscopic treatment of both articular-sided and bursal-sided lesions using a validated outcome scoring system and a minimum of 12 months of follow-up. Data abstracted from the selected studies included tear type and location (articular *v* bursal sided), treatment approach, postoperative rehabilitation protocol, outcome scores, patient satisfaction, and postoperative imaging results. **Results:** Sixteen studies met the inclusion criteria and were included for the final analysis. Seven of the studies treated partial-thickness rotator cuff tears with debridement with or without an associated subacromial decompression, 3 performed a takedown and repair, 5 used a transtendon repair technique, and 1 used a transosseous repair method. Among the 16 studies reviewed, excellent postoperative outcomes were reported in 28.7% to 93% of patients treated. In all 12 studies with available preoperative baseline data, treatment resulted in significant improvement in shoulder symptoms and function. For high-grade lesions, the data support arthroscopic takedown and repair, transtendon repairs, and transosseous repairs, with all 3 techniques providing a high percentage of excellent results. Debridement of partial-thickness tears of less than 50% of the tendon's thickness with or without a concomitant acromioplasty also results in good to excellent surgical outcomes; however, a 6.5% to 34.6% incidence of progression to full-thickness tears is present. **Conclusions:** This systematic review of 16 clinical studies showed that significant variation is present in the results obtained after the arthroscopic management of partial-thickness rotator cuff tears. What can be supported by the available data is that tears that involve less than 50% of the tendon can be treated with good results by debridement of the tendon with or without a formal acromioplasty, although subsequent tear progression may occur. When the tear is greater than 50%, surgical intervention focusing on repair has been successful. There is no evidence to suggest a differential in outcome for tear completion and repair versus transtendon repair of these lesions because both methods have been shown to result in favorable outcomes. **Level of Evidence:** Level IV, systematic review of Level IV studies.

From the Division of Sports Medicine, Rush University Medical Center, Chicago, Illinois, U.S.A.

The authors report no conflict of interest.

Received August 6, 2010; accepted September 27, 2010.

Address correspondence to Nikhil N. Verma, M.D., Midwest Orthopaedics, Rush University Medical Center, 1611 W Harrison St, Ste 300, Chicago, IL 60612, U.S.A. E-mail: nverma@rushortho.com

© 2011 by the Arthroscopy Association of North America

0749-8063/10467/\$36.00

doi:10.1016/j.arthro.2010.09.019

Note: To access the videos accompanying this report, visit the April issue of *Arthroscopy* at www.arthroscopyjournal.org.

Partial-thickness tears of the rotator cuff have the potential to cause significant pain and disability in affected patients.^{1,2} Partial-thickness tears can be on the articular side of the tendon, on the bursal side of the tendon, or intratendinous. In the older patient population, tears typically occur on the articular side of the supraspinatus tendon, near its insertion onto the greater tuberosity (Fig 1). This is in contrast to what is often seen in the younger, overhead throwing athlete, where tears tend to occur more posteriorly at the supraspinatus-infraspinatus interval. Ruotolo et al.³ evaluated the supraspinatus footprint in an anatomic study and found that the mean anterior-posterior dimension of the supraspinatus tendon was 25 mm (range, 19 to 27 mm). Among their 17 specimens with a mean age of 70 years, the authors reported a mean tendon thickness of 11.6 mm anteriorly, 12.1 mm at the midtendon region, and 12 mm posteriorly. Derived from the anatomy of the supraspinatus tendon, Ellman¹ developed a classification system for partial-thickness rotator cuff tears based on their location and depth as measured during shoulder arthroscopy (Table 1). In this system, articular-sided (A) or bursal-sided (B) tears are reported as grade 1 partial-thickness tears if less than 3 mm in depth, grade 2 tears if 3 to 6 mm in depth, and grade 3 lesions if greater than 6 mm in depth, representing greater than 50% of the tendon thickness.

Biomechanical studies have shown that in the presence of a partial-thickness tear, the strain patterns within the remaining intact rotator cuff are altered, potentially predisposing the tissue to tear propagation.⁴⁻⁷ Limited potential for spontaneous healing after the development of a partial-thickness tear is supported by histologic studies that observed no active repair at the site of the injury, with the proximal stumps of the rotator cuff appearing rounded, retracted, and avascular.⁸ Clinical evidence of tear progression was shown by Yamanaka and Matsumoto⁹ in their evaluation of 40 patients with documented partial-thickness articular-sided lesions of the supraspinatus. Reimaging of the study patients with arthrography at a mean of 412 days after the initial diagnosis showed tear enlargement in 53% and progression to a full-thickness tear in 28%.

After failed conservative management, operative intervention is typically indicated for patients with persistent symptoms of pain and disability. A variety of approaches to the arthroscopic management of partial-thickness rotator cuff tears have been reported, including acromioplasty alone, debridement of the partial-thickness tear with or without acromioplasty, transtendinous repair, or conversion

of the lesion to a full-thickness tear followed by repair (Table 2). Results of these surgical approaches vary considerably in the orthopaedic surgery literature, making it difficult to draw conclusions on the appropriate arthroscopic management of symptomatic partial-thickness rotator cuff tears.

On the basis of the continued controversy present within the literature regarding the management of

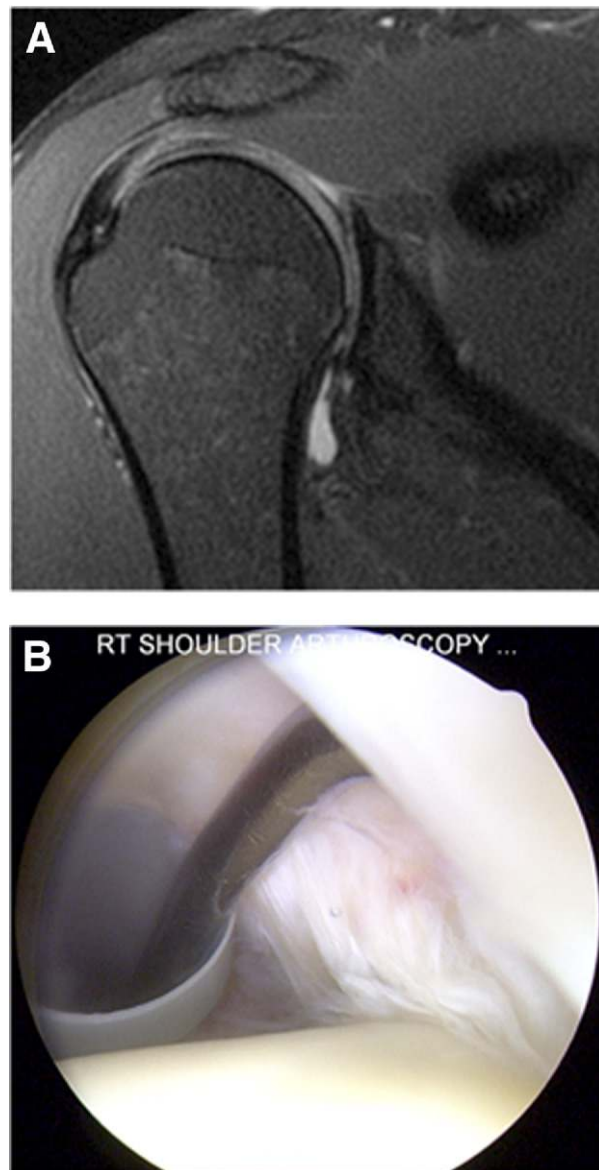


FIGURE 1. (A) Coronal magnetic resonance image and (B) intra-articular appearance with patient in beach-chair position of articular-sided partial-thickness tear of supraspinatus in 50-year-old right hand-dominant man with 7 months of activity-related right shoulder pain.

TABLE 1. *Ellman Classification of Partial-Thickness Rotator Cuff Tears Based on Location of Lesion and Depth Assessed at Time of Arthroscopy**

Location	Grade
A: Articular surface	I: <3 mm deep
B: Bursal surface	II: 3-6 mm deep
C: Interstitial	III: >6 mm deep

*Based on data from reference 1.

partial-thickness tears of the rotator cuff, we designed a qualitative systematic review to compare the results of the recommended arthroscopic treatments and evaluate which potential variables are associated with successful outcomes for this complex patient population.

METHODS

Literature Search

From January 1996 to December 2009, we searched PubMed, EMBASE, CINAHL (Cumulative Index to Nursing and Allied Health Literature), and the Cochrane Central Register of Controlled Trials for all published literature using the following key words: shoulder, rotator cuff, rotator cuff tear, partial-thickness rotator cuff tear, partial rotator cuff tear, articular-sided rotator cuff tear, bursal-sided rotator cuff tear, incomplete rotator cuff tear, and rotator cuff repair. General search terms were used to prevent the possibility of missing relevant studies. Studies that were only presented as abstracts were not included in the final analysis of the available data. To ensure that all possible studies were considered for evaluation, the references of all applicable studies and review articles were manually cross-referenced.

Inclusion criteria were all studies that reported clinical outcomes after the arthroscopic treatment of partial-thickness rotator cuff tears, including both articular-sided and bursal-sided lesions, using validated outcome scoring systems and with a minimum of 12 months of follow-up. Exclusion criteria were studies that failed to appropriately classify tears as articular sided or bursal sided, those that did not use an outcome scoring system, those with data on fewer than 10 patients, and those with less than 12 months of follow-up. Patient demographic information, partial-thickness rotator cuff tear characteristics, operative technical details, objective and subjective outcome measurements, follow-up imaging studies if included, and

TABLE 2. *Available Arthroscopic Treatment Options for Partial-Thickness Rotator Cuff Tears*

Isolated acromioplasty
Debridement with or without acromioplasty
Transtendinous repair
Conversion of lesion to full-thickness tear followed by repair

complications were abstracted from each included study.

Data Abstraction

The data from each study that met the inclusion criteria were abstracted by 2 independent reviewers. Study data collected included the type of study, year, level of evidence, number of patients enrolled, number of patients available for final follow-up, age, gender, and length of follow-up. The Ellman classification of partial-thickness rotator cuff tears was used to characterize the location and grade of the tear.¹ Location of the partial-thickness tear is divided into articular surface (A), bursal surface (B), and interstitial (C). Tears are graded according to depth and categorized as less than 3 mm deep (I), 3 to 6 mm deep (II), and greater than 6 mm deep (corresponding to >50% of supraspinatus width) (III). The primary treatment method for the partial-thickness tear was recorded, in addition to any concomitant procedures performed for associated shoulder pathology. Preoperative and postoperative data including range of motion, strength, and clinical and subjective outcome scores—University of California, Los Angeles (UCLA) outcome score,¹⁰ Constant-Murley outcome score,¹¹ American Shoulder and Elbow Surgeons outcome score,¹² Pennsylvania Shoulder Scale,¹³ Simple Shoulder Test,¹⁴ Japanese Orthopaedic Association outcome score,^{15,16} L'Insalata scoring system,¹⁷ Neer criteria,¹⁸ and visual analog scale (VAS) for pain—were extracted. If noted in the study, the percentage of patients satisfied with their outcome was documented. When available, the method of postoperative imaging modality used and the duration after surgery were also recorded. No statistical comparisons were performed as part of the systematic review.

RESULTS

Literature Search

Limiting the results to studies published in the English language, there were 48,486 articles found with

TABLE 3. Study Demographics of Articles Included in Current Systematic Review of Arthroscopic Management of Partial-Thickness Rotator Cuff Tears

Author	Year	No. of Shoulders	Mean Age (yrs)	Tear Type	Treatment	Mean Follow-Up (mo)	% Follow-Up
Spencer ³²	2010	20	41	Articular sided	TT repair	29	100%
Castricini et al. ²¹	2009	33	53.3	Articular sided	TT repair	33	94%
Castagna et al. ²⁰	2009	70	56.7	Articular sided	TT repair	32.4	77%
Kamath et al. ²⁵	2009	47	53	A3 tears	TD and repair	39	89.4%
Porat et al. ²⁹	2008	51	59.7	Articular sided	TD and repair	42.4	70.6%
Liem et al. ²⁷	2008	46	59.2	A1 and A2 tears	Debridement with SAD	50.3	100%
Tauber et al. ³³	2008	16	NR	A2 and A3 tears	TO repair	18	100%
Reynolds et al. ³⁰	2008	82	25.6	Articular sided	Debridement without SAD	39.2	41.5%
Deutsch ²³	2007	46	49	A3 tears (33) and bursal sided (8)	TD and repair	38	89.1%
Kartus et al. ²⁶	2006	33	51.5	A2 tears (13), bursal sided (10), both (3)	Debridement with SAD	101	79%
Waibl and Buess ³⁴	2005	22	45	Articular sided	TT repair	16	100%
Ide et al. ²⁴	2005	17	42	A3 tears	TT repair	39	100%
Budoff et al. ¹⁹	2005	98	45	Articular sided (51), bursal sided (1), both (27)	Debridement with and without SAD	114	80.6%
Park et al. ²⁸	2003	49	52	Articular sided (24), bursal sided (13)	Debridement with SAD	42	75.5%
Cordasco et al. ²²	2002	107	55	Articular sided (63), bursal sided (14)	Debridement with SAD	52.7	72%
Snyder et al. ³¹	1991	38	42	Articular sided (27), bursal sided (7)	Debridement with and without SAD	23	81.6%

Abbreviations: TT, transtendon; TD, takedown; NR, not reported; SAD, subacromial decompression; TO, transosseous.

all of the general search terms. Each of the search terms was then combined with 1 other term using PubMed's advanced-search feature to locate those studies pertinent to this systematic review. The abstracts of these combined searches were then reviewed to determine appropriateness for inclusion in the study. There were 29 articles whose abstracts indicated potential for inclusion. Of the 29 articles, 13 were excluded from the analysis after a full-text review, leaving 16 studies for final evaluation.¹⁹⁻³⁴ Six studies were excluded based on their use of open surgical techniques for the management of their patients' partial-thickness rotator cuff tears.³⁵⁻⁴⁰ Two studies were excluded because they had fewer than 10 patients and less than 12 months of follow-up in their analysis.^{41,42} Two studies were excluded based on their lack of a validated outcome scoring system for their postoperative evaluation.^{43,44} An additional 2 studies were excluded because of a lack of reported patient demographic information and description of tear type,^{45,46} and 1 study was excluded because of the same patient cohort being reported on in a subsequent article with longer follow-up.⁴⁷

Study Demographics

The study design, level of evidence, total number of patients studied, number of shoulders treated, tear type, arthroscopic treatment technique, and percent of follow-up were included in the analysis (Table 3). All of the studies included in this systematic review were Level IV Evidence comprising case series. Included studies had a range of patient follow-up from 41.5% to 100%, with an overall mean of 84% and 44.3 months (range, 16 to 114 months). There were a total of 775 shoulders with symptomatic partial-thickness rotator cuff tears undergoing treatment in patients with an overall mean age of 48.7 years. Follow-up data were available for 657 shoulders among the 16 clinical studies reviewed. Ten of the studies included patients with only articular-sided partial-thickness rotator cuff tears, with the remaining six studies evaluating patients with either articular-sided tears, bursal-sided tears, or tears affecting both the articular and bursal sides of the supraspinatus. Overall, 14 of the 16 studies classified the partial-thickness rotator cuff tears treated. There were 587 articular-sided tears,

43 bursal-sided tears, and 27 tears affecting both the articular and bursal surfaces. Partial articular surface tears were graded as Ellman IA in 106 cases, IIA in 135, and IIIA in 193. Two studies used the Snyder classification, describing 10 A1 tears, 20 A2 tears, 29 A3 tears, and 19 A4 tears.^{20,31} Seventy-five shoulders with partial articular-sided tears did not have a description of their tear type. Among the bursal-sided tears, there were 6 Ellman IB tears, 21 IIB tears, and 0 IIIB tears. On the basis of the Snyder classification, 2 shoulders had B1 partial-thickness tears, 3 had B2 tears, and 10 had B3 tears. One shoulder with an isolated bursal-sided tear did not have a description of the tear type. The 27 shoulders with tears present on both the articular and bursal sides of the rotator cuff did not have a description of the tear depth but were considered high grade for our analysis because each was taken down and repaired.

Arthroscopic treatment methods used in the reviewed studies included debridement of the partial-thickness rotator cuff tear with subacromial decompression in 4 studies, debridement without decompression in 1 study, debridement with or without subacromial decompression in 2 studies, takedown and repair in 3 studies, transtendon repairs of the supraspinatus in 5 studies, and arthroscopic transosseous repair in 1 study. Outcome measures reported in these studies included an assessment of postoperative range of motion, strength, patient satisfaction, follow-up American Shoulder and Elbow Surgeons (ASES) scores, Constant-Murley scores, UCLA scores, Simple Shoulder Test scores, Japanese Orthopaedic Association scores, L'Insalata scores, Athletic Shoulder Outcome Rating scores, Short Form 12 scores, VAS scores, and Neer criteria. Two studies included postoperative ultrasound evaluations, one study reported results on postoperative magnetic resonance imaging (MRI), and two studies reported percentage return to athletic activity.

Surgical Techniques

Studies that reported outcomes after debridement of partial-thickness rotator cuff tear with or without an associated subacromial decompression all describe a similar operative technique (Video 1, available at www.arthroscopyjournal.org). Each author described assessing the supraspinatus footprint using an arthroscopic probe to determine the depth of the partial-thickness tear (Table 4). Snyder et al.³¹ describe inserting the probe through a lateral subacromial portal to palpate the tear from the bursal side, confirming its partial-thickness nature while viewing intra-articu-

TABLE 4. Pearls for Arthroscopic Evaluation of Partial-Thickness Rotator Cuff Tears

When a partial thickness tear is identified, debridement with the shaver will help delineate the extent of the tear once the frayed edges and synovial lining are removed—debride until normal tendon fibers are identified inserting onto the greater tuberosity
The size of the tear can be estimated based on the extent of exposed bone of the greater tuberosity—Nottage's guidelines state that every millimeter of exposed bone present represents a 10% tear of the tendinous insertion ^{29,48}
Percutaneously insert the spinal needle into the site of the partial-thickness tear, typically inserting the needle at the anterolateral edge of the acromion
Pass a monofilament suture through the spinal needle to help with localization on the bursal side of the rotator cuff in the subacromial space
Bursal side evaluation of the rotator cuff at the site of the marking suture allows for further surgical decision making

larly. After intra-articular debridement, the bursal surface of the rotator cuff was assessed in the subacromial space.

Formal subacromial decompression was performed in all treated patients in 4 studies, all with a similarly described operative technique.^{22,26-28} Snyder et al.³¹ performed subacromial decompression combined with debridement in 18 of 31 cases (58%), and Reynolds et al.³⁰ included anterior acromioplasty in 25 of 82 professional baseball pitchers (30.5%) with partial-thickness rotator cuff tears. In their series of 62 shoulders with symptomatic partial-thickness rotator cuff tears, Budoff et al.¹⁹ evaluated the results of debridement without formal subacromial decompression. However, during the operative procedure, subacromial osteophytes were removed in 27 patients (43.5%).

Three studies described takedown and repair of high-grade partial-thickness tears found to be greater than 50% of the tendon thickness during diagnostic arthroscopy.^{23,25,29} In these studies, the high-grade tears were completed with a shaver and/or a scalpel and then repaired by use of a single-row technique in the study by Deutsch,²³ and a double-row repair construct in the study by Porat et al.²⁹ (Video 2, available at www.arthroscopyjournal.org). In the study published by Kamath et al.,²⁵ a horizontal mattress repair using a single suture anchor was used in 37 shoulders, with the remaining 5 patients having their tear repaired with a double-row construct.

Tauber et al.³³ reported using an arthroscopic transosseous repair in 16 patients with partial-thickness supraspinatus tears, 7 of which were graded as Ellman

TABLE 5. Pearls for Arthroscopic Transtendon Repairs of Partial-Thickness Rotator Cuff Tears

Technique indicated for partial articular surface tears of the supraspinatus
Precise portal placement is vital for success—typically two 8.25-mm cannulas are inserted: one in the anterosuperior position within the rotator interval and one in the lateral position within the subacromial space
Greater tuberosity preparation is performed with a shaver or an arthroscopic bur
Try to pass sutures such that a triangular configuration is created—allowing for re-creation of the normal insertional footprint
After the arthroscopic knots are tied in the subacromial space, the arthroscope can be reintroduced into the intra-articular space to evaluate the repair

IIA and 9 as Ellman IIIA. A specialized device was used to pass sutures through the supraspinatus tendon at the site of the partial-thickness tear, directly at the border between the intact and debrided tendon tissue. These sutures were then passed out of the lateral cortex 1.5 cm distal to the top of the greater tuberosity and tied in this position.

The remaining 5 studies reported results after arthroscopic transtendon repairs for articular-sided partial-thickness supraspinatus tears^{20,21,24,32,34} (Table 5). Each study used percutaneous placement of suture anchors through the intact bursal portion of the rotator cuff into the medial portion of the greater tuberosity (Video 3, available at www.arthroscopyjournal.org). In 4 of the 5 studies, a single double-loaded suture anchor was used for the transtendon repair. Ide et al.²⁴ used a single anchor for tears involving less than 1.5 cm of the footprint in the anterior-posterior direction and 2 anchors for tears involving greater than 1.5 cm. Sutures are shuttled through the edges of the partial-thickness tear and then tied in the subacromial space.

Postoperative Rehabilitation

Among the 7 studies using operative debridement with or without concomitant subacromial decompression, 6 describe encouraging patients to perform active and passive shoulder motion as tolerated in the immediate postoperative period.^{19,22,26-28,31} Sling immobilization was specified in 1 study until postoperative pain had subsided,²⁶ whereas 1 study did not use a postoperative sling for their treated patients.²⁷ After takedown and repair, patients were typically placed on a rotator cuff repair rehabilitation protocol. Castricini et al.²¹ used a slightly accelerated therapy program after transtendon repair, taking their patients out of the

abduction shoulder immobilizer for active range of motion at 3 weeks, with strengthening started at 10 weeks postoperatively. Continuous passive motion machines were used in the rehabilitation protocol of Ide et al.²⁴ after transtendon repair.

Surgical Outcomes

Results after the arthroscopic treatment of partial-thickness rotator cuff tears varied widely in the studies included for review. The rate of excellent postoperative outcomes ranged from 28.7% to 93%, with significant improvements compared with baseline reported in all 12 studies with available preoperative data. Treatment for partial-thickness rotator cuff tears can be separated into 2 main categories: debridement and repair.

Debridement: Debridement of the partial-thickness tear was used in 7 studies. Of the 7 studies, 4 used formal subacromial decompression in all treated patients. Tears that comprised less than 50% of the tendon's thickness and were Ellman grade II or less were routinely treated with debridement in these studies. Overall good to excellent results as measured by validated shoulder-scoring systems were obtained with this treatment modality (Table 6).^{22,26-28} Kartus et al.²⁶ reported that the results obtained with this treatment modality may not remain in optimal range over the long term, noting that the Constant score fell nearly 20 points below that of the contralateral "normal" shoulder at longer follow-up. Formal subacromial decompression with acromioplasty did not significantly affect the overall outcome of patients treated with debridement because good results were reported in studies that did not use this adjunct as part of their treatment protocol (Table 6).^{19,30,31} Return to high-level athletic activity was variable when debridement was used as the surgical intervention, with Reynolds et al.³⁰ reporting only a 45% rate of return to play at the same or higher level before the rotator cuff pathology. Budoff et al.¹⁹ reported similar findings regarding return to play, with 57% of patients being able to return to preoperative levels of recreational activity, 20% reporting pain with these activities, and 22% being unable to participate because of persistent shoulder discomfort. On the basis of the available data, partial-thickness tears of less than 50% or Ellman grade II or less can be successfully treated with debridement alone. It does not appear, based on the current evidence, that formal subacromial decompression leads to superior outcomes when compared with debridement alone. The ability to return patients to high-level recreational or sporting activities is less

TABLE 6. *Clinical Outcomes After Debridement With and Without SAD for Partial-Thickness RTC Tears*

Author	Treatment	Findings	Conclusions
Liem et al. ²⁷	Debridement with SAD	Mean ASES score, 37.4 → 86.6 Mean VAS, 7.4 → 2.1 Mean postoperative Constant score, 87.6 Overall outcome graded as good/excellent in 87% of cases	Good and excellent results can be achieved midterm to long term by subacromial decompression and debridement for partial-thickness tears <50% in size
Reynolds et al. ³⁰	Debridement without SAD	18 pitchers with excellent outcomes, 8 with good outcomes, 4 with fair outcomes, and 4 with poor outcomes 76% of patients returned to professional pitching, with 55% returning to play at same or higher level	Debridement of partial-thickness RTC tears allowed a majority of elite overhead throwing athletes to return to competitive pitching; however, returning to their previous level of competition remains a challenge
Kartus et al. ²⁶	Debridement with SAD	At long-term follow-up, the mean Constant score was 65 compared with mean of 84 for contralateral shoulder Postoperative ultrasound identified progression to full-thickness tear in 34.6% of patients Patients whose tear progressed had worse outcomes than those whose tear remained stable	Acromioplasty and debridement of partial-thickness tears does not protect the RTC from undergoing further degeneration
Park et al. ²⁸	Debridement with SAD	Increase in mean ASES score from 38 at baseline to 83 at 6 mo, 88 at 1 yr, and 89 at 2 yr of follow-up VAS decreased from 6.5 preoperatively to 1 at 2 yr of follow-up	Pain relief and functional recovery were excellent after debridement and subacromial decompression
Cordasco et al. ²²	Debridement with SAD	Mean L'Insalata score, 90 At time of final follow-up, patients regained 95% of their contralateral shoulder's strength	At long-term follow-up, there was no evidence that clinically relevant or symptomatic intrinsic RTC pathology progresses in patients with partial-thickness tears treated with debridement and subacromial decompression
Budoff et al. ¹⁹	Debridement with and without SAD	Satisfactory outcome in 87% of cases Good/excellent postoperative UCLA scores in 86% of cases 57% returned to athletics without symptoms When Workers' Compensation cases excluded, 90% satisfactory outcomes	Debridement of RTC with and without subacromial decompression is an effective long-term treatment for partial-thickness tears
Snyder et al. ³¹	Debridement with and without SAD	Mean UCLA score, 32 26 of 31 patients classified as having satisfactory outcome	Good results achieved after debridement with and without subacromial decompression No difference in outcomes between patients treated with formal subacromial decompression and those treated with debridement alone

Abbreviations: SAD, subacromial decompression; RTC, rotator cuff.

predictable with this method of treatment, and although further study is necessary, the long-term prognosis is suggested to be guarded.

Repair: Similar to debridement, repair of partial-thickness rotator cuff tears has been shown to be a reliable method for treatment of this pathology. Positive outcomes as measured by validated scores and patient subjective satisfaction surveys are reported for transtendon, transosseous, and tear-completion meth-

ods for repair, with no significant difference noted between these surgical techniques (Table 7).^{23,25,29,33} Four of the five studies on transtendon repair reported results comparable to the takedown groups; however, although still showing improvement from preoperative levels, Castagna et al.²⁰ did report a 41% incidence of persistent shoulder pain after transtendon repair. There are currently no randomized studies comparing takedown with transtendon repair.

TABLE 7. Clinical Outcomes After Arthroscopic Repair of Partial-Thickness RTC Tears

Author	Treatment	Findings	Conclusions
Spencer ³²	Transtendon repair	Mean Penn Shoulder Score improved from 74 to 92; 19 of 20 patients returned to athletics at same level or higher	An all-inside transtendon repair results in good clinical outcomes with no cases of postoperative stiffness
Castricini et al. ²¹	Transtendon repair	Mean Constant score, 44.4 → 91.6 Excellent outcomes in 93% of cases; 100% of patients returned to work without difficulty	For high-grade partial-thickness RTC tears, arthroscopic transtendon repair reconstitutes the footprint without damaging the remaining intact fibers, potentially allowing for a better recovery
Castagna et al. ²⁰	Transtendon repair	Mean UCLA score, 14.1 → 32.9 Mean Constant score, 45.3 → 90.6 Mean Simple Shoulder Test score, 9.8 → 0.8 Mean VAS, 5.7 → 1.3; 41% of patients continued to report shoulder discomfort with activity	Arthroscopic transtendon repair is a reliable procedure resulting in good outcomes with respect to pain relief and improved shoulder function
Waibl and Buess ³⁴	Transtendon repair	Mean UCLA score, 17.1 → 31.2 Mean VAS, 8.4 → 2.0 Good/excellent results in 86% of patients 91% of patients satisfied with their outcome	Transtendon repair has shown promising results with the benefit of preserving the remaining intact tendon fibers
Ide et al. ²⁴	Transtendon repair	Good/excellent results in 94% Mean UCLA score, 17.3 → 32.9 Mean Japanese Orthopaedic Association score, 68.4 → 94.8	Arthroscopic transtendon repair is a safe and reliable procedure for patients with high-grade partial-thickness RTC tears
Kamath et al. ²⁵	Takedown and repair	Mean ASES score, 46.1 → 82.1; 93% of patients reported satisfaction with their clinical outcome and 93% returned to their previous occupation	Arthroscopic repair of high-grade partial-thickness RTC tears results in a high rate of tendon healing
Porat et al. ²⁹	Takedown and repair	Mean UCLA score, 17.25 → 31.45 Good/excellent results in 83.3% of patients	Completion of high-grade partial-thickness RTC tears followed by repair results in clinical improvement
Deutsch ²³	Takedown and repair	Mean ASES score, 42 → 93 (73.2% of patients with ASES score >90) Mean VAS, 6.5 → 0.8; 100% of patients reported improvements in ADLs Patient satisfaction, 3 → 9.2	Clinical results support the takedown and repair of partial-thickness RTC tears >50% of the tendon thickness
Tauber et al. ³³	Transosseous repair	Mean UCLA score, 15.8 → 32.8 Mean VAS, 7.9 → 1.2; 15 of 16 patients satisfied with their clinical outcome	Preliminary results of the transosseous technique are convincing, with significant pain relief and functional improvement

Abbreviations: RTC, rotator cuff; ADLs, activities of daily living.

Of the 9 studies in which repair was performed, 6 reserved this treatment for high-grade tears.^{23-25,29,32,34} Although the available numbers are small, in the studies where repair was also performed for patients with Ellman grade II or Snyder A1 and A2 lesions, no significant difference was noted with respect to postoperative outcome compared with that seen after treatment for high-grade tears.^{20,21,33}

On the basis of the available data, for higher-grade partial-thickness tears (>50% of tendon's thickness) repair through a transtendon, transosseous, or tear-completion technique can be successful with high patient satisfaction and good outcomes reported based

on validated scoring systems. In addition, on the basis of the current available data, no recommendation can be made regarding preferred surgical technique for repair of partial-thickness tears of the rotator cuff.

Postoperative Range of Motion

Of the 16 studies reviewed, 6 reported postoperative glenohumeral range of motion as an outcome variable after the treatment of partial-thickness rotator cuff tear.^{20,22,23,26,29,32} In their review of results after debridement with acromioplasty, Cordasco et al.²² report no significant loss of motion in scapular-

plane elevation, external rotation, or internal rotation, although no specific preoperative or postoperative data are presented. Of the remaining 5 studies, 3 reported improvements in glenohumeral range of motion after treatment,^{20,23,29} with all 5 reporting no significant difference in postoperative range of motion compared with the contralateral side at the time of final follow-up.^{20,23,26,29,32}

Postoperative Imaging

Four studies used postoperative imaging to evaluate the status of the rotator cuff after treatment.^{21,25-27} Of the 4 studies, 3 used ultrasound, whereas that of Castricini et al.²¹ used MRI. Kartus et al.²⁶ reported that after arthroscopic debridement and acromioplasty, 9 of 26 patients had ultrasound evidence of progression of their partial-thickness tear to a full-thickness tear, for a tear-completion rate of 34.6%. The mean Constant score for those patients whose tear progressed was lower than that seen in patients whose tear remained stable (48 v 65); however, this difference was not found to be statistically significant. In the study of takedown and repair of Kamath et al.,²⁵ 5 of 42 shoulders (11.9%) had ultrasound evidence of re-tear at a mean of 6 months after the procedure. Patients with recurrent tears in this study tended to be older than those whose tears had healed postoperatively (62.8 years v 51.8 years) and had lower postoperative ASES scores and higher VAS pain scores, although these differences were not found to be significant. Liem et al.²⁷ reported better outcomes, with only 3 of their 46 patients (6.5%) having progression of their tear present on ultrasound evaluation after debridement and subacromial decompression. In the review of Castricini et al., follow-up MRI of the results after arthroscopic transtendon repair showed no evidence of re-tear in any of their 33 patients.

Effect of Partial-Thickness Rotator Cuff Tear Size on Surgical Outcome

In 8 of the 16 studies, patients with partial-thickness rotator cuff tears of varying depth were treated and included for analysis.^{19-22,27,30,31,33} Of the 8 studies, 5 compared surgical outcomes between tears of different grades, with 4 of the 5 reporting no significant difference in results.^{19,22,27,31,33} Budoff et al.⁴⁷ found that after debridement without formal acromioplasty, patients with grade II partial-thickness tears had significantly better outcomes than those treated for grade III tears. Good to excellent results were reported in 86% of cases with tears less than 50% in size com-

pared with 54% in those found to be greater than 50%. Patients with Ellman grade I and II tears were treated in the reviews of debridement and subacromial decompression of partial-thickness lesions of Cordasco et al.²² and Liem et al.,²⁷ with no difference noted in postoperative VAS pain scores, ASES scores, or L'Insalata scores. Postoperative UCLA scores for patients with Snyder A1 tears, A2 tears, and A3 tears treated with debridement with or without subacromial decompression were not significantly different in the study of 31 patients of Snyder et al.³¹ (means of 30, 33 and 32, respectively). Similarly, no difference in postoperative clinical outcome was reported between patients with grade II and grade III tears treated with transosseous arthroscopic repair in the review of 16 patients by Tauber et al.³³ Castagna et al.²⁰ reported that among their 22 patients with residual pain after transtendon repair of Snyder A2, A3 and A4 tears, the best predictor of postoperative symptoms was the amount of tendon retraction present before treatment. Among the patients with activity-related pain, a mean 12.7 mm of retraction was present compared with 5.7 mm of retraction in those without symptoms after repair.

Articular-Sided Versus Bursal-Sided Lesions

Of the 16 studies reviewed, 6 included patients with partial-thickness tears affecting either the articular or bursal surface of the rotator cuff, or both.^{19,22,25,26,28,31} Four studies compared the postoperative outcomes between articular- and bursal-sided lesions: two found no significant difference, one reported better outcomes for bursal-sided lesions, and one found a significantly higher failure rate among bursal-sided lesions. In the review of Kartus et al.,²⁶ the mean postoperative Constant score for patients with bursal-sided tears was 61.5 after debridement and acromioplasty; although lower than the mean of 72 for those with articular-sided lesions, this was not statistically significant. Park et al.²⁸ reported that after debridement and subacromial decompression, a significantly greater reduction in pain was noted at the 6-month time point among patients with bursal-sided tears compared with those with articular-sided tears; however, this difference was not present at 1 or 2 years of follow-up. Similarly, a significantly larger increase in ASES score was seen at 6 months in patients whose bursal-sided tears were treated compared with patients with articular-sided lesions, but this difference was not present at later follow-up time points. At final follow-up, 83% of patients with articular-sided tears reported

satisfactory outcomes compared with 92% of patients with bursal-sided tears. Poorer outcomes with a significantly greater failure rate among patients with bursal-sided partial-thickness tears treated with debridement and acromioplasty was reported by Cordasco et al.²² Treatment failure, defined as a L'Insalata score of less than 70, was seen in 29% of patients with bursal-sided tears (4 of 14 shoulders) compared with 3% of patients with articular-sided lesions (2 of 63 shoulders). Among the 42 shoulders treated with takedown and repair in the study of Kamath et al.,²⁵ 33 had articular-sided tears and 9 had bursal-sided tears. Although no significant difference was noted in mean postoperative ASES score and VAS pain score (81.3 v 85.2 and 2.8 v 2.5, respectively), treatment failure in the form of retear was noted in 22.2% of bursal-sided lesions compared with 9.1% of articular-sided tears.

Although the available data regarding the location of partial-thickness rotator cuff tears are variable, it appears that bursal-sided lesions fare worse than those on the articular side. Although further study is warranted, current evidence suggests that patients with bursal-sided partial-thickness tears have a guarded prognosis and should be counseled by the treating surgeon accordingly.

Postoperative Complications

Complications after the arthroscopic treatment of partial-thickness rotator cuff tears were rare. Excluding tear progression as a complication, 12 of the 16 studies reviewed reported no intraoperative or postoperative complications. The remaining 4 studies reported an incidence of postoperative complications ranging from 2.5% to 11.9%.^{19,25,29,31} Of the 9 complications described, postoperative stiffness accounted for 6 cases; 2 required manipulation under anesthesia, 3 were treated with arthroscopic lysis of adhesions/capsular release, and 1 improved after corticosteroid injection. The remaining complications were persistent symptoms due to acromioclavicular joint pathology in 1 case, subcoracoid impingement in 1 case, and symptomatic scapulothoracic bursitis in 1 case, all of which required reoperation.

Workers' Compensation Cases

Workers' Compensation patients were included in the patient populations of 3 studies, with only 1 specifically reporting surgical outcomes for this patient subset.^{19,23,29} Budoff et al.¹⁹ reported that the presence of Workers' Compensation claims had a statistically significant correlation with inferior results for postop-

erative UCLA scores after debridement without formal subacromial decompression. Among the 5 patients with outstanding claims, 3 required reoperation for persistent symptoms, for a 60% failure rate.

Potential Study Biases

Although this review included all clinical studies reporting on outcomes after the arthroscopic treatment of partial-thickness rotator cuff tears, the techniques used varied, creating the potential for performance bias. In addition, concomitant surgical procedures separate from those aimed at the partial-thickness lesions were performed in patients in 6 of the 16 studies reviewed.^{19,20,23,25,30,31} In these 6 studies, concomitant procedures including superior labral debridement or repair, distal clavicle excision, capsular release, and/or capsulorrhaphy were performed in 6.5% to 96% of study patients. The potential for impact of these additional procedures on the outcome after partial-thickness rotator cuff treatment needs to be acknowledged.

With a range of patient follow-up from 41.5% to 100%, the potential for selection bias is present in this systematic review. However, we believe that 14 of the 16 studies having greater than 75% patient follow-up, 7 having greater than 90% follow-up, and an overall mean of 86% follow-up limit this possibility to as great an extent as possible.

DISCUSSION

Clinically, partial-thickness tears of the rotator cuff present with pain and decreased shoulder function, with most patients reporting symptoms during overhead activities and pain at night. They are potentially more painful than full-thickness tears, possibly because of the nonphysiologic tension created within the remaining intact rotator cuff fibers. Biomechanical studies have shown that once a partial-thickness lesion of the rotator cuff occurs, strain patterns in the surrounding cuff are altered, predisposing the tear to propagation and/or completion. Natural history studies have supported these biomechanical theories, indicating that because of altered tension distribution and a limited potential for spontaneous healing, partial-thickness rotator cuff tears will progress over time. When initial conservative treatment comprising rest, activity modification, nonsteroidal anti-inflammatory medications, and corticosteroid injections fails to improve symptoms, operative intervention is indicated. A number of different surgical approaches to partial-thickness rota-

tor cuff tears have been reported on in the orthopaedic literature, with considerable variation in outcomes. Although the current theory is to debride partial-thickness tears comprising less than 50% of the tendon thickness and to repair high-grade tears greater than 50%, the data to support any particular management approach are variable and limited.

In this qualitative systematic review, we identified 16 clinical studies investigating the arthroscopic treatment of partial-thickness rotator cuff tears with 4 main surgical techniques: debridement with or without sub-acromial decompression, arthroscopic transosseous repair, takedown and repair, and transtendon repair. Studies selected for review included those that treated partial-thickness rotator cuff tears affecting either the articular or bursal surface using validated outcome scoring systems and reported on at least 10 patients with a minimum of 12 months of follow-up. Overall,

there were data available on 657 patients with 587 articular-sided tears, 43 bursal-sided tears, and 27 tears affecting both the articular and bursal surfaces.

Results after the arthroscopic treatment of partial-thickness rotator cuff tears varied widely among the 16 studies reviewed. Excellent postoperative outcomes were reported in 28.7% to 93% of patients treated. In all 12 studies with available preoperative baseline data, treatment resulted in significant improvement in shoulder symptoms and function. Although the use of different outcome scoring systems makes direct comparison of the various treatment approaches difficult, the data support the operative repair of high-grade partial-thickness tears. Arthroscopic transtendon repairs, takedown and repair, and transosseous repairs all appear to be effective operative techniques, with the rate of good to excellent results ranging from 86% to 94.1%. As shown in the use of postoperative

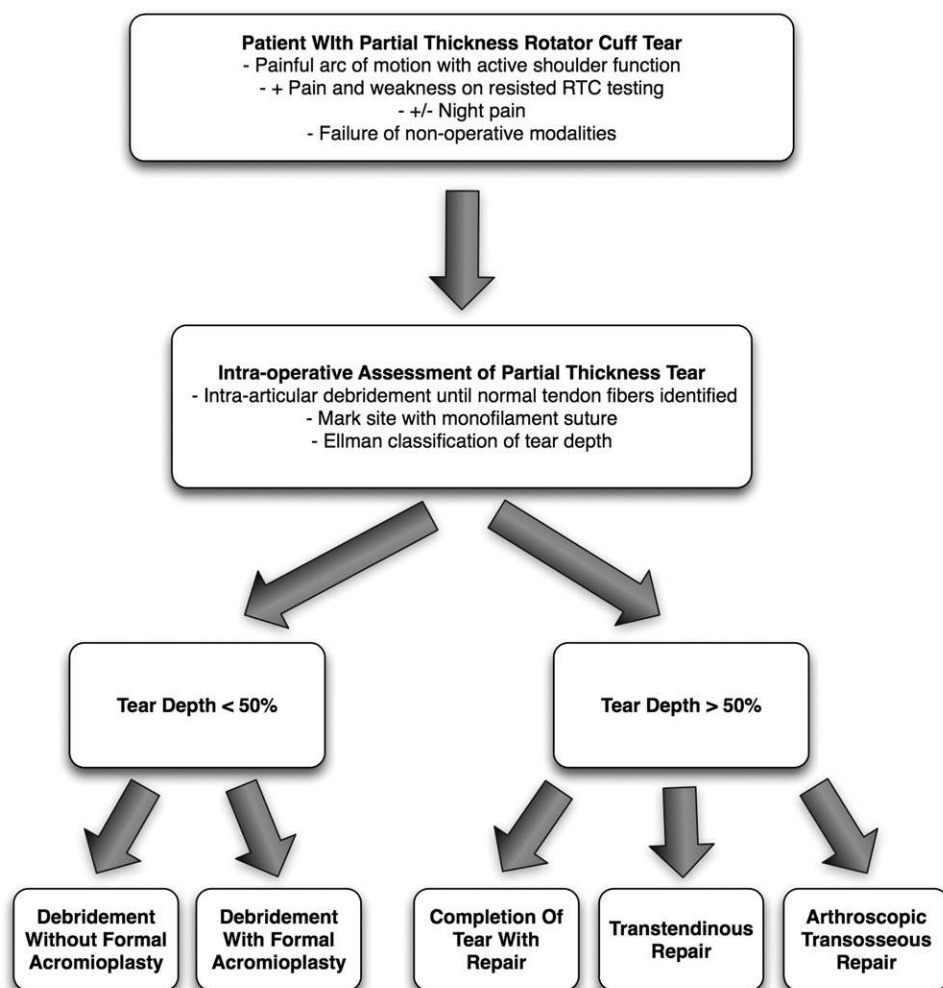


FIGURE 2. Treatment algorithm based on current evidence in orthopaedic surgery literature. What can be supported by the data available is that, in general, tears that involved less than 50% of the tendon can be treated with good results by debridement of the tendon with or without a formal acromioplasty. When the tear is greater than 50%, surgical intervention focusing on repair has been successful. There is no evidence to suggest that tear completion and repair is superior or inferior to transtendon repair of these lesions because both methods have been shown to result in favorable outcomes. (RTC, rotator cuff.)

MRI by Castricini et al.,²¹ tear progression was prevented after arthroscopic transtendon repair at 33 months of follow-up.

For tears of less than 50% of the tendon's thickness, successful results after debridement with or without subacromial decompression have also been shown in published studies. There appears to be a slight advantage to performing a concomitant acromioplasty for grade I and II partial-thickness tears, with studies using debridement only reporting a lower percentage of good/excellent results and a relatively low return to recreational and elite athletic activity. No comparative studies are available, however. In addition, in the studies that used postoperative imaging as part of their outcome assessment, debridement with acromioplasty was associated with a 6.5% to 34.6% incidence of progression to full-thickness tears after treatment. Furthermore, patients whose lesion progressed were shown to have poorer outcomes than those without tear completion.

The majority of studies describing glenohumeral range-of-motion parameters as part of their outcome assessment showed significant improvement after arthroscopic management. Five studies reported no significant difference between the operative shoulder and the contralateral side after debridement or repair of the partial-thickness lesion.

Unfortunately, none of the 16 studies reviewed analyzed the effect the exact location of the partial-thickness rotator cuff tear had on the surgical results. Observational studies have shown that partial-thickness tears typically occur in 2 varieties, with older patients having tears at the supraspinatus insertion on the greater tuberosity, anterior to that seen in younger, overhead athletes, whose tears tend to occur near the supraspinatus-infraspinatus interval. On the basis of biomechanical models, we would anticipate different strain patterns affecting both debrided and repaired tears at these sites, potentially impacting treatment outcomes. In addition, secondary factors such as SLAP lesion, posterior capsular tightness, or anterior laxity may play a role in the pathogenesis of partial-thickness tears and were not adequately evaluated by the current studies.

Although potential limitations of a systematic review of Level IV studies exist because of variation in patient population and tear types treated and the use of variable surgical techniques and different outcome scoring systems, we believe that useful information can be obtained through this type of analysis (Fig 2). However, it is noted that the overall quality of studies on this subject is limited, and further work to deter-

mine appropriate treatment strategies is required. In summary, this systematic review of 16 clinical studies showed that significant variation is present in the results obtained after the arthroscopic management of partial-thickness rotator cuff tears. Although all treatment methods resulted in significant improvement in symptoms and shoulder function, continued study is required in an effort to determine the optimal management algorithm for this common orthopaedic pathologic lesion.

CONCLUSIONS

There is currently no high-level evidence to support a specific treatment algorithm for partial-thickness rotator cuff pathology. This is because of a large variation in the literature of how this pathology is treated surgically. What can be supported by the data available is that, in general, tears that involve less than 50% of the tendon can be treated with good results by debridement of the tendon with or without a formal acromioplasty. When the tear is greater than 50%, surgical intervention focusing on repair has been successful. There is no evidence to suggest that tear completion and repair is superior or inferior to transtendon repair of these lesions because both methods have been shown to result in favorable outcomes.

REFERENCES

1. Ellman H. Diagnosis and treatment of incomplete rotator cuff tears. *Clin Orthop Relat Res* 1990;64-74.
2. Gonzalez-Lomas G, Kippe MA, Brown GD, et al. In situ transtendon repair outperforms tear completion and repair for partial articular-sided supraspinatus tendon tears. *J Shoulder Elbow Surg* 2008;17:722-728.
3. Ruotolo C, Fow JE, Nottage WM. The supraspinatus footprint: An anatomic study of the supraspinatus insertion. *Arthroscopy* 2004;20:246-249.
4. Mazzocca AD, Rincon LM, O'Connor RW, et al. Intra-articular partial-thickness rotator cuff tears: Analysis of injured and repaired strain behavior. *Am J Sports Med* 2008;36:110-116.
5. Bey MJ, Ramsey ML, Soslowky LJ. Intratendinous strain fields of the supraspinatus tendon: Effect of a surgically created articular-surface rotator cuff tear. *J Shoulder Elbow Surg* 2002;11:562-569.
6. Reilly P, Amis AA, Wallace AL, Emery RJ. Supraspinatus tears: Propagation and strain alteration. *J Shoulder Elbow Surg* 2003;12:134-138.
7. Andarawis-Puri N, Ricchetti ET, Soslowky LJ. Rotator cuff tendon strain correlates with tear propagation. *J Biomech* 2009;42:158-163.
8. Wolff AB, Sethi P, Sutton KM, Covey AS, Magit DP, Medvecky M. Partial-thickness rotator cuff tears. *J Am Acad Orthop Surg* 2006;14:715-725.
9. Yamanaka K, Matsumoto T. The joint side tear of the rotator cuff. A followup study by arthrography. *Clin Orthop Relat Res* 1994;68-73.

10. Amstutz HC, Sew Hoy AL, Clarke IC. UCLA anatomic total shoulder arthroplasty. *Clin Orthop Relat Res* 1981;7:20.
11. Constant CR, Murley AH. A clinical method of functional assessment of the shoulder. *Clin Orthop Relat Res* 1987;160:164.
12. Michener LA, McClure PW, Sennett BJ. American Shoulder and Elbow Surgeons Standardized Shoulder Assessment Form, patient self-report section: Reliability, validity, and responsiveness. *J Shoulder Elbow Surg* 2002;11:587-594.
13. Leggin BG, Michener LA, Shaffer MA, Brenneman SK, Iannotti JP, Williams GR Jr. The Penn shoulder score: Reliability and validity. *J Orthop Sports Phys Ther* 2006;36:138-151.
14. Matsen FA, SK, Parsons M, eds. Effectiveness evaluation and the shoulder. Philadelphia: WB Saunders, 2004.
15. Ide J, Takagi K. Early and long-term results of arthroscopic treatment for shoulder stiffness. *J Shoulder Elbow Surg* 2004;13:174-179.
16. Ide J, Maeda S, Takagi K. A comparison of arthroscopic and open rotator cuff repair. *Arthroscopy* 2005;21:1090-1098.
17. L'Insalata JC, Warren RF, Cohen SB, Altchek DW, Peterson MG. A self-administered questionnaire for assessment of symptoms and function of the shoulder. *J Bone Joint Surg Am* 1997;79:738-748.
18. Neer CS II. Displaced proximal humeral fractures. I. Classification and evaluation. *J Bone Joint Surg Am* 1970;52:1077-1089.
19. Budoff JE, Rodin D, Ochiai D, Nirschl RP. Arthroscopic rotator cuff debridement without decompression for the treatment of tendinosis. *Arthroscopy* 2005;21:1081-1089.
20. Castagna A, Delle Rose G, Conti M, Snyder SJ, Borroni M, Garofalo R. Predictive factors of subtle residual shoulder symptoms after transtendinous arthroscopic cuff repair: A clinical study. *Am J Sports Med* 2009;37:103-108.
21. Castricini R, Panfoli N, Nittoli R, Spurio S, Pirani O. Transtendon arthroscopic repair of partial-thickness, articular surface tears of the supraspinatus: Results at 2 years. *Chir Organi Mov* 2009;93:S49-S54 (Suppl 1).
22. Cordasco FA, Backer M, Craig EV, Klein D, Warren RF. The partial-thickness rotator cuff tear: Is acromioplasty without repair sufficient? *Am J Sports Med* 2002;30:257-260.
23. Deutsch A. Arthroscopic repair of partial-thickness tears of the rotator cuff. *J Shoulder Elbow Surg* 2007;16:193-201.
24. Ide J, Maeda S, Takagi K. Arthroscopic transtendon repair of partial-thickness articular-side tears of the rotator cuff: Anatomical and clinical study. *Am J Sports Med* 2005;33:1672-1679.
25. Kamath G, Galatz LM, Keener JD, Teefey S, Middleton W, Yamaguchi K. Tendon integrity and functional outcome after arthroscopic repair of high-grade partial-thickness supraspinatus tears. *J Bone Joint Surg Am* 2009;91:1055-1062.
26. Kartus J, Kartus C, Rostgard-Christensen L, Sernert N, Read J, Perko M. Long-term clinical and ultrasound evaluation after arthroscopic acromioplasty in patients with partial rotator cuff tears. *Arthroscopy* 2006;22:44-49.
27. Liem D, Alci S, Dedy N, Steinbeck J, Marquardt B, Mollenhoff G. Clinical and structural results of partial supraspinatus tears treated by subacromial decompression without repair. *Knee Surg Sports Traumatol Arthrosc* 2008;16:967-972.
28. Park JY, Yoo MJ, Kim MH. Comparison of surgical outcomes between bursal and articular partial thickness rotator cuff tears. *Orthopaedics* 2003;26:387-390.
29. Porat S, Nottage WM, Fouse MN. Repair of partial thickness rotator cuff tears: A retrospective review with minimum two-year follow-up. *J Shoulder Elbow Surg* 2008;17:729-731.
30. Reynolds SB, Dugas JR, Cain EL, McMichael CS, Andrews JR. Debridement of small partial-thickness rotator cuff tears in elite overhead throwers. *Clin Orthop Relat Res* 2008;466:614-621.
31. Snyder SJ, Pachelli AF, Del Pizzo W, Friedman MJ, Ferkel RD, Pattee G. Partial thickness rotator cuff tears: Results of arthroscopic treatment. *Arthroscopy* 1991;7:1-7.
32. Spencer EE Jr. Partial-thickness articular surface rotator cuff tears: An all-inside repair technique. *Clin Orthop Relat Res* 2010;468:1514-1520.
33. Tauber M, Koller H, Resch H. Transosseous arthroscopic repair of partial articular-surface supraspinatus tendon tears. *Knee Surg Sports Traumatol Arthrosc* 2008;16:608-613.
34. Waibl B, Buess E. Partial-thickness articular surface supraspinatus tears: A new transtendon suture technique. *Arthroscopy* 2005;21:376-381.
35. Miller SL, Hazrati Y, Cornwall R, et al. Failed surgical management of partial thickness rotator cuff tears. *Orthopedics* 2002;25:1255-1257.
36. Gartsman GM, Milne JC. Articular surface partial-thickness rotator cuff tears. *J Shoulder Elbow Surg* 1995;4-6:409-415.
37. Itoi E, Tabata S. Incomplete rotator cuff tears. Results of operative treatment. *Clin Orthop Relat Res* 1992:128-135.
38. Payne LZ, Altchek DW, Craig EV, Warren RF. Arthroscopic treatment of partial rotator cuff tears in young athletes. A preliminary report. *Am J Sports Med* 1997;25:299-305.
39. Weber SC. Arthroscopic debridement and acromioplasty versus mini-open repair in the treatment of significant partial-thickness rotator cuff tears. *Arthroscopy* 1999;15:126-131.
40. Wright SA, Cofield RH. Management of partial-thickness rotator cuff tears. *J Shoulder Elbow Surg* 1996;5-6:458-466.
41. Brockmeier SF, Dodson CC, Gamradt SC, Coleman SH, Altchek DW. Arthroscopic intratendinous repair of the delaminated partial-thickness rotator cuff tear in overhead athletes. *Arthroscopy* 2008;24:961-965.
42. Benson RT, McDonnell SM, Rees JL, Athanasou NA, Carr AJ. The morphological and immunocytochemical features of impingement syndrome and partial-thickness rotator-cuff tear in relation to outcome after subacromial decompression. *J Bone Joint Surg Br* 2009;91:119-123.
43. Andrews JR, Broussard TS, Carson WG. Arthroscopy of the shoulder in the management of partial tears of the rotator cuff: A preliminary report. *Arthroscopy* 1985;1-2:117-122.
44. Lyons TR, Savoie FH III, Field LD. Arthroscopic repair of partial-thickness tears of the rotator cuff. *Arthroscopy* 2001;17:219-223.
45. Lo IK, Burkhart SS. Transtendon arthroscopic repair of partial-thickness, articular surface tears of the rotator cuff. *Arthroscopy* 2004;20:214-220.
46. Wolff AB, Magit DP, Miller SR, Wyman J, Sethi PM. Arthroscopic fixation of bursal-sided rotator cuff tears. *Arthroscopy* 2006;22:1247e11247e4. Available online at www.arthroscopyjournal.org.
47. Budoff JE, Nirschl RP, Guidi EJ. Debridement of partial-thickness tears of the rotator cuff without acromioplasty. Long-term follow-up and review of the literature. *J Bone Joint Surg Am* 1998;80:733-748.
48. Gartsman GM. *Shoulder arthroscopy*. Ed 2. Philadelphia: Saunders Elsevier, 2009.