

Technical Note With Video Illustration

The Arthroscopic Active Compression Test

Nikhil N. Verma, M.D., Mark Drakos, M.D., and Stephen J. O'Brien, M.D.

Abstract: Pathology of the biceps tendon is often a factor in the pathogenesis of shoulder pain. However, diagnosis and management of such pathology remains controversial. Multiple tests have been described to identify pathology related to the biceps tendon and biceps anchor. The active compression test is one such test that has been used clinically to identify patients with superior labral/biceps anchor pathology. An arthroscopic version of this test is described to identify biceps pathology intraoperatively and to aid the surgeon in making diagnostic and treatment decisions. **Key Words:** Biceps tendon—Active compression test—Shoulder arthroscopy.

The knowledge of the biceps tendon as a potential source of pain in the shoulder has been longstanding. However, the diagnosis and management of biceps tendon pathology still remains controversial. The senior author (S.J.O.) has previously described the active compression test to help diagnose superior labral and biceps anchor pathology.¹ Other tests have been described to identify biceps tendonitis or other pathology related to the tendon itself.²⁻⁴ Unfortunately, when used individually, these tests may have a low specificity.

Recently, the senior author has begun performing the active compression test arthroscopically, to aid in the diagnosis of long head biceps tendon pathology as a factor in mechanical intra-articular pain. When performed arthroscopically, this test uses the same principles as the clinical version but allows direct visualization of biceps tendon entrapment. It is important to

note that this test must be correlated with preoperative physical examination findings. When combined with a high level of suspicion of biceps tendon pathology before surgical intervention, this test may aid in intraoperative decision making.

SURGICAL TECHNIQUE

The patient is placed in the beach-chair position on the operating room table. Preoperatively, a thorough examination under anesthesia should be performed to evaluate passive range of motion and potential instability. A standard posterior viewing portal is then established and the arthroscope is introduced. Diagnostic arthroscopy is performed. The test should be performed before the introduction of any anterior instrumentation that could potentially interfere with the biceps tendon morphology.

The test is performed by first placing the arm in 90° of forward flexion with elbow extended. The arm is then adducted 10° to 15° medial to the sagittal plane of the body. Next, the arm is internally rotated while visualizing the biceps tendon from the posterior portal. When this maneuver is performed, the biceps tendon and superior labrum are displaced medially and inferiorly. In the case of an unstable SLAP lesion, the torn labrum may be seen displacing into the glenohumeral joint space, thus being entrapped and compressed within the joint (Fig 1, Video 1). Similarly, in

From the Sports Medicine and Shoulder Service, The Hospital for Special Surgery, Affiliated with the New York Hospital, Cornell University Medical Center, New York, New York, U.S.A.

Address correspondence and reprint requests to Stephen J. O'Brien, M.D., 535 E 70th S, New York, NY 10021, U.S.A. E-mail: obriens@hss.edu

© 2005 by the Arthroscopy Association of North America

Cite this article as: Verma NN, Drakos M, O'Brien SJ. The arthroscopic active compression test. Arthroscopy 2005;21:634.e1-634.e4 [doi:10.1016/j.arthro.2005.02.008].

0749-8063/05/2105-4212\$30.00/0

doi:10.1016/j.arthro.2005.02.008

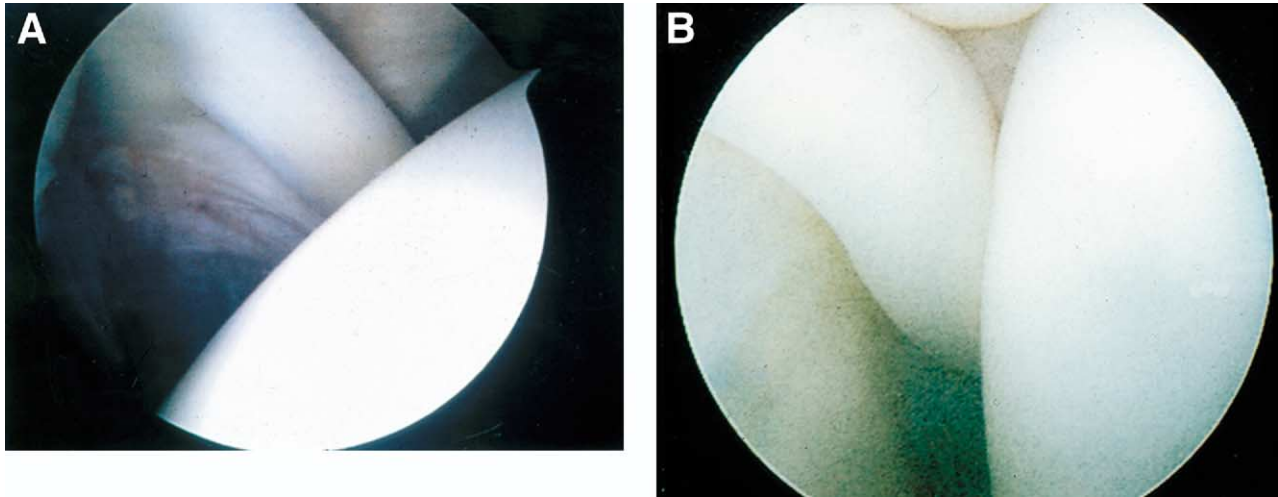


FIGURE 1. (A) Arthroscopic view from the posterior portal of a normal-appearing biceps tendon. This patient had mechanical symptoms. (B) The etiology of these symptoms was identified when performing an arthroscopic active compression and viewing the incarceration of the biceps tendon under direct visualization.

a patient with a normal labrum but biceps tendon pathology, the tendon itself may be seen displacing medially and inferiorly and becoming entrapped within the joint (Fig 2A). When the arm is externally rotated, the entrapment is relieved and the tendon returns to its normal position (Fig 2B). The arthroscopic results should be correlated with preoperative physical examination findings and treatment decisions can then be made. We have noted cases in which the arthroscopic active compression test is positive (Fig 3), but in which the patient had no pain or mechanical

symptoms related to the biceps. In these cases, no treatment is indicated.

DISCUSSION

There continues to be significant controversy over the clinical role of the long head biceps tendon. Some authors believe that the tendon may play an important role in shoulder stability.^{5,6} Others believe that the tendon is clinically insignificant, serving only as a vestigial structure.⁷⁻⁹ Despite this controversy, it is

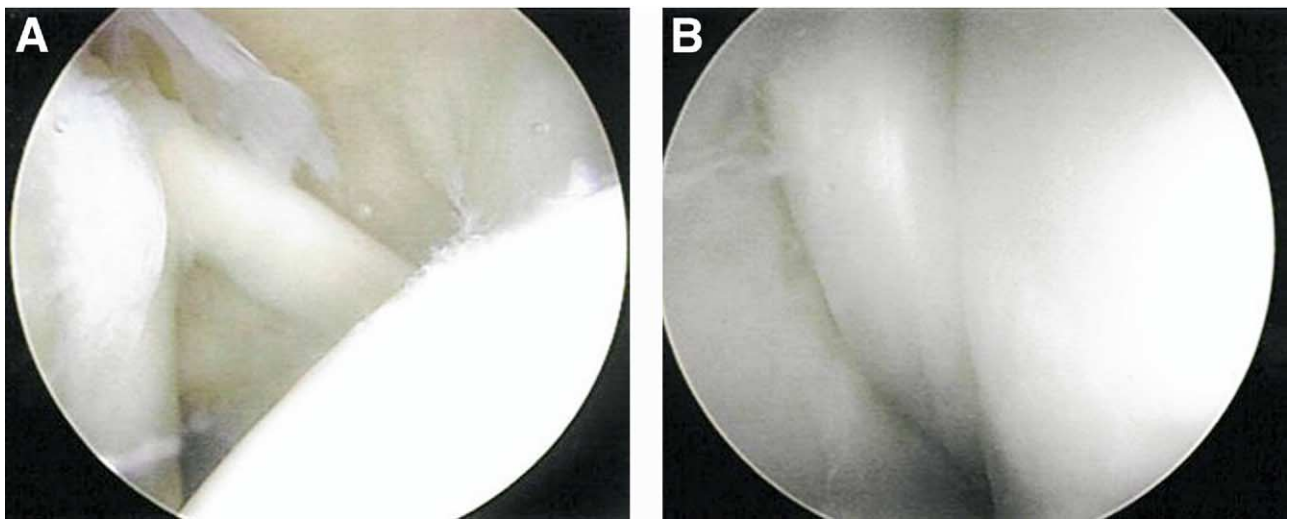


FIGURE 2. (A) Arthroscopic view from a posterior portal showing a type II SLAP lesion. (B) When the arthroscopic active compression test is performed, the biceps tendon can be displaced inferiorly and medially and become entrapped in the glenohumeral joint.

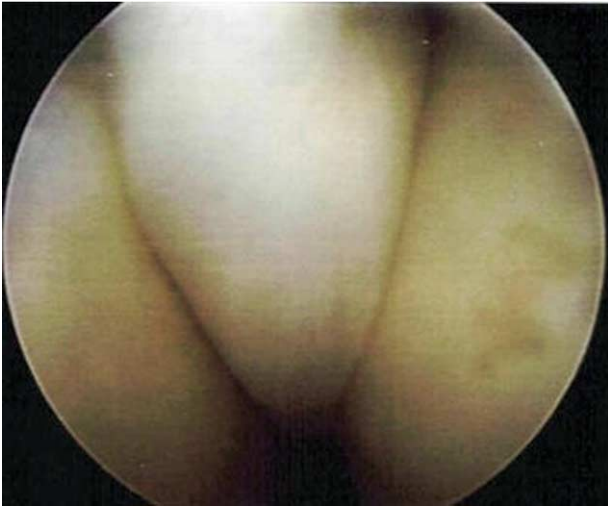

FIGURE 3. This is an arthroscopic active compression test performed in a patient with clicking and mechanical symptoms, but without pain. Subluxation of the tendon within the joint is evident, but because the clicking was not painful no intervention was performed.

commonly accepted that the biceps tendon can play an important role in shoulder pathology and serve as a major pain generator within the shoulder.

The diagnosis and treatment of biceps tendon pathology has remained equally controversial. Multiple tests have been described to identify lesions of the long head biceps tendon and superior labral complex.^{1,3} The most common complaint and physical examination finding associated with biceps pathology is pain over the anterior aspect of the shoulder, often radiating down the anterior aspect of the arm, along the biceps muscle belly. The tendon and bicipital groove can be palpated over the anterior shoulder, approximately 7.5 cm distal to the acromion. Tenderness in this area can be indicative of biceps pathology. The pain is also noted to move laterally with shoulder external rotation.

Speed's test is performed by having the patient resist a downward pressure with the arm forward flexed and the elbow extended with the forearm in supination. The specificity and sensitivity of this test have been reported as 13.8% and 90%, respectively.² Yergason's test is performed by having the patient supinate the forearm against resistance with the elbow in 90° of flexion. Recently, this test was reported to have a sensitivity of only 9% with a specificity of 93%.³ These tests can be used to evaluate the long head biceps tendon in its entirety. Multiple other tests have been described specifically to identify SLAP lesions.

Recently, the ramp test was described to aid in the arthroscopic diagnosis of biceps tendon subluxation.¹⁰ Motley et al. performed an anatomic study and found that selective cutting of the coracohumeral and superior glenohumeral ligaments would allow the biceps tendon to sublux anteriorly and inferiorly while remaining in the bony bicipital groove, thus impinging on the superior fibers of the subscapularis tendon. The authors described an arthroscopic test to help identify this subluxation because direct visualization of the area of injury can be difficult arthroscopically.

In our experience, symptomatic biceps subluxation may occur in 4 distinct cases. The first is the patient who develops shoulder laxity such as an overhead athlete or swimmer. In this case, the increased shoulder laxity may allow biceps subluxation within the glenohumeral joint causing mechanical symptoms. The second case is the patient with an unstable biceps anchor or superior labrum (SLAP tear). The third case is that of an unstable long head biceps pulley such as a tear of the transverse humeral ligament. Again, this lesion will destabilize the long head biceps tendon and may allow symptomatic subluxation within the joint. The fourth scenario involves the presence of a subscapularis tendon tear that destabilizes the biceps pulley complex.

The senior author originally described the active compression test in 1998.¹ In the original description, this test was used clinically to identify acromioclavicular joint abnormality or lesions of the superior labrum. The distinction was made based on the location of pain with the arm in the adducted position. With regard to labral abnormalities, the sensitivity of this test was reported as 100% with a specificity of 98.5%. Other authors, however, have reported significantly lower values.³ Currently, the most commonly used physical examination approach is to combine the patients' complaints with the results of multiple clinical tests to attempt to make a definitive diagnosis. However, even when using this approach, patients often have overlapping pathology and a single definitive diagnosis may be hard to obtain.

Another specific controversy that currently exists is the surgical treatment of symptomatic biceps tendon pathology in the absence of a labral lesion. After failed conservative management, surgery is often considered. The tendon is examined arthroscopically for evidence of tenosynovitis, fraying, or frank tears. Surgical treatment may include primary repair, tenotomy, or tenodesis. We have used the arthroscopic active compression test to aid in surgical decision making in this situation. If the patient has demonstrated symp-

toms when performing the active compression clinically, and the arthroscopic active compression test shows incarceration of the biceps tendon, we perform a long head biceps tenotomy or arthroscopic transfer to the conjoint tendon depending on the age of the patient. We have found seemingly normal-appearing tendons in patients with biceps tendon symptoms. When these tendons have demonstrated a positive arthroscopic active compression test, patients have responded well to biceps tenotomy, tenodesis, or transfer. If the arthroscopic active compression test had not been used, this pathology may be easily missed. In our opinion, debridement alone is not successful in this situation because it does not eliminate the incarceration of the biceps tendon within the joint. Again, it is important to state that we have had cases in which the arthroscopic active compression test is positive, but the patient has not had symptoms. In these cases, the tendon was left intact. Thus correlation to clinical examination findings is crucial to the success of this test.

Diagnosis and treatment of long head biceps tendon pathology remains difficult and controversial. No one specific physical examination test can be used to reliably diagnose all types of biceps pathology. Once the biceps has been identified as a source of shoulder pain, controversy also exists over definitive treatment. Conservative management should be tried initially in most cases, including physical therapy and anti-inflammatory medications. When this fails, surgical options include debridement, repair, tenotomy, or tenodesis. In these cases, the arthroscopic active compression test can be used as intra-operative confirmation of biceps pathology when correlated with preoperative

physical examination, and can aid in surgical management decision making.

APPENDIX. SUPPLEMENTARY DATA

Supplementary data associated with this article can be found, in the online version, at [doi:10.1016/j.arthro.2005.02.008](https://doi.org/10.1016/j.arthro.2005.02.008)

REFERENCES

- O'Brien SJ, Pagnani MJ, Fealy S, McGlynn SR, Wilson JB. The active compression test: A new and effective test for diagnosing labral tears and acromioclavicular joint abnormality. *Am J Sports Med* 1998;26:610-613.
- Bennett WF. Specificity of the Speed's test: Arthroscopic technique for evaluating the biceps tendon at the level of the bicipital groove. *Arthroscopy* 1998;14:789-796.
- McFarland EG, Kim TK, Savino RM. Clinical assessment of three common tests for superior labral anterior-posterior lesions. *Am J Sports Med* 2002;30:810-815.
- Neviaser RJ. Lesions of the biceps and tendonitis of the shoulder. *Orthop Clin North Am* 1980;11:343-348.
- Kumar VP, Satku K, Balasubramaniam P. The role of the long head of biceps brachii in the stabilization of the head of the humerus. *Clin Orthop Rel Res* 1989;244:172-175.
- Rodosky MW, Harner CD, Fu FH. The role of the long head of the biceps muscle and superior glenoid labrum in anterior stability of the shoulder. *Am J Sports Med* 1994;22:121-130.
- Lippmann RK. Bicipital Tenosynovitis. *N Y State J Med* 1944;Oct:2235-2241.
- Levy AS, Kelly B, Lintner S, Speer KP. The function of the long head of the biceps at the shoulder: an EMG analysis. *J Shoulder Elbow Surg* 2001;10:250-255.
- Yamaguchi K, Riew KD, Galatz LM, Syme JA, Neviaser RJ. Biceps activity during shoulder motion: An electromyographic analysis. *Clin Orthop* 1997;336:122-129.
- Motley GS, Osbahr DC, Holovac TF, Speer KP. An arthroscopic technique for confirming intra-articular subluxation of the long-head of the biceps tendon: The ramp test. *Arthroscopy* 2002;18:E46 (available online at www.arthroscopyjournal.org).