

Systematic Review

Allograft Reconstruction for Glenoid Bone Loss in Glenohumeral Instability: A Systematic Review

Eli T. Sayegh, B.S., Randy Mascarenhas, M.D., Peter N. Chalmers, M.D.,
Brian J. Cole, M.D., M.B.A., Nikhil N. Verma, M.D., and Anthony A. Romeo, M.D.

Purpose: The aim of this study was to assess clinical outcomes and radiological outcomes after osteochondral allograft reconstruction for glenoid bone loss. **Methods:** Glenoid bone loss can occur in the setting of recurrent glenohumeral instability and poses a challenge for surgeons. Reconstruction of these defects with allografts has been proposed as an alternative to both arthroscopic stabilization and nonanatomic bony augmentation procedures with autografts. We conducted a systematic review of the literature for studies of any level of evidence that reported clinical or radiological outcomes (or both) after allograft reconstruction for glenoid deficiency in the setting of recurrent shoulder instability. Data collected included study and patient characteristics, surgical technique, outcome scores, range of motion, strength, subjective outcomes, radiological outcomes, and complications. Data from studies with a sample size of at least 5 were pooled in the main analysis. Studies were assessed for the presence of methodological bias. **Results:** Eight studies met the inclusion criteria and were included in the review. Three studies were deemed eligible for pooled analysis. The study group consisted of 70 shoulders with a mean age of 27.7 years (74.6% of participants were men) and a mean follow-up period of 44.5 ± 17.7 (range, 32 to 90) months. The mean final Rowe score was 90.6, representing a mean improvement of 57.5. Only 9.8% of patients complained of persistent or unimproved pain, and 93.4% were satisfied. Bony integration of the allograft was documented in 100% of shoulders. Recurrence of glenohumeral dislocation and overall instability were seen in 2.9% and 7.1% of cases, respectively. **Conclusions:** The current body of Level IV data suggests that allograft reconstruction for glenoid bone loss provides excellent clinical outcomes, low rates of recurrent instability, and high osseous incorporation rates with no evidence of graft resorption. **Level of Evidence:** Level IV, systematic review of Level IV studies.

Glenoid bone loss can play a significant role in recurrent glenohumeral instability and is often identified as the source of failure after shoulder stabilization.^{1,2} The prevalence of anteroinferior glenoid rim deficiency in recurrent instability ranges from 5% to more than 70% of cases.³⁻⁵ The likelihood of glenoid bone

loss is increased in patients with chronic recurrent instability, a high-energy mechanism of injury (i.e., in collision athletes), and a history of recurrent dislocations occurring with less force.⁶ Loss of the anteroinferior glenoid rim leads to loss of the glenoid articular arc, compromising the concavity compression mechanism and thus increasing the risk of recurrence of instability. It also reduces the articulating surface area of the glenoid, which may potentially increase contact pressures and the risk of future degenerative joint disease. Arthroscopic Bankart repair has been associated with a recurrence rate of 4% in the absence of significant glenoid bone loss versus 67% in patients with greater than 25% loss of inferior glenoid diameter or an engaging Hill-Sachs lesion.¹ Untreated glenoid deficiency can also limit the recovery of range of motion after Bankart repair^{7,8} and is a recognized cause of failed shoulder stabilization surgery.⁶

Glenoid reconstruction is typically indicated in situations of 25% or greater bone loss⁹⁻¹¹ or when revision stabilization becomes necessary.¹² The surgical management of glenoid deficiency is challenging. Both open^{1,13} and arthroscopic¹⁴⁻²⁰ techniques have been used, and common strategies include the use of

From College of Physicians and Surgeons (E.T.S.), Columbia University, New York, New York; and Department of Orthopaedic Surgery (R.M., P.N.C., B.J.C., N.N.V., A.A.R.) Rush University Medical Center, Chicago, Illinois, U.S.A.

The authors report the following potential conflict of interest or source of funding in relation to this article: B.N.C. receives support from Arthrex, DJ Orthopaedics, Johnson & Johnson, Medipost, Regentis, Zimmer, Smith & Nephew, Carticept; N.N.V. receives support from Smith & Nephew, Vindico Medical, Major League Baseball, Omeros, Arthrex, Ossur, and Linvatec; and A.A.R. receives support from Arthrex, DJO Surgical, Smith & Nephew, Ossur. The work for this article was performed at Rush University Medical Center, Chicago, Illinois.

Received April 26, 2014; accepted May 13, 2014.

Address correspondence to Eli T. Sayegh, B.S., Columbia University College of Physicians and Surgeons, 630 West 168th Street No. 459, New York, NY 10032-3784. E-mail: etsayegh@gmail.com

*© 2014 by the Arthroscopy Association of North America
0749-8063/14355/\$36.00*

<http://dx.doi.org/10.1016/j.arthro.2014.05.007>

coracoid transfer^{11,21,22} and iliac crest autografts²³ or allografts.^{12,24-29} Although these procedures have been successful in restoring glenohumeral stability, nonanatomic coracoid transfer procedures to address glenoid bone loss have been associated with progression to instability arthropathy.³⁰

Osteochondral allografts have been widely used in the management of articular pathologic conditions, especially osteochondral lesions of the knee.³¹ This technique was first described successfully in the shoulder by Gerber and Lambert³² for the treatment of chronic locked posterior shoulder dislocation. There are several advantages to the use of allografts over autografts in reconstructive procedures for glenoid bone loss, including a more anatomic restoration of the articular contour and the addition of a cartilaginous interface for articulation with the humeral head. The theoretical benefits of this cartilaginous interface include a decrease in the risk of future instability arthropathy and the prevention of recurrence by restoration of the natural glenoid concavity. However, the reliability of allograft incorporation into the glenoid without resorption has yet to be evaluated.

The objective of this review was to assess clinical and radiological outcomes after osteochondral allograft reconstruction for glenoid bone loss. To our knowledge, this is the first systematic review examining the use of allografts to the glenoid in the setting of chronic glenohumeral instability. We hypothesized that allograft reconstruction would provide excellent clinical outcomes, low recurrence rates, and of foremost interest, high rates of radiographic union.

Methods

Eligibility Criteria

This systematic review was performed according to the Preferred Reporting Items for Systematic Reviews and Meta-analyses (PRISMA) guidelines. Therapeutic studies were included if they addressed glenoid deficiency in the setting of glenohumeral instability with allograft reconstruction. Studies were excluded if they (1) used an autograft, (2) did not identify the anatomic source of the allograft, (3) treated only humeral head deficiency, or (4) used glenoid reconstruction in the setting of tumor resection or revision shoulder arthroplasty. No restrictions were imposed on publication date, study design, level of evidence, or follow-up period, although studies that did not report the follow-up period were also excluded. Laboratory studies and review or technique-only articles were excluded.

Literature Search

Two independent reviewers performed the literature search to identify eligible studies. MEDLINE, EMBASE, and Scopus were queried to identify relevant English-language studies. The search term was as follows:

“glenoid AND graft.” The resulting study titles and abstracts were reviewed according to the eligibility criteria. Full articles were procured and reviewed for potentially eligible studies, and their citations were manually screened in an effort to identify additional studies that might have been missed. A PRISMA trial flow shows the study selection algorithm (Fig 1).

Data Extraction

Data were extracted for study and patient characteristics, surgical technique, outcome scores, range of motion, strength, subjective outcomes, radiological outcomes, and complications. Outcome scores included the Rowe⁴; Constant³³; American Shoulder and Elbow Surgeons³⁴; University of California, Los Angeles³⁵; and Disabilities of the Arm, Shoulder, and Hand³⁶ scores. Range-of-motion parameters included forward flexion, abduction, external rotation (ER) in the adducted position, and internal rotation (IR). Recurrence of instability was defined as recurrent dislocation, subluxation, apprehension, or a combination of these conditions. Finally, studies were assessed for the presence of methodological bias, including selection, detection, performance, and attrition biases.

Data Synthesis

Data from studies with a sample size of at least 5 were pooled in the main analysis. Data aggregation was performed when an outcome was uniformly reported by more than one study. Continuous data were analyzed through calculation of weighted means and standard deviations. Dichotomous data were analyzed through summation of the number of events and total observations to compute an aggregated rate. All other data were summarized in descriptive fashion.

Results

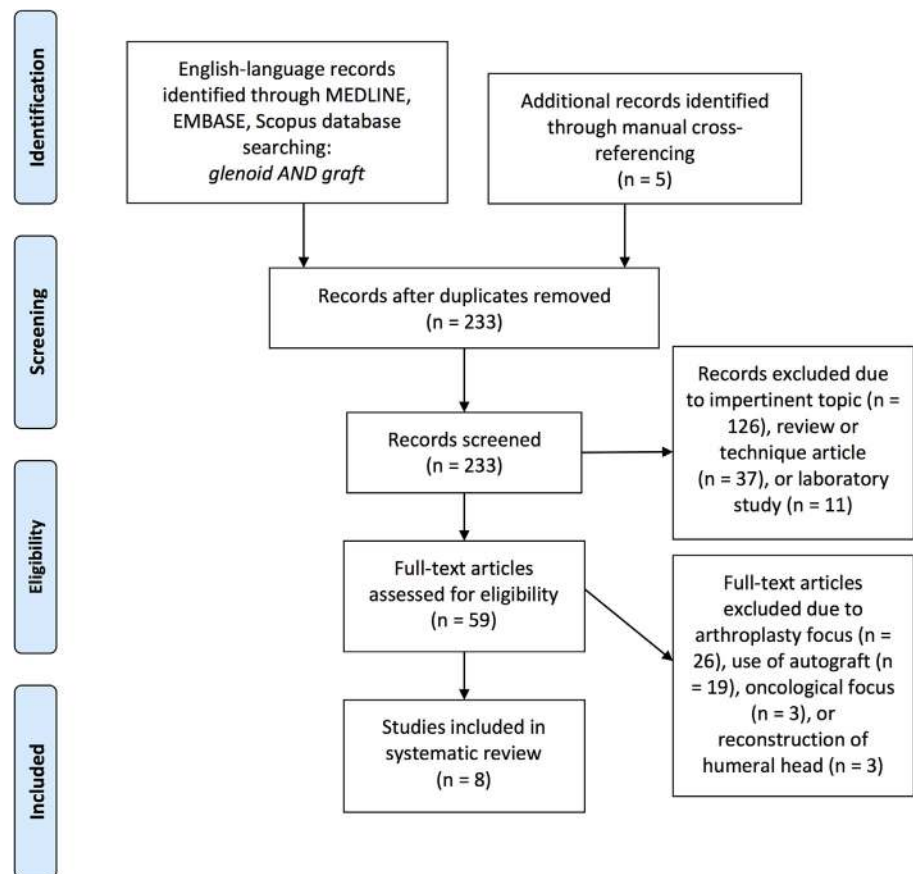
Literature Search

The literature search identified 233 studies whose titles and abstracts were preliminarily screened. Full-text articles for 59 studies were procured and reviewed. After application of the eligibility criteria, 8 studies^{12,25-29,37,38} published from 1995 to 2014 remained and were included in the systematic review (Table 1). The 3 studies^{25,29,38} with a sample size greater than 5 were included in the pooled analyses.

Patient Characteristics

Of the 8 studies, the 3 studies^{25,29,38} included in the pooled analyses contained a total of 70 shoulders with follow-up data (Table 2). The weighted mean follow-up period and age were 44.5 ± 17.7 (range, 32 to 90) months and 27.7 years, respectively. The proportion of male patients and dominant or right arms was 74.6% and 68.0%, respectively. Previous surgery had

Fig 1. Preferred Reporting Items for Systematic Reviews and Meta-Analyses (PRISMA) trial flow describing the inclusion process for the studies in the systematic review.



been performed in 10.3% of shoulders and included capsular shift, Bankart repair, and Bristow or Putti-Platt procedures.

Surgical Technique

The 3 studies included in the pooled analysis used either iliac crest bicortical allografts³⁸ or femoral head allografts.^{25,29} The remaining 5 studies used distal tibial allografts,^{12,26,37} glenoid allografts,²⁷ or humeral head bicortical allografts²⁸ (Table 3). The tissue preservation status of the graft was fresh in 2 studies^{12,26,27} and

cryopreserved in one study.²⁸ The beach chair surgical position was used in 3 of 5 studies,^{12,25,29} whereas the surgical approach was arthroscopic in 2 studies^{37,38} and deltopectoral in 4 studies.^{12,25,28,29} Although Zhao et al.³⁸ used suture anchor fixation, the remainder of studies used cortical or cancellous screw fixation of the graft at the osteotomy site.²⁶

Outcome Scores

Two of the 3 studies provided both preoperative and postoperative outcome scores^{29,38} (Table 4). The

Table 1. Overview of Included Studies

First Author (Year)	Study Design	Level of Evidence	Shoulders (n)	Follow-up Period (mo)	Follow-up Rate (%)	Bias
Zhao (2014) ³⁸	Retrospective case series*	IV	52	38.8 (24-64)	80.0	Selection, detection
Weng (2009) ²⁹	Prospective case series	IV	9	90 (54-168)	100	Detection
Hutchinson (1995) ²⁵	Retrospective case series	IV	9	32 (8-61)	88.2	Selection, detection
Provencher (2009) ¹²	Retrospective case series	IV	3	—	NA	Selection, detection
Millett (2013) ²⁶	Case report	IV	2	> 24	NA	Selection, detection
Gupta (2013) ³⁷	Case report	IV	1	12	NA	Selection, detection
Petrera (2013) ²⁷	Case report	IV	1	24	NA	Selection, detection
Tjoumakaris (2008) ²⁸	Case report	IV	1	—	NA	Selection, detection

NA, not available.

*The study design of Zhao et al. was a retrospective study of prospectively collected data.

Table 2. Demographic Characteristics of Included Studies

First Author (Year)	Shoulders (n)	Age (yr)	Male Sex (%)	Dominant (D) or Right (R) Arm (%)	Duration of Instability (mo)	Previous Surgery (%)	Type of Previous Surgery
Zhao (2014)	52	26.3 (19-35)	75.0	—	54.1 (27-99)	0	—
Weng (2009)	9	34.6 (21-63)	77.8	66.7 (D)	> 6	33.3	Unspecified Bankart repair (2), capsular shift (1)
Hutchinson (1995)*	9	29.1 (19.4-46)	69.2	69.2 (D)	—	47.1	Unspecified Bankart repair (3), Bristow procedure (3), Putti-Platt procedure (6)
Provencher (2009)	3	20.2 (18-23)	—	—	—	66.7	Open (1) or arthroscopic Bankart repair (1)
Millett (2013)	2	15.5 (15-16)	100	—	—	50	Posterior capsulolabral repair (1), iliac crest autograft glenoid reconstruction (1)
Gupta (2013)	1	29	100	100 (R)	—	—	—
Petrera (2013)	1	54	100	100 (R)	—	—	—
Tjoumakaris (2008)	1	19	100	0 (R)	24	0	—

*The series of Hutchinson et al. contained 15 patients in total, including an additional 6 patients treated with autografts, who were excluded from analysis in this review.

weighted mean final Rowe score was 90.6 ± 2.8 , representing a weighted improvement of 57.5 ± 1.5 from the preoperative value, based on 2 studies.^{29,38} Hutchinson et al.²⁵ reported a mean final Constant score of 91.3 in their 9 patients.

Range of Motion and Strength

ER was nonuniformly assessed in the 3 studies, and IR was assessed in one study. Zhao et al.³⁸ documented deficits in ER at postoperative follow-up in 2 of 52 patients in the adducted position and 5 of 52 patients in the abducted position, with deficits greater than 10° in 2 patients. Weng et al.²⁹ noted a mean loss in ER of 7° in their cohort of 9 patients. Although Hutchinson et al.²⁵ did not provide a preoperative measurement, they reported a mean postoperative ER of 38° during adduction and 63° during abduction. Zhao et al.³⁸ noted a deficit in IR in 2 of 52 patients. Hutchinson et al.²⁵ were the sole authors to assess postoperative strength.

Using the 25-point Constant strength score, they reported postoperative scores of 23.1 for abduction, 18.4 for ER, and 20.1 for IR.

Subjective Outcomes

Pain improvement or resolution was achieved in 90.2% of patients in 2 studies.^{29,38} Only one study quantitatively assessed pain status using the Constant pain score.²⁵ Ninety-four percent of patients were satisfied after the allograft reconstruction in 2 studies.^{25,38}

Radiological Outcomes

Bony integration of the allograft was assessed in 2 studies^{29,38} and was achieved in 100% of patients, with all bony unions occurring within 6 months. Computed tomography and magnetic resonance imaging were used in one study,³⁸ whereas the other used standard radiography.²⁹ Zhao et al.³⁸ further reported that the mean glenoid defect width changed from 32.7%

Table 3. Surgical Technique in Included Studies

First Author (Year)	Graft Source	Graft Preservation	Surgical Approach	Surgical Position	Fixation Method	Augmentation
Zhao (2014)	Iliac crest bicortical allograft	—	Arthroscopic	Lateral decubitus	2 suture anchors	—
Weng (2009)	Femoral head allograft	—	Deltpectoral	Beach chair	2 cortical screws	—
Hutchinson (1995)	Femoral head allograft	—	Deltpectoral	Beach chair	2 large cortical screws	—
Provencher (2009)	Distal tibial allograft	Fresh	Deltpectoral	Beach chair	2 fully threaded cortical screws	—
Millett (2013)	Distal tibial allograft	Fresh	—	Lateral decubitus	Lag screw	BMP-7
Gupta (2013)	Distal tibial allograft	—	Arthroscopic	—	—	—
Petrera (2013)	Glenoid allograft	Fresh	—	—	2 small cancellous screws with washers	—
Tjoumakaris (2008)	Humeral head bicortical allograft	Cryopreserved	Deltpectoral	—	3 headless cannulated screws	—

BMP, bone morphogenetic protein.

Table 4. Outcomes in Included Studies

First Author (Year)	Reconstructive Technique	Outcome Scores	Range of Motion (°)	Strength	Pain	Satisfaction	Return to Activity	Radiological Outcomes
Zhao (2014)	Iliac crest bicortical allograft	Oxford (pre): 29.7 Oxford (post): 42.4 Rowe (pre): 34.7 Rowe (post): 91.8	Deficits: > 10° external rotation (2 of 52) ER (adduction) (2 of 52) ER (abduction) (5 of 52) IR (2 of 52)	—	Persistent slight pain: 6 of 52	48 of 52	—	Integration: 52 of 52 (CT) Progression of arthrosis: 0 of 52 Glenoid edema: 3 of 52 9 of 9 integrated (XR)
Weng (2009)	Femoral head allograft	Rowe (pre) = 24 Rowe (post) = 84*	Loss of ER = 7	—	9 of 9 improved	—	0 of 9 limited in ADL	—
Hutchinson (1995) [†]	Femoral head allograft	Constant (post) = 91.3	ER = 38 (adduction) ER = 63 (abduction)	Abduction [‡] = 23.1 ER = 18.4 IR = 20.1 of 25	Constant (pain): 14 of 15	9 of 9	Constant (ADL) = 19.9 of 20	—
Provencher (2009)	Distal tibial allograft	—	—	—	—	—	—	3 of 3 integrated (CT)
Millett (2013)	Distal tibial allograft	DASH (post) = 9 ASES (post) = 86	—	—	2 of 2 improved VAS (post) = 2	—	2 of 2 (sport)	2 of 2 integrated (CT)
Gupta (2013)	Distal tibial allograft	—	Regained full range of motion	—	—	—	1 of 1 (work)	1 of 1 integrated (CT)
Petrera (2013)	Glenoid allograft	—	Complete forward flexion Abduction, ER, and IR limited to thoracolumbar level	Forward flexion = 5 of 5 Abduction = 5 of 5 ER = 5 of 5 IR = 5 of 5	—	1 of 1	0 of 1 limited in ADL	1 of 1 integrated (XR) Concentric glenohumeral alignment: 1 of 1
Tjoumakaris (2008)	Humeral head bicortical allograft	—	—	Normal	Improved	—	—	1 of 1 integrated (XR + CT)

ADL, activities of daily living; ASES, American Shoulder and Elbow Surgeons; CT, computed tomography; DASH, Disabilities of the Arm, Shoulder, and Hand; ER, external rotation; IR, internal rotation; pre, preoperative; post, postoperative; ROM, range of motion; XR, radiography; VAS, visual analog scale.

*indicates a statistically significant improvement.

[†]The Constant score and subscores reported by Hutchinson et al.²⁵ refer to their entire cohort, which additionally included 6 patients treated with autografts.

[‡]Hutchinson et al.²⁵ used the Constant scoring system to rate strength.

Table 5. Aggregated Demographic and Outcome Statistics for Included Studies

Variable	No. of Studies	No. of Shoulders	Weighted Mean
Demographics			
Follow-up rate (%)	3	70	83.6
Follow-up period (mo)	3	70	44.5
Age (yr)	3	70	27.7
Male sex (%)	3	70	74.6
Dominant or right arm (%)	2	18	68.0
Previous surgery (%)	3	70	10.3
Outcomes			
Final Rowe score	2	61	90.6
Improvement in Rowe score	2	61	57.5
Pain improvement or resolution (%)	2	61	90.2
Patient satisfaction (%)	2	61	93.4
Bony integration (%)	2	61	100
Recurrence of instability (%)	3	70	7.1
Graft resorption (%)	2	18	0
Hardware prominence (%)	2	18	0

to -16.3% , whereas the mean glenoid defect area changed from 28.3% to -16.9% . Increases in the final glenoid surface area and glenoid width were achieved in 94.2% and 96.2% of their patients, respectively. None of the patients in their cohort experienced progression of arthrosis, which was present preoperatively in 36 of 52 patients, according to the Samilson and Prieto classification system. Persistent edema on magnetic resonance imaging around the graft was noted in 3 of 52 patients at 24 months.

Complications

Weng et al.²⁹ were the only authors to comment on the rate of overall complications, which was 0 of 9 in their cohort. All 3 studies assessed patients for recurrence of glenohumeral instability, which occurred in 7.1% of patients and consisted of 2 dislocations, one subluxation, and 2 instances of apprehension. Thus, the rate of recurrent dislocation was 2.9% . Neither graft resorption nor hardware prominence occurred in any patients in 2 studies.^{25,29}

Bias

All 3 studies were Level IV case series. As a result, they were susceptible to selection bias, with the exception of one study that was a series of consecutive patients.²⁹ Two of 3 studies had a prospective design for data collection.^{29,38} Because none of the studies indicated the use of an independent examiner to evaluate patients, detection bias was possible in all cases. A control group was not used in any study. Statistical power, as a function of sample size, was limited in all but one study.³⁸ Performance bias was present in only one study,³⁸ resulting from the performance of concomitant procedures, namely, Bankart or bony

Bankart repair. None of the 3 studies was subject to attrition bias because of a follow-up rate of 80% or greater in all cases.

Reports from Smaller Studies

In addition to the 3 studies included in the preceding analyses, 5 small case series and case reports have reported outcomes after the use of allograft Le Fort glenoid reconstruction in the setting of recurrent shoulder instability. Using a cryopreserved humeral head bicortical allograft, Tjoumakaris et al.²⁸ noted graft incorporation on CT in their sole patient. Using a fresh distal tibial allograft, Provencher et al.¹² reported graft integration on CT without resorption in all 3 patients. Petrer et al.,²⁷ who used a fresh glenoid allograft, also noted radiographic integration and concentric glenohumeral joint alignment in their sole patient. Using a fresh distal tibial allograft, Millett et al.²⁶ noted tomographic graft incorporation in both patients. Most recently, Gupta et al.,³⁷ who used a distal tibial allograft arthroscopically, noted tomographic graft integration in their sole patient.

Discussion

Allograft reconstruction of glenoid bone loss represents a potential alternative to the conventional techniques of arthroscopic stabilization and nonanatomic coracoid transfer procedures. However, the reliability of allograft incorporation into the glenoid without resorption has yet to be definitively established. This review identified 8 Level IV studies examining the efficacy and complications associated with allograft reconstruction for glenoid bone loss in the setting of recurrent glenohumeral instability (Table 5). Taken collectively, these data show that allograft reconstruction of the glenoid has excellent clinical outcomes, a low rate of recurrent instability, high rates of graft union, and very low rates of graft resorption. The Rowe score, a validated clinical assessment of shoulder instability, was improved by an average of 57.5 points and showed an excellent mean final score of 90.6. Ninety-three percent of patients were satisfied with the outcome of surgery, and more than 90% experienced pain improvement or resolution. Bony integration of the graft was achieved in 100% of shoulders at long-term follow-up of 44.5 months, with no signs of graft resorption, whereas recurrence of glenohumeral instability was observed in only 7.1% of shoulders.

Several sources of allografts have been used to address glenoid deficiency, including glenoid,²⁷ iliac crest,³⁸ distal tibia,^{12,26} femoral head,²⁹ and humeral head²⁸ allografts. These come in the form of osseous or osteochondral allografts, the latter of which theoretically restores the anatomic articular arc of the glenoid, including both the bone and hyaline articular cartilage surfaces.³⁹ As such, the technique is suitable for the treatment of

osteocondritis dissecans and focal chondral defects and has been used extensively for this purpose in the knee.^{24,38,39} Because the 3 studies included in our pooled analyses used osseous rather than osteochondral grafts, any potential advantages of cartilage-bearing allografts require further investigation.

There are innate disadvantages to the use of allografts. Donor tissue may not be readily obtainable in all cases and carries a miniscule risk of disease transmission,³⁹ including a less than one in 1,000,000 risk of human immunodeficiency transmission when proper precautions are used.⁴⁰ Cryopreservation may undermine the tissue viability and overall function of the allograft, because chondrocyte viability is reduced both in vitro⁴¹ and in clinical specimens⁴² relative to fresh allografts. However, the use of fresh allografts is logistically challenging because they must be used within 14 to 28 days⁴³ to avoid biological decline of the tissue.⁴⁴

Limitations

There are several limitations to this study. Because all included studies were of Level IV evidence, the likelihood of methodological bias is increased, and no comparison of allograft reconstruction against other techniques was possible. Each study contained one or more demonstrable biases, including selection, detection, attrition, or a combination of these biases. Although the smaller case series and case reports used several different clinical scoring systems, only the Rowe score was amenable to pooling in the main analysis. Pooled analysis of range of motion and strength was not possible because of nonuniform or limited outcome reporting. Aside from recurrent instability, complications were not extensively assessed in these studies. However, no significant complications were associated with this procedure in any of the reports.

Further research, ideally in the form of well-designed controlled trials or cohort studies, or both, is required to determine the comparative efficacy and safety of this technique relative to the nonanatomic bony augmentation procedures that have been favored historically. Additionally, the optimal anatomic source of the allograft represents an important question for continued investigation.

Conclusions

The current body of Level IV data suggests that allograft reconstruction for glenoid bone loss provides excellent clinical outcomes, low rates of recurrent instability, and high osseous incorporation rates with no evidence of graft resorption.

References

- Burkhart SS, De Beer JF. Traumatic glenohumeral bone defects and their relationship to failure of arthroscopic Bankart repairs: Significance of the inverted-pear glenoid and the humeral engaging Hill-Sachs lesion. *Arthroscopy* 2000;16:677-694.
- Kummel BM. Fractures of the glenoid causing chronic dislocation of the shoulder. *Clin Orthop Relat Res* 1970;69:189-191.
- Rowe CR, Patel D, Southmayd WW. The Bankart procedure: A long-term end-result study. *J Bone Joint Surg Am* 1978;60:1-16.
- Rowe CR, Sakellarides H. Factors related to recurrences of anterior dislocations of the shoulder. *Clin Orthop* 1961;20:40.
- Symeonides PP. The significance of the subscapularis muscle in the pathogenesis of recurrent anterior dislocation of the shoulder. *J Bone Joint Surg Br* 1972;54:476-483.
- Provencher CMT, Bhatia S, Ghodadra NS, et al. Recurrent shoulder instability: Current concepts for evaluation and management of glenoid bone loss. *J Bone Joint Surg* 2010;92:133-151.
- Itoi E, Lee SB, Amrami KK, Wenger DE, An KN. Quantitative assessment of classic anteroinferior bony Bankart lesions by radiography and computed tomography. *Am J Sports Med* 2003;31:112-118.
- Itoi E, Lee SB, Berglund LJ, Berge LL, An KN. The effect of a glenoid defect on anteroinferior stability of the shoulder after Bankart repair: A cadaveric study. *J Bone Joint Surg Am* 2000;82:35-46.
- Hovelius LK, Sandstrom BC, Rosmark DL, Saebo M, Sundgren KH, Malmqvist BG. Long-term results with the Bankart and Bristow-Latarjet procedures: Recurrent shoulder instability and arthropathy. *J Shoulder Elbow Surg* 2001;10:445-452.
- Pagnani MJ. Open capsular repair without bone block for recurrent anterior shoulder instability in patients with and without bony defects of the glenoid and/or humeral head. *Am J Sports Med* 2008;36:1805-1812.
- Schroder DT, Provencher MT, Mologne TS, Muldoon MP, Cox JS. The modified Bristow procedure for anterior shoulder instability: 26-year outcomes in Naval Academy midshipmen. *Am J Sports Med* 2006;34:778-786.
- Provencher MT, Ghodadra N, LeClere L, Solomon DJ, Romeo AA. Anatomic osteochondral glenoid reconstruction for recurrent glenohumeral instability with glenoid deficiency using a distal tibia allograft. *Arthroscopy* 2009 Apr;25:446-452.
- Bigliani LU, Newton PM, Steinmann SP, Connor PM, McIlveen SJ. Glenoid rim lesions associated with recurrent anterior dislocation of the shoulder. *Am J Sports Med* 1998 Jan-Feb;26:41-45.
- Boileau P, Bicknell RT, El Fegoun AB, Chuinard C. Arthroscopic Bristow procedure for anterior instability in shoulders with a stretched or deficient capsule: the "belt-and-suspenders" operative technique and preliminary results. *Arthroscopy* 2007;23:593-601.
- Kim SH, Ha KI, Kim YM. Arthroscopic revision Bankart repair: A prospective outcome study. *Arthroscopy* 2002;18:469-482.
- Mologne TS, Provencher MT, Menzel KA, Vachon TA, Dewing CB. Arthroscopic stabilization in patients with an inverted pear glenoid: Results in patients with bone loss of the anterior glenoid. *Am J Sports Med* 2007;35:1276-1283.

17. Lafosse L, Lejeune E, Bouchard A, Kakuda C, Gobezie R, Kochhar T. The arthroscopic Latarjet procedure for the treatment of anterior shoulder instability. *Arthroscopy* 2007 Nov;23:1242.e1241-1242.e1245.
18. Sugaya H, Moriishi J, Kanisawa I, Tsuchiya A. Arthroscopic osseous Bankart repair for chronic recurrent traumatic anterior glenohumeral instability. *J Bone Joint Surg Am* 2005 Aug;87:1752-1760.
19. Arrigoni P, Huberty D, Brady PC, Weber IC, Burkhart SS. The value of arthroscopy before an open modified latarjet reconstruction. *Arthroscopy* 2008 May;24:514-519.
20. Bauer T, Abadie O, Hardy P. Arthroscopic treatment of glenoid fractures. *Arthroscopy* 2006;22:569.e561-569.e566.
21. Hovelius L, Sandstrom B, Sundgren K, Saebo M. One hundred eighteen Bristow-Latarjet repairs for recurrent anterior dislocation of the shoulder prospectively followed for fifteen years: Study I—Clinical results. *J Shoulder Elbow Surg* 2004;13:509-516.
22. Levine WN, Arroyo JS, Pollock RG, Flatow EL, Bigliani LU. Open revision stabilization surgery for recurrent anterior glenohumeral instability. *Am J Sports Med* 2000;28:156-160.
23. Warner JJ, Gill TJ, O'Hollerhan JD, Pathare N, Millett PJ. Anatomical glenoid reconstruction for recurrent anterior glenohumeral instability with glenoid deficiency using an autogenous tricortical iliac crest bone graft. *Am J Sports Med* 2006;34:205-212.
24. DiPaola MJ, Jazrawi LM, Rokito AS, et al. Management of humeral and glenoid bone loss—Associated with glenohumeral instability. *Bull NYU Hosp Jt Dis* 2010;68:245-250.
25. Hutchinson JW, Neumann L, Wallace WA. Bone buttress operation for recurrent anterior shoulder dislocation in epilepsy. *J Bone Joint Surg Br* 1995;77:928-932.
26. Millett PJ, Schoenahl JY, Register B, Gaskill TR, van Deurzen DF, Martetschlager F. Reconstruction of posterior glenoid deficiency using distal tibial osteoarticular allograft. *Knee Surg Sports Traumatol Arthrosc* 2013;21:445-449.
27. Petrera M, Veillette CJ, Taylor DW, Park SS, Theodoropoulos JS. Use of fresh osteochondral glenoid allograft to treat posteroinferior bone loss in chronic posterior shoulder instability. *Am J Orthop (Belle Mead NJ)* 2013;42:78-82.
28. Tjoumakaris FP, Sekiya JK. Combined glenoid and humeral head allograft reconstruction for recurrent anterior glenohumeral instability. *Orthopedics* 2008;31:497.
29. Weng PW, Shen HC, Lee HH, Wu SS, Lee CH. Open reconstruction of large bony glenoid erosion with allogeneic bone graft for recurrent anterior shoulder dislocation. *Am J Sports Med* 2009;37:1792-1797.
30. Young DC, Rockwood CA Jr. Complications of a failed Bristow procedure and their management. *J Bone Joint Surg Am* 1991;73:969-981.
31. Beaver RJ, Mahomed M, Backstein D, Davis A, Zukor DJ, Gross AE. Fresh osteochondral allografts for post-traumatic defects in the knee. A survivorship analysis. *J Bone Joint Surg Br* 1992;74:105-110.
32. Gerber C, Lambert SM. Allograft reconstruction of segmental defects of the humeral head for the treatment of chronic locked posterior dislocation of the shoulder. *J Bone Joint Surg Am* 1996;78:376-382.
33. Constant CR, Murley AH. A clinical method of functional assessment of the shoulder. *Clin Orthop Relat Res* 1987;214:160-164.
34. Richards RR, An KN, Bigliani LU, et al. A standardized method for the assessment of shoulder function. *J Shoulder Elbow Surg* 1994;3:347-352.
35. Amstutz HC, Sew Hoy AL, Clarke IC. UCLA anatomic total shoulder arthroplasty. *Clin Orthop Relat Res* 1981;155:7-20.
36. Hudak PL, Amadio PC, Bombardier C. Development of an upper extremity outcome measure: the DASH (disabilities of the arm, shoulder and hand) [corrected]. The Upper Extremity Collaborative Group (UECG). *Am J Ind Med* 1996;29:602-608.
37. Gupta AK, Chalmers PN, Klosterman E, et al. Arthroscopic distal tibial allograft augmentation for posterior shoulder instability with glenoid bone loss. *Arthrosc Tech* 2013;2:e405-e411.
38. Zhao J, Huangfu X, Yang X, Xie G, Xu C. Arthroscopic glenoid bone grafting with nonrigid fixation for anterior shoulder instability: 52 patients with 2- to 5-year follow-up. *Am J Sports Med* 2014;42:831-839.
39. Bugbee WD, Richard Convery F. Osteochondral allograft transplantation. *Clin Sports Med* 1999;18:67-75.
40. Buck BE, Malinin TI, Brown MD. Bone transplantation and human immunodeficiency virus. An estimate of risk of acquired immunodeficiency syndrome (AIDS). *Clin Orthop Relat Res* 1989;240:129-136.
41. Rodrigo JJ, Thompson E, Travis C. Deep-freezing versus 4 degrees preservation of avascular osteocartilaginous shell allografts in rats. *Clin Orthop Relat Res* 1987;218:268-275.
42. Oakeshott RD, Farine I, Pritzker KP, Langer F, Gross AE. A clinical and histologic analysis of failed fresh osteochondral allografts. *Clin Orthop Relat Res* 1988;233:283-294.
43. Boselli KJ, Ahmad CS, Levine WN. Treatment of glenohumeral arthrosis. *Am J Sports Med* 2010;38:2558-2572.
44. Williams SK, Amiel D, Ball ST, et al. Prolonged storage effects on the articular cartilage of fresh human osteochondral allografts. *J Bone Joint Surg Am* 2003;85-a:2111-2120.